



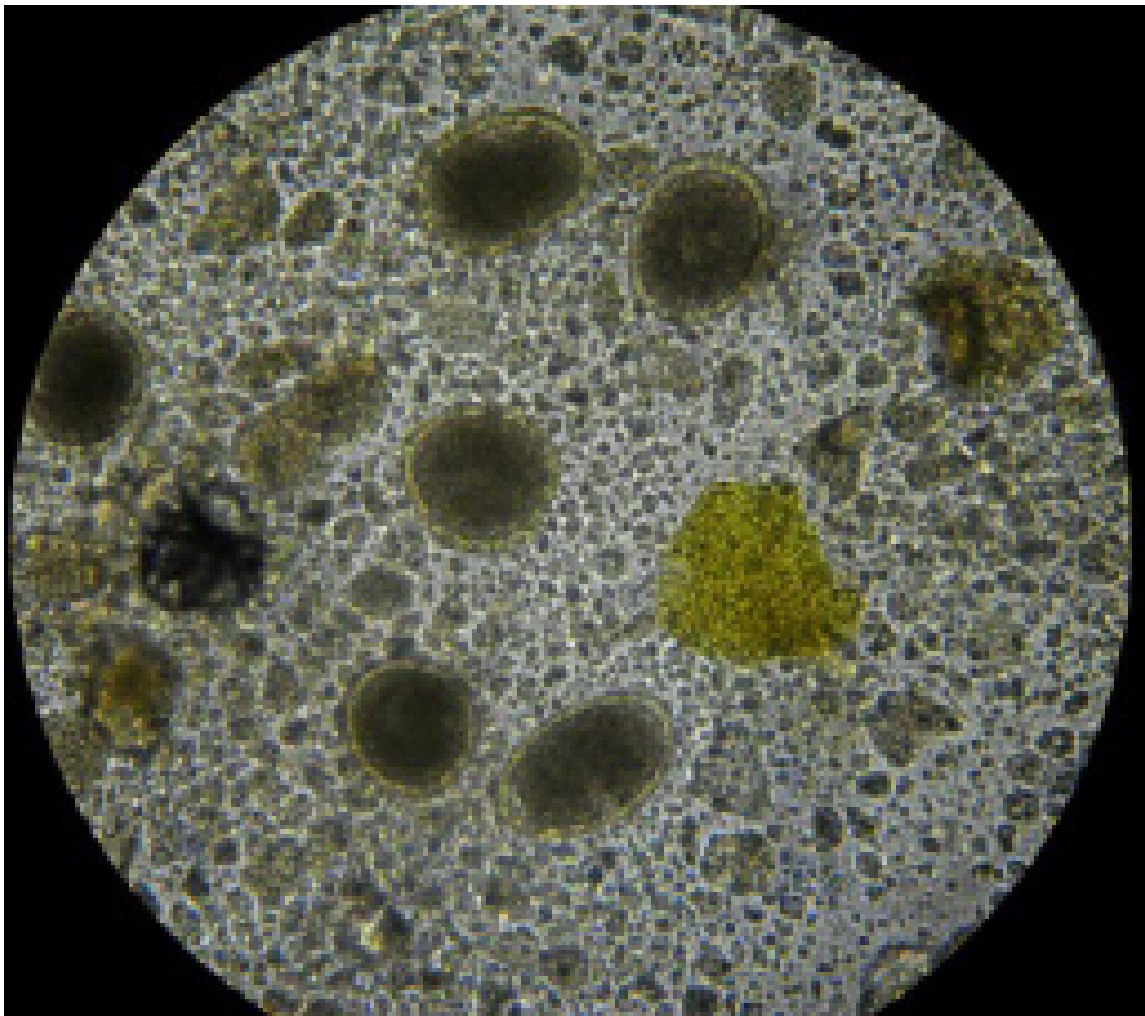
Supplementary Material

Gastrointestinal Helminth in Large Felines from a Zoo in Malaysia

Maria Syafiqah Ghazali¹, Azlan Che' Amat² and Nor Azlina Abdul Aziz^{1*}

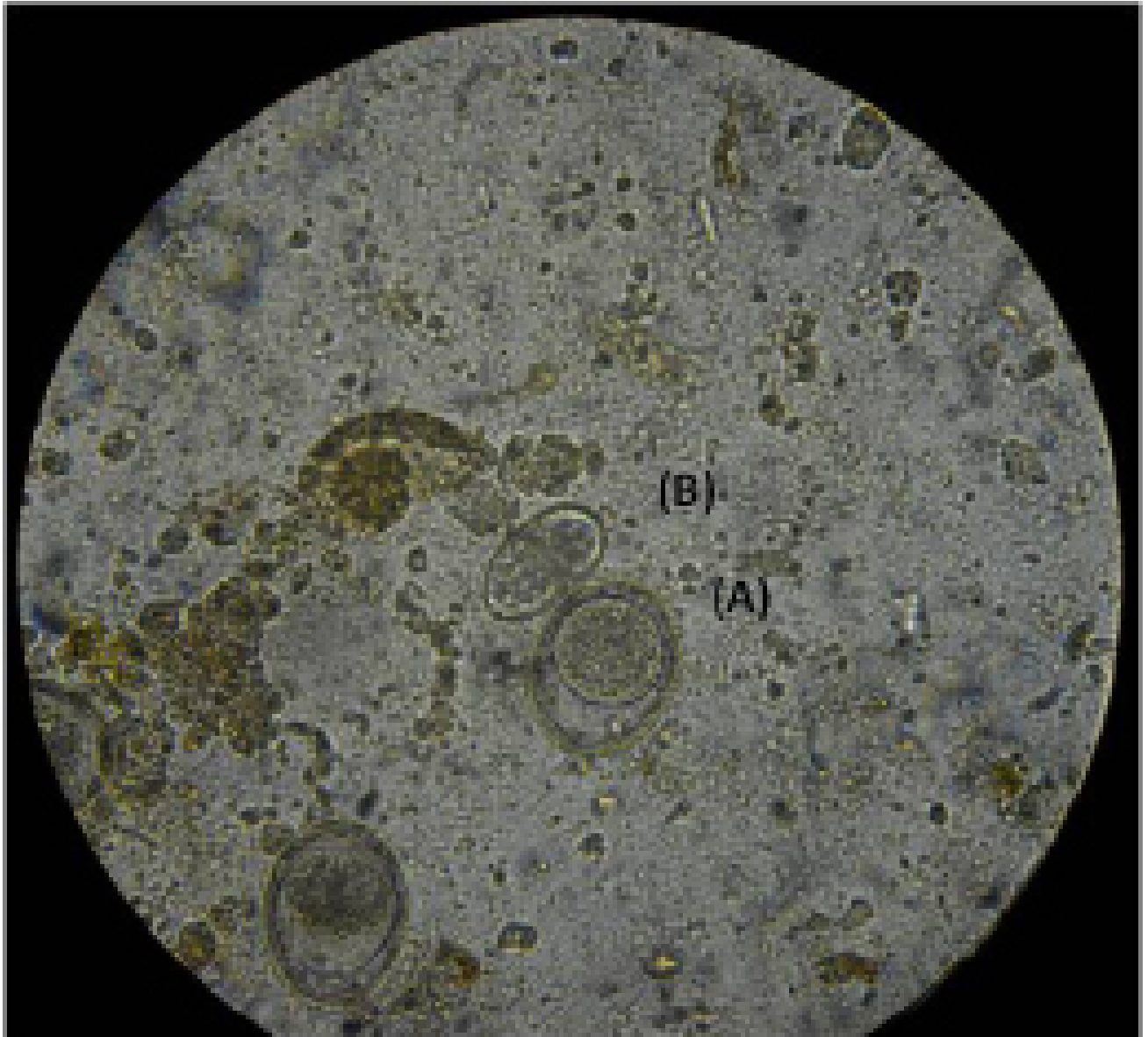
¹Department of Veterinary Pathology and Microbiology, Faculty of Veterinary Medicine, Universiti Putra Malaysia, 43400 UPM Serdang, Selangor, Malaysia

²Department of Veterinary Clinical Studies, Faculty of Veterinary Medicine, Universiti Putra Malaysia, 43400 UPM Serdang, Selangor, Malaysia.



Supplementary Fig. 1. Eggs of *Toxocara cati* in a puma.

* Corresponding author: azlinaaziz@upm.edu.my
0030-9923/2021/0002-0781 \$ 9.00/0
Copyright 2021 Zoological Society of Pakistan



Supplementary Fig. 2. Eggs of *Toxascaris leonina* (A) and *Ancylostoma* spp. (B) in an African lion.