



Expression of Aquaporin-1 and Endothelin-1 in Children with Congenital Hydronephrosis

Jinjian Ma¹, Zhaokang Wang² and Hong Liu^{3*}

¹Faculty of Medicine and Health Sciences, University of Putra Malaysia, Malaysia, Selangor Darul Ehsan, Malaysia.

²Ruikang Hospital Affiliated to Guangxi University of Traditional Chinese Medicine, Nanning, Guangxi530000, China.

³Clinical College of Hubei College of Traditional Chinese Medicine, Jingzhou, Hubei434020, China.

Jinjian Ma and Zhaokang Wang contributed equally to this work.

ABSTRACT

The objective of this study was to analyze the expression of aquaporin-1 (AQP-1) and endothelin-1 (ET-1) in children with congenital hydronephrosis. A study group consisted of 52 children who were admitted to our hospital from August 2021 to August 2022 and diagnosed with congenital pyelonephric junction stenosis (UPJO) leading to hydronephrosis through imaging examination. At the same time, 20 hospitalized children without hydronephrosis were enrolled as the control group. Record two sets of urine β Compare the protein expression and mRNA expression of AQP-1 and ET-1 in 2-MG, serum creatinine (Scr), and serum Ccr, analyze the expression of AQP-1 and ET-1 mRNA at different levels, and analyze the correlation between AQP-1 and ET-1. Compared with the control group, the expression of AQP-1 protein in the study group was lower, but the expression of ET-1 protein in the study group was higher than that in the control group; the expression of AQP-1 mRNA in the control group was higher than that in the study group, and the expression of ET-1 mRNA in the control group was significantly lower than that in the study group. In children with congenital hydronephrosis, the expression of AQP-1 protein and AQP-1 mRNA is low, while the expression of ET-1 protein and ET-1 mRNA is high, showing a negative correlation ($r=0.365$, $P=0.002$). It was concluded that AQP-1 and ET-1 proteins are involved in the progression of congenital hydronephrosis and may be potential biomarkers for diagnosing the condition of congenital hydronephrosis.

Article Information

Received 30 July 2023

Revised 28 October 2023

Accepted 13 November, 2023

Available online 08 January 2024 (early access)

Authors' Contribution

JM and ZW conducted the experiments in this study. HL contributed to the design and interpretation of the current study and wrote the article. All authors read, revised, and approved the final manuscript.

Key words

Congenital hydronephrosis, Aquaporin-1, Clinical significance, Endothelin-1, Children

INTRODUCTION

Hydronephrosis is relatively common in intrauterine ultrasound examination (Merguerian *et al.*, 2010). According to the available statistics, about half to two percent of intrauterine ultrasounds show an anomaly in the fetus, the most common of which is hydronephrosis (Mohammadjafari *et al.*, 2009). Dealing with fetal hydronephrosis varies according to the severity, whether it is unilateral or bilateral, and the gender of the baby; but in any case, it includes radiographic examinations such as

ultrasound, voiding cystourethrogram (VCUG) and functional kidney scans in the first months of life (Yamacake and Nguyen, 2013; Aubin *et al.*, 2013). The result of these investigations is the accurate identification of the underlying problem and appropriate treatment. This treatment may be surgical or medicinal, and many times, the patient does not need any special therapeutic intervention (Romao *et al.*, 2012; Alconcher and Tombesi, 2012; Yiee *et al.*, 2011; Valent-Moric *et al.*, 2011).

The most common causes of unilateral hydronephrosis in the fetal and neonatal period are: ureteropelvic junction obstruction (UPJO), vesicoureteral reflux (VUR) and ureterovesical junction obstruction (UVJO). Ureteral obstruction has been reported to trigger several pathophysiological changes (Hu *et al.*, 2023). Specifically, in case of a blockage in one or both of the ureters that carry urine from the kidneys to the bladder, the renal pelvis, calyces, collecting ducts and renal tubules are dilated, and then edema occurs in renal interstitium, which is consequently infiltrated by focal inflammatory cells, exposed to fibrosis, and finally prone to renal atrophy

* Corresponding author: liuhong230412@163.com
0030-9923/2023/0001-0001 \$ 9.00/0



Copyright 2023 by the authors. Licensee Zoological Society of Pakistan.

This article is an open access article distributed under the terms and conditions of the Creative Commons Attribution (CC BY) license (<https://creativecommons.org/licenses/by/4.0/>).

(Gosemann *et al.*, 2020). Therefore, the detection and analysis of congenital hydronephrosis, the main cause of end-stage renal disease in children, is an important guide for its treatment (Xie *et al.*, 2020; Jing and Zou, 2018). In animal experiments, AQP-1 and ET-1 were found to be significantly involved in renal dysfunction. In this study, an attempt has been made to examine the expression of AQP-1 and ET-1 proteins in eligible children with congenital hydronephrosis over a one-year period.

MATERIALS AND METHODS

Objects

All the eligible children were admitted to the Pediatric Surgery Department or Urology Department of our hospital from August 2021 to August 2022, and were diagnosed with hydronephrosis caused by congenital UPJO by color Doppler ultrasound, CT urography (CTU), intravenous pyelography (IVP), magnetic resonance urography (MRU) or CT examination. In order to avoid interference from other factors, some subjects were excluded by the following criteria: (1) bilateral hydronephrosis; (2) urinary tract infection; (3) hydronephrosis caused by other reasons, such as ureterovesical junction obstruction; (4) fever or other diseases; or 5) $\text{Scr} \geq 177.0$ mmol/L. A total of 52 children with unilateral hydronephrosis were enrolled, including 29 males and 23 females, with an average age of 5.52 ± 2.45 years. Besides, 20 hospitalized children without hydronephrosis were recruited as the control group, including 12 males and 8 females, with an average age of 5.46 ± 2.25 years. All of these children had congenital myotonic neck but were free of hydronephrosis, fever, urinary tract infection, and blood $\text{Scr} \geq 177.0$ mmol/L by urologic ultrasound.

Disease classification

Rickwood index (Jee *et al.*, 1993) was used to divide the children into 12 mild, 28 moderate and 12 severe cases, respectively. Children with mild to moderate hydronephrosis were followed up regularly in the outpatient department. The severe cases were treated by operation. During the operation, UPJO, dilated hydronephrosis of the renal pelvis and calyces, and thinned renal cortex occurred. After the operation, UPJO was pathologically confirmed, the diameter of UPJ ranged from 1.0 to 2.5 mm, and chronic inflammatory changes were found in the mucosa.

Index detection

(1) First, 10 ml fasting venous blood was extracted from all subjects in the morning and centrifuged for examination. Fasting morning urine was also collected and preserved for examination. Urine β 2-MG was detected by

radioimmunoassay, serum creatinine (Scr) was tested by sarcosine oxidase, and (Ccr) expression was represented by serum Scr (P), urine Scr (U), urine volume (V) and body surface area (A) as follows: $\text{Ccr} = \frac{U \times V}{P \times 1.73/A}$ (ml·min).

(2) Western blot was performed to identify AQP-1 and ET-1 expressions. To be specific, 50 μ g protein was extracted, boiled for 5 min to denature it, and subjected to SDS-PAGE gel electrophoresis. The gel was then cut open according to the size of the protein molecules and transferred to a PVDF membrane. The protein to be tested and the internal reference protein were blocked in room with Western blocking solution for 90 min, added to the antibody to be tested at a ratio of 1:1000 and the internal reference antibody at a ratio of 1:2000, incubated overnight, and washed 5 times with Western washing solution, once every 10 min. Diluted goat anti-rabbit IgG was added at a ratio of 1:5000, incubated for 60 min in a horizontal shaker at room temperature, and washed 5 times with Western washing solution, once every 10 min. After ECL coloration and exposure, the mixture was subjected to BIO-RAD imaging, and ImageJ was used to detect the gray value of the band, and the gray value of the internal reference band and the protein rational were taken as AQP-1 and ET-1 results for statistical analysis, respectively.

(3) RT-PCR was performed to detect the expression of AQP-1 mRNA and ET-1 mRNA. Total RNA was extracted from the cells to determine RNA purity and content, and then reversely transcribed into cDNA. Primers were designed using Primer 5. 0, and Numb expression was calculated by $2^{-\Delta\Delta\text{Ct}}$ method with U6 as the internal reference. The assays were performed according to the primer sequences in Table I.

Table I. List of primer sequences.

Genes	Primer sequences
<i>AQP-1</i>	Upstream 5'-CTGACCCGCTCGGACTTACT-3'
	Downstream 5'-CCACGTCTTCTGGACCCATG-3'
<i>ET-1</i>	Upstream 5'-CCCAGCACATCCTGGAGACC-3'
	Downstream 5'-CTCGGGAGTGTTGACCCAGAT-3'
<i>β-actin</i>	Upstream 5'-TCAGCATCGACCCGTACCTG-3'
	Downstream 5'-GACTTTGGCCACCAGCATCG-3'

For abbreviations, see Table II.

Statistical analysis

SPSS 26.0 provided data analysis, and Kolmogorov-Smirnov provided a normal distribution test. Measurement data in normal distribution were described by mean \pm standard deviation ($\bar{x} \pm s$), and then compared in multiple groups through *F* test while compared between two groups by an independent sample *t* test. Those not in

normal distribution were expressed by M(Qn) after natural logarithm transformation, and examined by a non-parametric test. Meanwhile, enumeration data were expressed as rate (%) and tested by χ^2 test. The correlation between miR-152, SHGB and SRC-2 was analyzed by Pearson, and $P < 0.05$ was considered statistically significant.

RESULTS

As shown in Table II, the expressions of urinary β_2 -MG, serum Scr and serum Ccr were compared between the two groups. Compared with the control group, the study group had higher expressions of urinary β_2 -MG, serum Scr and serum Ccr ($P < 0.05$).

Table II. Comparison of the variables expression between both groups ($\bar{x} \pm s$).

	Control group (n=20)	Study group t (n=52)	t	P
Urine β_2 -MG (mg/L)	0.17 \pm 0.03	0.32 \pm 0.06	10.65	0.001
Scr (mol/L)	28.16 \pm 3.84	40.42 \pm 5.13	9.679	0.001
Serum Ccr (ml/min)	76.69 \pm 8.25	85.37 \pm 9.72	3.531	0.001
AQP-1mRNA	1.76 \pm 0.24	0.85 \pm 0.13	20.69	0.001
ET-1mRNA	0.64 \pm 1.05	1.47 \pm 0.02	5.764	0.001

AQP, aquaporin-1; ET-1, endothelin-1; Serum Ccr, serum creatinine clearance Scr, serum creatinine.

The expressions of AQP-1 and ET-1 were compared between the two groups. Compared with the control group, the study group showed lower expression of AQP-1 protein but higher level of ET-1 protein, as shown in Figure 1.

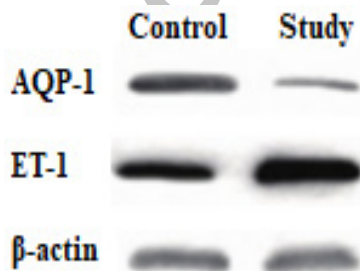


Fig. 1. Expression map of AQP-1 and ET-1. For abbreviations, see Table II.

AQP-1 mRNA and ET-1 mRNA levels were compared between the two groups, and it was found that the AQP-1 mRNA expression was higher, but the ET-1 mRNA expression was significantly lower in the control group

($P < 0.05$) (Table II).

As shown in Table III, the expressions of AQP-1 mRNA and ET-1 mRNA were compared among children with different grades of congenital hydronephrosis. It was found that mild children had higher AQP-1 mRNA and lower ET-1 mRNA expressions than moderate and severe cases ($P < 0.05$); The moderate group presented higher AQP-1 mRNA expression than the severe group, while the ET-1 mRNA level was lower in moderate group than that in the mild group ($P < 0.05$).

Table III. Expression of AQP-1mRNA and ET-1mRNA in children with different degrees of congenital hydronephrosis.

Group	Cases	AQP-1mRNA	ET-1mRNA
Mild	12	1.17 \pm 0.23	1.06 \pm 0.11
Moderate	28	0.88 \pm 0.11	1.56 \pm 0.18
Severe	12	0.49 \pm 0.05	1.89 \pm 0.21

For abbreviations, see Table II.

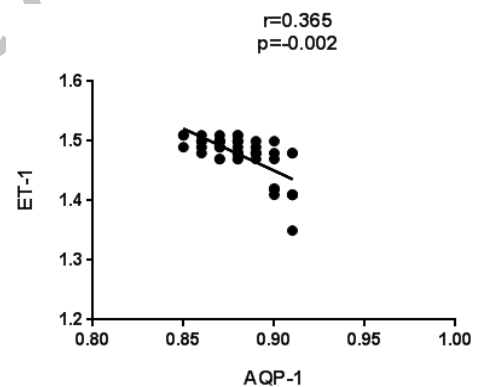


Fig. 2. Correlation analysis between AQP-1 and ET-1. For abbreviations, see Table II.

Correlation analysis showed that there was a negative correlation between AQP-1 and ET-1 ($R = 0.365$, $P = 0.002$) (Fig. 2).

DISCUSSION

Genetic factors and congenital renal sinus abnormalities are closely related to the occurrence of congenital hydronephrosis (Wang *et al.*, 2018). As congenital hydronephrosis progresses, children have been reported with a poor prognosis. For example, the poor prognosis characterized by hydronephrosis, renal tissue edema, loss of renal function, decreased metabolic function of the kidney, and renal artery stenosis often occurs after

ureteral obstruction (Pan and Sachdeva, 2019). Congenital hydronephrosis is a congenital malformation as a result of the interplay of complex and multifaceted factors. In recent years, scholars at home and abroad have made animal models of complete or partial ureteral obstruction to study congenital hydronephrosis at the molecular level, and found that the expression changes of cytokines are closely correlated with the occurrence and development of congenital hydronephrosis (Sevostjanovs *et al.*, 2020; Shields *et al.*, 2020).

Aquaporins widely exist in the specific channels of water-borne processes in prokaryotic and eukaryotic cell membranes. Studies on the structure and function of aquaporins suggest that they are involved in the physiology and pathology of fluid transport in various organs and tissues (Shi *et al.*, 2022; Wang *et al.*, 2022). Not only that, but aquaporins are widely distributed in various systems of the body, and most of them are highly expressed in epithelial and endothelial cells, which are closely related to the secretion and absorption of body fluid. Since one of the aquaporin subtypes is the most abundant molecule in the kidney, most scholars believe that aquaporins play an important role in the process of kidney damages (Jiang *et al.*, 2021).

As one of the important aquaporin subtypes, AQP-1 is involved in water-borne processes during the transport of non-consuming adenosine triphosphate of aquaporins (Wang *et al.*, 2022). Under pathological conditions, AQP-1 level declines, inhibits the absorption of the renal pelvis and oviduct, and then aggravates renal obstruction and renal damage (Zhang *et al.*, 2021). Reportedly, the down-regulation of AQP-1 expression may lead to a decrease in osmotic transport capacity in congenital hydronephrosis. As a consequence, fluid may accumulate in the renal pelvis and oviduct obstruction and aggravate the condition (Xue *et al.*, 2020). With the decrease of AQP-1 expression, channel protein transporters in renal tubular epithelium will be insufficient so that significant changes will be made in the local osmotic pressure of glomerulus and nephron, affecting glomerular filtration function (Sun *et al.*, 2019). Congenital hydronephrosis has been confirmed to reduce AQP-1 expression by more than 25% on average, and the more severe the tubal obstruction is, the lower the expression is (Zhang *et al.*, 2019). In this study, the study group presented lower AQP-1 protein and AQP-1 mRNA expressions than the control group, and AQP-1 level tended to decrease with the severity of congenital hydronephrosis, consistent with the above findings. The relationship analysis between AQP-1 and ET-1 showed a negative correlation, indicating that the low expression of AQP-1 is involved in the progression of congenital hydronephrosis and is expected to become a marker for

its diagnosis.

ET-1, an endogenous vasoconstrictive peptide with long action intensity and action time, gets involved in the process of renal ischemia and hypoxia. It shows an increasing trend in normal tissue cells, and consequently the tissue cells that do not express or express low ET-1 gene will secrete ET-1 in large quantities, which may cause or participate in the changes of renal hemodynamics and further aggravate renal ischemia (Zhang *et al.*, 2022). In case of an ischemia-reperfusion injury, tissue ischemia and hypoxia are reported to trigger vascular endothelial cell damage, and then increase the release of ET-1, aggravating renal injury (Wang *et al.*, 2019; Anggorowati *et al.*, 2020). In this study, ET-1 protein and ET-1 mRNA were highly expressed in children with congenital hydronephrosis, indicating that the release of ET-1 progressed the condition and the renal injury.

CONCLUSION

The expression of AQP-1 protein and AQP-1 mRNA were lowly expressed in children with congenital hydronephrosis, while ET-1 protein and ET-1 mRNA were highly expressed. They were negatively correlated, but both were involved in the progress of congenital hydronephrosis and were expected to become markers for its diagnosis.

ACKNOWLEDGEMENT

Authors would like to express their gratitude to all those who helped during the writing of this thesis and acknowledge the help of department director, Ms. Su, who has offered me valuable suggestions in the academic studies.

Funding

The study received no external funding.

IRB approval

This study was approved by the Clinical College of Hubei College of Traditional Chinese Medicine, Jingzhou, Hubei 434020, China.

Ethical approval

The study was carried out in compliance with guidelines issued by Ethical Review Board Committee of Clinical College of Hubei College of Traditional Chinese Medicine, China. The official letter would be available on fair request to corresponding author.

Statement of conflict of interest

The authors have declared no conflict of interest.

REFERENCES

- Alconcher, L.F. and Tombesi, M.M., 2012. Natural history of bilateral mild isolated antenatal hydronephrosis conservatively managed. *Pediatr. Nephrol.*, **27**: 1119-1123. <https://doi.org/10.1007/s00467-012-2113-0>
- Anggorowati, N., Nugrahaningsih, D.A.A. and Emoto, N., 2020. Endothelin converting enzyme-1 (ECE-1) deletion in association with Endothelin-1 downregulation ameliorates kidney fibrosis in mice. *Life Sci.*, **258**: 118223. <https://doi.org/10.1016/j.lfs.2020.118223>
- Aubin, M.S., Willihnganz-Lawson, K., Varda, B.K., Fine, M., Adejoro, O., Prosen, T., Lewis, J.M. and Shukla, A.R., 2013. Society for fetal urology recommendations for postnatal evaluation of prenatal hydronephrosis-will fewer voiding cystourethrograms lead to more urinary tract infections? *J. Urol.*, **190**: 1456-1461. <https://doi.org/10.1016/j.juro.2013.03.038>
- Gosemann, J., Alvarez, L.A. and Puri, P., 2020. Altered anoctamin-1 and tyrosine phosphorylation in congenital ureteropelvic junction obstruction. *J. Pediatr. Surg.*, **55**: 1621-1625. <https://doi.org/10.1016/j.jpedsurg.2020.02.001>
- Hu, L., Yang, F. and Xie, Z., 2023. Diagnostic value of urography combined with color doppler in children with congenital hydronephrosis. *Adv. Mod. Biomed.*, **23**: 158-162.
- Jee, L.D., Rickwood, A.M., Williams, M.P. and Anderson, P.A., 1993. Experience with duplex system anomalies detected by prenatal ultrasonography. *J. Urol.*, **149**: 808-810. [https://doi.org/10.1016/S0022-5347\(17\)36213-4](https://doi.org/10.1016/S0022-5347(17)36213-4)
- Jiang, R., Zhang, L. and Yan, J., 2021. Expressions of transforming growth factor- β 1, aquaporin and osteopontin in renal injury induced by fluorosis in rats. *Chin. J. Endemiol.*, **40**: 535-539.
- Jing, P. and Zou, J., 2018. Clinical value of serum CysC, β 2-MG and α 1-MG in children with congenital hydronephrosis. *Contemp. Med.*, **24**: 111-113.
- Merguerian, P.A., Herz, D., McQuiston, L. and Van Bibber, M., 2010. Variation among pediatric urologists and across 2 continents in antibiotic prophylaxis and evaluation for prenatally detected hydronephrosis: A survey of American and European pediatric urologists. *J. Urol.*, **184**: 1710-1715. <https://doi.org/10.1016/j.juro.2010.03.115>
- Mohammadjafari, H., Alam, A., Kosarian, M., Mousavi, S.A. and Kosarian, S.H., 2009. Vesicoureteral reflux in neonates with hydronephrosis, role of imaging tools. *Iran J. Pediatr.*, **19**: 347-353.
- Pan, P. and Sachdeva, N., 2019. Immunohistochemistry and morphometric analysis of pelviureteric junction complexes in children with hydronephrosis. *Indian J. Pathol. Microbiol.*, **62**: 49-53. https://doi.org/10.4103/IJPM.IJPM_535_17
- Sevostjanovs, E., Dambrova, M. and Liepinsh, E., 2020. Rats with congenital hydronephrosis show increased susceptibility to renal ischemia-reperfusion injury. *Physiol. Rep.*, **8**: e14638. <https://doi.org/10.14814/phy2.14638>
- Romao, R.L., Farhat, W.A., Pippi Salle, J.L., Braga, L.H., Figueroa, V., Bägli, D.J., Koyle, M.A. and Lorenzo, A.J., 2012. Early postoperative ultrasound after open pyeloplasty in children with prenatal hydronephrosis helps identify low risk of recurrent obstruction. *J. Urol.*, **188**: 2347-2353. <https://doi.org/10.1016/j.juro.2012.08.036>
- Shi, M., Xu, Y. and Wang, Z., 2022. Effect and mechanism of Elabela on improving diabetic nephropathy by regulating aquaporin 2. *Chin. J. Endocrinol. Metab.*, **38**: 651-657.
- Shields, L.B.E., Peppas, D.S. and Rosenberg, E., 2020. Bilateral aniridia and congenital ureteral valve: Role of genetic testing. *Mol. Genet. Genomic Med.*, **8**: e1183. <https://doi.org/10.1002/mgg3.1183>
- Sun, M., Tian, H. and Yu, Y., 2019. Berberine regulates the expression of aquaporin-1 via PI3K/Akt pathway and improves renal function in diabetic rats. *Chin. J. Anat.*, **42**: 561-564.
- Valent-Morić, B., Žigman, T., Čuk, M., Žaja-Franulović, O. and Malenica, M., 2011. Postnatal evaluation and outcome of infants with antenatal hydronephrosis. *Acta Clin. Croat.*, **50**: 451-455.
- Wang, L., Lv, Y. and Nie, Y., 2022. The relationship between aquaporin 1, transforming growth factor- β 1, vascular endothelial growth factor and peritoneal transport function in continuous ambulatory peritoneal dialysis patients. *Chin. J. Blood Purif.*, **21**: 25-28.
- Wang, M., Zhang, J. and Zhang, L., 2019. Indicative effect of serum ET-1 level on unplanned disembarkation and outcomes of continuous renal replacement therapy. *J. Prev. Med. Chin. PLA*, **37**: 50-52.
- Wang, W., Liu, J. and Kan, Y., 2018. Diuretic renal dynamic scintigraphy in grading of congenital hydronephrosis. *J. clin. exp. Med.*, **17**: 2411-2413.
- Wang, Y., Zhang, Y. and Wang, H., 2022. Role of urinary

- aquaporin 2 in evaluating proximal tubular injury. *Lab. Med.*, **42**: 415-418.
- Xie, X., Zheng, B. and Deng, J., 2020. A follow-up study of 300 patients with cNO papillary thyroid microcarcinoma. *Chin. J. Bas. Clin. Gen. Surg.*, **27**: 569-573.
- Xue, L., Su, G. and Jin, Y., 2020. Aquaporin 1 alleviates acute kidney injury via PI3K-mediated macrophage M2 polarization. *Inflamm. Res.*, **69**: 509-521. <https://doi.org/10.1007/s00011-020-01334-0>
- Yamaçake, K.G. and Nguyen, H.T., 2013. Current management of antenatal hydronephrosis. *Pediatr. Nephrol.*, **28**: 237-243. <https://doi.org/10.1007/s00467-012-2240-7>
- Yiee, J.H., Tasian, G.E. and Copp, H.L., 2011. Management trends in prenatally detected hydronephrosis: National survey of pediatrician practice patterns and antibiotic use. *Urology*, **78**: 895-901. <https://doi.org/10.1016/j.urology.2011.04.027>
- Zhang, C., Su, P. and Li, B., 2022. Screening for kidney stones in elderly patients with hyperuricemia or gout and its correlation with serum NALP3, sICAM-1 and ET-1. *Chin. J. Gerontol.*, **42**: 4415-4418.
- Zhang, L., Zhang, X. and Cheng, W., 2021. Regulation of miR-1306-5p targeting aquaporin 1 on diabetic cardiomyopathy. *J. Zhengzhou Univ. (Med. Sci.)*, **56**: 236-241.
- Zhang, X., Xie, G. and Zhou, C., 2019. Effect of tetramethylpyrazine on the expression of aquaporin-1 in human epithelial cells. *Chin. J. Integ. Trad. West. Nephrol.*, **20**: 801-804.

Online First Article