

Pulicaria odora Protects Domestic Male Pigeons (*Columba livia domestica*) Exposed to a Long Photoperiod from Cypermethrin-induced Seasonal Reproductive Impairment

Omar Berkani^{1*}, Souheila Slimani², Nora Sakhraoui³ and Cherif Abdennour¹

¹Laboratory of Animal Ecophysiology, Department of Biology, Faculty of Sciences, University of Badji Mokhtar, Annaba BP 12, 23000 Annaba, Algeria.

²Department of SNV, Faculty of Sciences, University of August 20, 1955 Skikda, Algeria.

³Laboratory of Research in Biodiversity Interaction, Ecosystem and Biotechnology (LRIBEB), University of 20 August 1955, Skikda, Algeria.

ABSTRACT

The present study was conducted to assess whether *Pulicaria odora* (PO) aqueous extract could serve as a protective agent against the toxic impacts of two doses of cypermethrin (CYP) on the seasonal reproduction of domestic males pigeons (*Columba livia domestica*) subjected to a long photoperiod (19L: 05D). Therefore, thirty pigeons were divided equally into six groups; group C used as a control, group PO used as a positive control that treated by PO (300 mg/k b.w/day), CYP1 and CYP2 groups were respectively treated by 10 and 20 mg/Kg b.w/day, in addition to CYP1+PO and CYP2+PO groups. All treatments were realized by gavage for 10 consecutive weeks starting in mid-February. Their testes volumes and moult plumage progression were measured every 15 days. Whereas, testicular weights, testicular histological examination, vas different semen analysis and plasma FT4 level were measured at week 10. Results showed that under long photoperiod, the sexual activity of the control group lasted for 06 weeks, characterized by a significant growth in the testicular volume, followed by spontaneous gonadal regression up to week 10. Azoospermia in control birds was noticed, with a significant increase in FT4 level and a fall of flying feathers in the 8th and 10th weeks, which assert the testicular regression. Compared to the control, CYP1 and CYP2 increased the testicular weights significantly during the last weeks by delaying the refractory phase until the end of the experimental period, while most of spermatozoa were malformed or dead. Various histopathological alterations including a decrease in interstitial space, an enlarged lumen, a remarkable atrophy of Leydig cells and malformed spermatozoa were observed in the gonads of birds exposed to CYP. The FT4 concentration decreased significantly and none of the CYP groups was molting. Treatment with PO aqueous extract seems counteracted the toxic effects of CYP, which was confirmed histopathologically by the noticeable amelioration in the testicular tissues. It was concluded that PO aqueous extract co-administration may be promising as a natural protective herb against CYP-induced reproductive toxicity in the male pigeons.

Article Information

Received 11 May 2022

Revised 25 June 2022

Accepted 01 August 2022

Available online 08 September 2022
(early access)

Authors' Contribution

OB designed and performed the experiments, collected the data and analysed it and wrote the article. SS supervised the work and corrected the manuscript. NS identified the plants. CA corrected the language of the article. All authors read and approved the final manuscript.

Key words

Pigeon, Cypermethrin, *Pulicaria odora*, Seasonal reproduction, Insecticide

INTRODUCTION

Synthetic pyrethroids have been reported to account for 30% of all pesticides used worldwide

* Corresponding author: omarberkani0423@gmail.com
0030-9923/2022/0001-0001 \$ 9.00/0



Copyright 2022 by the authors. Licensee Zoological Society of Pakistan.

This article is an open access article distributed under the terms and conditions of the Creative Commons Attribution (CC BY) license (<https://creativecommons.org/licenses/by/4.0/>).

(Iwanika et Borzechi, 2015). Cypermethrin [(R, S)-alpha-cyano-3-phenoxybenzyl (IRS)-cis, trans-3-(2, 2-dichlorovinyl)-2, 2-dimethyl cyclopropane carboxylate] is a member of pyrethroids insecticides family and is made of natural compounds that extracted from the chrysanthemum flower (Solati et al., 2010). Cypermethrin belongs to the type II class and is widely used in agricultural, domestic applications (Palanisamy et al., 2012), by humans for spot treatment to control insect pests in stores, warehouses, industrial buildings, houses, laboratories, transports (Suzan, 2012), and against ectoparasites in the veterinary field (He, 2000; Barlow et al., 2001).

Despite a wide margin of safety, recent literature has shown that Cypermethrin can induce adverse effects on

non-target organisms as farm animals (Latif *et al.*, 2012). Moreover, since it is widely used, CYP has been detected in different levels in the air, soil, and water (Palanisamy *et al.*, 2012). As a result, its persistence in the ecosystems is challenging in which many non-target organisms are at risk.

Various studies have reported that CYP can accumulate in mammals, kidneys, liver, heart, adrenals and body fats (Hall *et al.*, 1980; Manna *et al.*, 2004). Therefore, CYP is a highly hydrophobic substance that might have a functional interaction with integral proteins or/and phospholipids to cross cell membranes (Michelangeli *et al.*, 1990). Therefore, the toxicity of CYP to the organism is linked to various ways includes oxidative stress and reactive oxygen species (ROS) generation (Gupta *et al.*, 1999). Cypermethrin is metabolized in the liver through hydrolytic ester cleavage and oxidative pathways by the CYP-450 enzymes to generate ROS, which may cause oxidative stress in mammals (Flodström *et al.*, 1988; Klimek, 1990). The ROS directly react with biomolecules and cause tissue damage by affecting the liver, kidney, and erythrocytes, (Zegura *et al.*, 2004; Giray *et al.*, 2001; Kale *et al.*, 1999). Moreover, CYP is well-known as a Neurotoxicant inducer (Wolansky and Crofton, 2006) by its ability to induce ROS (Kale *et al.*, 1999; Giray, 2001) that may cause central nervous system deficits through extending the opening of sodium channels where the spontaneous repetitive nerve-firing lead to a hypo-polarization and a hyper-excitation (Eells and Dubocovich, 1988; Narahashi *et al.*, 1992; Kirby *et al.*, 1999). Additionally, CYP can induce neurotoxicity by modifying the concentration of gamma-aminobutyric acid (Manna *et al.*, 2005). It was confirmed that CYP could be counted as one of the most relevant insecticides, since it perhaps contributes to Parkinson's disease through the implication of the nigrostriatal dopaminergic neurodegeneration (Nasuti *et al.*, 2007).

Recent studies have shown that exposure to CYP may cause serious health risks, including reproductive function in humans and wildlife such as abnormal sperm, cell morphology, decrease in testicular testosterone production, reduction of sperm production, decrease in fecundity, and behavioral changes such as aggression (Kjeldsen *et al.*, 2013; Orlu, 2014; Sharma *et al.*, 2014). In male rats, CYP has adversely affected fertility and reproduction (Elbetieha, 2001), while in mice it increased dead and abnormal sperm (Bhunya and Pati, 1990). It was demonstrated that a decrease in testosterone concentration may lead to the detachment of germ cells from the epithelium of the seminiferous tubules. (Blanco-Rodriguez and Martinez-Garcia, 1998; Zitzmann, 2008). Moreover, the observed decrease in sperm production in cypermethrin-treated rats, was proportional to the fall in serum testosterone levels (Hu *et al.*, 2013). Another study was performed

on androgen receptors (AR). The androgenic receptor is a type of nuclear receptor that mediates the actions of androgens (Wang *et al.*, 2009). *In vitro* test, CYP can exert an anti-androgenic effect by interfering with androgen receptors in the testicular androgen receptors reporter gene (Xu *et al.*, 2006), which cause an adverse effect on male reproduction (Kelce and Wilson, 1997).

A benefic effect of plants dietary supplementation on the reduction of various environmental toxicants has been demonstrated (Nandi *et al.*, 1997). Plant products are known to exercise scavenging action on free radicals and antioxidant protective effects (Palanisamy *et al.*, 2012). *Pulicaria odora L.* is a *spontaneous herb* widely used by the Algerian population in the treatments of many ailments due to its exciting biological and medicinal properties as an antibacterial (Hanbali *et al.*, 2005), antioxidant (Touati *et al.*, 2014) and anti-inflammatory agent (Bellakhdar, 1997). The essential oil of *P. odora* is rich in thymol (47.83%), tymolisobutyrate (30%), methylpropanoic acid (4.46%) and carvacrol (2.78%) (Hanbali *et al.*, 2005). Carvacrol and thymol present antibacterial and antifungal activity against phytopathogenic fungi (Cowan, 1999), in addition to the antioxidant activity of phenolic (thymol and carvacrol) and non-phenolic (linalool) chemotypes (Stefanovits-Banyai *et al.*, 2003).

Due to the lack of studies concerning the beneficial activities of *P. odora* in birds, the present work investigates the possible protective role of this local herb against the toxicity of CYP by evaluating the reproductive cycle of domestic male pigeon *Columba livia domestica* subjected to a long photoperiod.

MATERIALS AND METHODS

Cypermethrin preparation

The insecticide used in this study was a commercial formulation (SHERPA 25 EC) containing the active ingredient Cypermethrin 250 g/l. The chemical name for Cypermethrine is (RS)- α -cyano-3-phenoxybenzyl (1RS,3RS;1RS,3SR)-3-(2,2-dichlorovinyl)-2,2-dimethyl cyclopropanecarboxylate (C₂₂H₁₉Cl₂N₃O₃), with a CAS registry number 52315-07-8 and homologation number R 06 44 267. This product is made by CMPA firm and distributed by Agro Consulting International, Algeria. CYP was prepared by dissolving in an appropriate amount of distilled water.

Herb collection

Pulicaria odora (PO) is a perennial, characterized by a tall of 20-90 cm and basal leaves with short, ovoid, pointed and green flowering petioles. The leaves of the

stem are alternate, elongated and semi-sheathing. The flowers are lingual, golden yellow in color, exceeding 8 mm in involucre. The fruits can be up to 1.8 mm long with 10-12 bristles, surrounded at the base by a small membranous corolla.

Samples of PO were collected during February from Seraidi at an altitude of 850 meters, Annaba region (36° 55' 00" N, 7° 40' 00" E). Samples were transported to the laboratory in polyethylene bags, where it was identified by Sakhraoui a botanist at the University of Skikda- Algeria. The aqueous extract of PO was extracted by drying 1.5kg of the aerial part under an ambient temperature for a week, and then it crushed to powder. After that, 2 g was infused in 20 ml of boiled distilled water for 30 min. The preparation was repeated daily during 10 weeks of the experimental period. The equivalent of 300 mg/kg bw of the infused powder was delivered to each pigeons daily by gavage.

Animals

Male pigeons (*Columba livia domestica*), with an average body weight of 250–300 g, were obtained from particular animal markets in Annaba, north Algeria. Birds were kept in metal cages measuring 100x100x100 cm, with five birds per cage and were placed inside a light-controlled room, which was acclimatized for 14 days before the experimentation under standard conditions where food and water were supplied *ad libitum*.

Experimental design

Pigeons were divided into 6 groups represented by the control, the positive control that received 300mg/kg bw of (PO) infused powder. The third and the fourth groups received 10mg/kg bw and 20mg/kg bw of CYP1 and CYP2, respectively. The fifth and the sixth groups received a combination of CYP1+PO and CYP2+PO, respectively. All groups were held under an artificial photoperiod of (19L: 5D) using a programmable digital timer socket brand (profile comfort). Pigeons were treated daily by gavage for 70 days, and then they were sacrificed by cervical decapitation without anesthesia in order to minimize the animals' stress.

Molt score

Molt scores were assessed as the mean of the number of the nine primary feathers lost on both wings every 15 days of the experiment, which are normally shed in regular sequence, at the time of reproductive regression.

Testicular measurement

The testicular volume is measured after dissection at intervals of 15 days, according to the technique specific to birds (Boulakoud and Goldsmith, 1994). After anesthesia,

the incision with viscous lidocaine and fixation of the pigeons on a dissection board, a 2 cm long incision was made under the last pair of ribs. Testicular volumes were measured in situ after the separation of the intercostal muscles according to the formula of (Dawson *et al.*, 1985) as follows:

$V = 4/3 \pi a^2 b$; where a is half the width and b is half the length (long axis).

Testicular weight was measured after 10 weeks of the experiment with a precision balance (KERN PRS 320-3, Balingen, Germany).

Semen measurement

Sperm markers (concentration, motility and normality) were determined using a computer-assisted sperm analysis (CASA) system (Sperm Class Analyzer, S.C.A. V30, Microptic, Barcelona, Spain). The semen obtained from the pigeon's vas deferents immediately after sacrifice were diluted (dilution 1:8) with physiological water 0.9% NaCl. 8 μ l of semen was dropped into a slide chamber (GoldCyto 20- μ m), and then observed under a Nikon Eclipse (Nikon E200-LED) microscope at the phase objective (x4).

Thyroxin evaluation

Plasma free thyroxin (FT4) was estimated by automated micro particle enzyme immunoassay (ERBA XL-600, ERBA Diagnostics Mannheim GmbH, Mannheim, Germany) using commercial kits.

Histology

After decapitation, tissues from the left and right testes were collected and immediately fixed in neutral buffered formalin (NBF) by the standard method. Briefly, NBF-fixed tissues were dehydrated with ascending graded alcohols, embedded in paraffin, and sectioned at 6 μ m in thickness using a sliding microtome (EuromaxR, Japan). The deparaffinized sections were stained with hematoxylin and eosin (HE) for histopathological examination (Hould, 1998).

Statistical analysis

Data was expressed as mean \pm SEM. Statistical analysis was performed using one-way analysis of variance (ANOVA), followed by Tukey's post hoc test, and all statistical analyses were performed using GraphPad Prism 5.0. Significant test at $P \leq 0.05$ levels was considered.

RESULTS

Changes in testicular volume

Changes in gonadal size are shown in Table I. The four groups that were kept at long photoperiod throughout

the experiment (19L: 05D) had maintained a fully reproductive cycle, characterized by a significant increase in the testicular volume up to the six weeks, followed by spontaneous gonadal regression, by week 10 of the experiment. Treated groups by CYP had not shown any testicular size increase along the experimental period. However, mean testes size was superior in the treated pigeons compared to control at the end of the experiment, in which testicular volumes were (710.6±104.5 mm³) and (553.30±165.8 mm³) in Cyp-treated pigeons at 10 mg and 20 mg/kg bw, respectively.

Testicular weight

Testicular mass (g) of pigeons indicated a full regression in the four groups (C, PO, CYP1+PO, CYP2+PO) with significant differences against the mean testicular weight of the two treated groups by Cypermethrin (Fig. 1).

Sperm markers

The spermogramme revealed azoospermia in groups (C, PO, CYP1+PO and CYP2+PO) after 10 weeks of the experiment (Table II). However, pigeons exposed to the doses of 10 mg/kg bw and 20 mg/kg bw have a significant

increase of dead spermatozoa and sperm abnormalities.

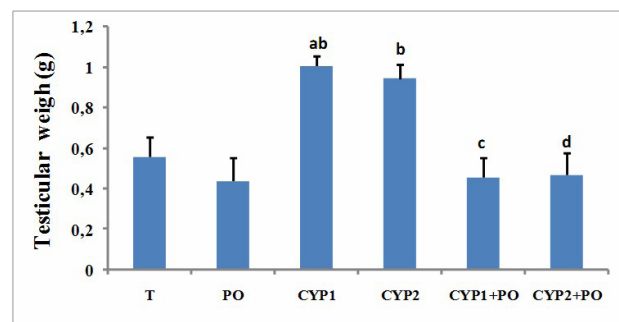


Fig. 1. Testicular mass (mean±SEM) of male pigeons treated with two different doses of cypermethrin (10 and 20 mg/kg bw) and the aqueous extract of *P. odora* (300mg/kg bw) for 10 weeks, and subjected to long photoperiod (19L: 05D) (n=5).

a, Significant difference between the control, CYP1 and CYP2; b, Significant difference between the positive control, CYP1 and CYP2; c, Significant difference between CYP1+PO, CYP1 and CYP2; d, Significant difference between CYP2+PO, CYP1, and CYP2, e, Significant difference between CYP1 and CYP2.

Table I. Variation of the mean testicular volume (mean ± SEM) of male pigeons *Columba livia domestica* subjected to a long photoperiod (19L: 05D) and exposed to Cypermethrin (CYP) and *P. odora* (PO) for 70 days (n=5).

Groups	Week 0	Week 2	Week 4	Week 6	Week 8	Week 10
C	180.66±38.28	254.35±49.44	306.6±79.52	557.89±19.71	298.74±48.8	185.2±57.96
CYP1	269.68±32.88	338.25±59.84	431.37±98.32	363.44±49.4 ^b	387.77±42.32 ^b	710.6±41.8 ^{ab}
CYP2	243.02±58.2	300.84±33.44	411.18±103.64	356.37±66.8 ^{ab}	431.08±39.72 ^{ab}	553.30±66.32 ^{ab}
PO	176.25±48.44	306.96±37.88	475.83±72.28	677.5±111.4	349.33±27.83	141±15.77
CYP1+PO	258.48±52.04	335.1±50.56	441.83±46.04	507.52±117.24	290.21±42.8 ^c	199.28±75.6 ^c
CYP2+PO	232.6±74.6	361.3±78.44	439.85±94.6	499.68±179.24	353.6±94.24 ^d	196.34±81.72 ^d

a, Significant difference between the control, CYP1, and CYP2; b, Significant difference between the positive control, CYP1 and CYP2; c, Significant difference between CYP1+PO, CYP1 and CYP2; d, Significant difference between CYP2+PO, and CYP1 and CYP2, e, Significant difference between CYP1 and CYP2.

Table II. Effects of Cypermethrin (CYP) and the aqueous extract of *P. odora* (PO) on sperm markers of male pigeons (*Columba livia domestica*) subjected to long photoperiod (19L: 05D) after 70 days (n=5).

	Sperm vitality %		Abnormalities %	
	Motile	Imotile	Normal	Abnormal
C	0	0	0	0
PO	0	0	0	0
CYP1	1.85±0.26 ^b	98.15±0.29 ^{abcd}	1.9±0.21 ^b	98.1±0.22 ^{abcd}
CYP2	1.3±0.70 ^b	98.7±0.70 ^{abcd}	1.24±0.70 ^b	98.76±0.70 ^{abcd}
CYP1+PO	0	0	0	0
CYP2+PO	0	0	0	0

For statistical details, see Table I.

Histopathological examination

The testicular histological assessments of pigeons after 10 weeks exposure to Cypermethrin and the aqueous extract of PO are seen in Figures 2 and 3. The control pigeon (Fig. 2A) and the positive control (Fig. 2B) exhibited regular seminiferous tubules with a thick basal blade and lack of successive stages of spermatogenesis, with an absence of spermatozoa in the lumen of somniferous tubules indicating thus, gonadal regression and a refractoriness period.

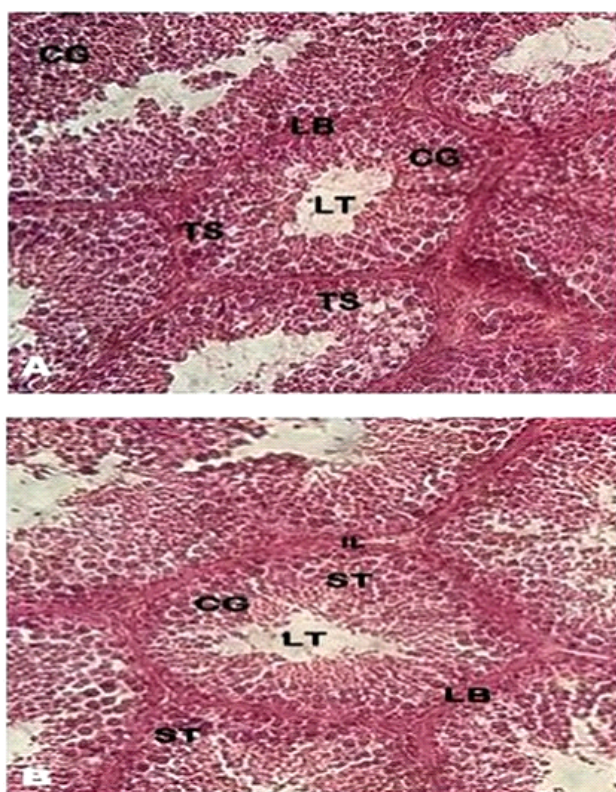


Fig. 2. Histological structure of the testicular control (A) and the positive control (B) of pigeons subjected to a long photoperiod (19L: 05D) (n=5) (X40).

ST, seminiferous tubule; Lb, basal lame; LT, lumen of seminiferous tubule; GL, germinal layer; IL, interstitial lumen.

Testicular histological examination from CYP1-treated pigeons (Fig. 3A) showed the irregular diameter of seminiferous tubules with a small and a fine elongated basal blade. Spermatozoa appear malformed in the lumen, with a slight decrease in Sertoli cells and atrophy of Leydig cells. Testicular histological observations of birds treated with 20 mg/kg bw (Fig. 3B) revealed a much severe testicular lesion reflected by elongated seminiferous tubules, with an enlarged lumen, empty germ layer and the existence of

round cells of the seminiferous epithelium and sloughing of germ cells into the lumen of the seminiferous tubules. However, spermatozoa seem immature and malformed. Furthermore, a severe decrease in interstitial space and rigorous atrophy of Leydig cells was observed.

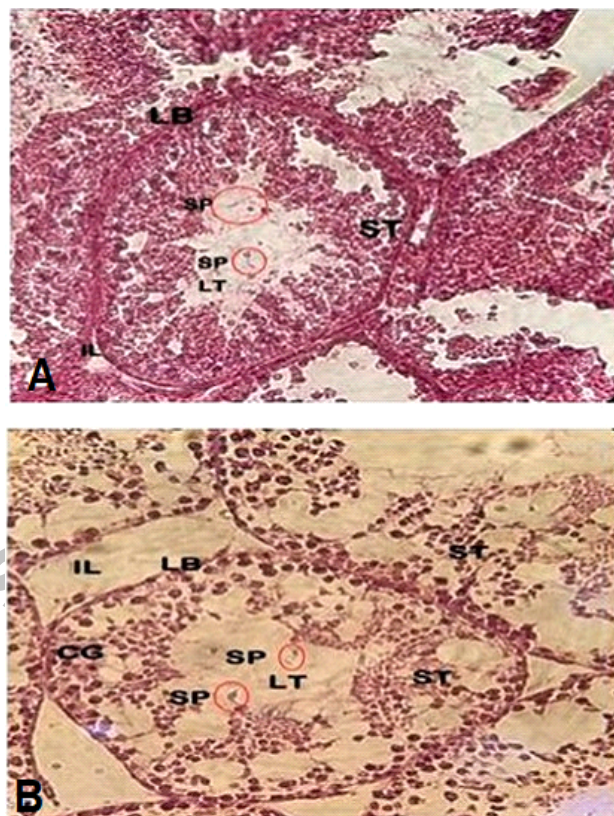


Fig. 3. Histological structure of the testicular pigeons treated with CYP1 (A) and CYP2 (B) subjected to a long photoperiod (19L: 5D) (n=5) (X40).

For abbreviation see Fig. 2.

The histological observation of the pigeons treated using the combination of cypermethrin, and the aqueous extract of PO lower dose CYP1+PO (Fig. 4A) and higher dose CYP2+PO (Fig. 4B) showed normal testicular architecture with a regular seminiferous tubule, with an absence of spermatozoa in the lumen of somniferous tubules.

Molting score

At the beginning of the experiment, none of the birds was molting (Table III). However, the control, the positive control, the CYP1+PO, and the CYP2+PO groups had begun to molt at the 8th week, and continued to increase until the end of the experiment at 10th week. On the other hand, the two groups treated with Cypermethrin alone

(CYP1 and CYP2) did not start the molt throughout the experiment in which pigeons still had complete numbers of primary flight feathers. It should be noted that the molt score of the control and the positive control was superior to those subjected to the combined treatment of CYP1+PO and CYP2+PO.

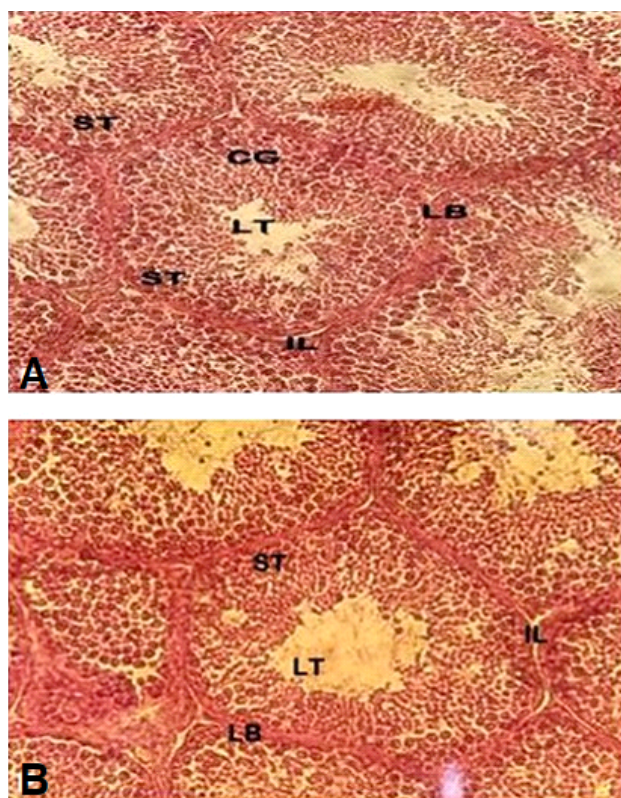


Fig. 4. Histological structure of the testicular pigeons treated with CYP1+PO (A) and CYP2+PO (B) subjected to a long photoperiod (19L: 5D) (n=5). (X40). For abbreviation see Fig. 2.

Table III. Variation (Mean±SEM) of the molt score in male pigeons supplied with PO and Cypermethrin (CYP) at two doses and placed under a long photoperiod (19L: 05D) (n=5).

Groups	Week8	Week10
C	0.3±0.25	0.9±0.31
PO	0.4±0.12	0.9±0.12
CYP1	0 ^{abcd}	0 ^{abcd}
CYP2	0 ^{abcd}	0 ^{abcd}
CYP1+PO	0.3±0.12	0.7±0.12
CYP2+PO	0.25±0.12	0.6±0.23

For statistical details, see Table I.

Plasma thyroxin

Plasma FT4 level showed significant variation between groups, where positive control birds maintained throughout the experiment on (19L: 05D) had the highest concentrations (16.31 ± 0.990 pmol/L), while treated groups by CYP1 and CYP2 had significant lower plasmatic thyroxin levels (Fig. 5). Birds treated by the combination of CYP1+PO and CYP2+PO had recorded a higher thyroxin concentrations at the 10th week, and were significantly different than those exposed to CYP1 and CYP2.

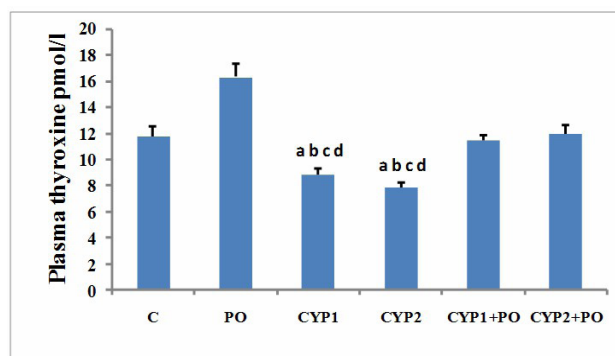


Fig. 5. Variation in plasma thyroxine concentration (means ± SEM) of male pigeons after 70 days exposure to Cypermethrin and *P. odora* (n=5). For statistical details, see Figure 1.

DISCUSSION

The findings from this Work demonstrate that under a long artificial photoperiod (19L: 5D), control and PO pigeons maintained a fully reproductive cycle characterized by full mature testes at the 6th week, followed by spontaneous gonadal regression. These findings are in accordant with Slimani *et al.* (2018). The physiological mechanism underlying the photo-stimulation is that an increase in photoperiod elevates the rate of gonadotrophin-releasing hormone (GnRH) secretion, which in turn acts on the anterior pituitary gland to secrete gonadotropins, and hence gonadal maturation such as luteinizing hormone (LH) and follicle stimulating hormone (FSH) to induce gonad growth and steroid hormone production (Wingfield and Farner, 1993). It is important to note that tests volumes in PO pigeons are superior as control tests. Several studies showed that medicinal plant can by their saponin stimulates the pituitary gland to produce more LH and makes testosterone (Wang *et al.*, 2001; Sharma *et al.*, 2020).

In this study, results have shown that at week ten a decreased testicular weight of control pigeon's was likely due to the refractoriness (Boulakoud and Goldsmith,

1991). The increase of testicular weights mainly stand on the mass of differentiated spermatogenic cells through spermatogenesis stages, but the reduction of their weights was proportionate with the elimination of germ cells (Chapin and Lamb, 1984). However, this study demonstrated that the remarkable increase of testicular weight was correlated with increasing cypermethrin concentrations, which may be owed to enlarged and elongated lumen and interstitial spaces of the seminiferous tubules. Cypermethrin induced testicular histological impairments in rats, including distorted seminiferous tubules with a reduction and deformation of spermatogonia and spermatocytes, accompanied with reduced sperm motility (Hu *et al.*, 2013). Cypermethrin has affected the germinal epithelium needed for normal spermatogenesis, provoked leydig cells degeneration, altered serum testosterone and gonadotrophin levels, and consequently suppressed spermatogenesis (Li *et al.*, 2013). Interestingly, the presence of spermatozoa and the intact stages of spermatogenesis in the seminiferous tubules of pigeons intoxicated with 10 and 20 mg/Kg/day of cypermethrin indicated that these birds were not in the refractoriness period.

In birds, gonadal development and regression appear to be a seasonal phenomenon, generated and synchronized by external factors such as day length, food availability, etc. (Budki *et al.*, 2009). Therefore, all metabolic and reproductive processes depend on the day length as a principal regulator of the circadian clock (Hahn and Shackleton, 2008; Dixit and Singh, 2011), which is the primary environmental factors that can influence the timing of reproduction (Dawson *et al.*, 2001; Kumar *et al.*, 2004).

The present study demonstrates that *in vivo* exposure to cypermethrin at two doses under long days (19L: 5D) impaired pigeons' reproductive functions by altering gonadal volumes and weights.

At the physiological level, it is difficult to discuss the correlation between the inhibiting effect of pesticides and birds' reproductive function. Thus, cypermethrin is considered as an endocrine disruptor compounds (EDC) that has a potential to alter the endocrine system by interfering with different pathways in some organisms and may affect growth, metabolism, behavior and contribute in disturbing gonadal and adrenal axes as well as thyroid function (Mnif *et al.*, 2011; Jin *et al.*, 2011; Landrigan *et al.*, 1999; Liu *et al.*, 2006). EDCs can affect the hypothalamic-pituitary-thyroid (HPT) axis and alter central regulation, synthesis, and distribution of thyroid hormones receptors (Boas *et al.*, 2012; Crofton *et al.* 2008). It is possible that cypermethrin indirectly acted at the level of hypothalamus or pituitary gland, or directly acted on testicular tissues

by influencing the androgen biosynthesis pathways that reduce pituitary gonadotrophins (FSH and LH) secretions (Biswas and Ghosh, 2004; Pareek *et al.*, 2007). It has been demonstrated that the insecticide chlorodime form may act at the level of the hypothalamus level to suppress GnRH release, leading to destroying endocrinologic homeostasis (Goldman *et al.*, 1990). Xenobiotics have also been reported to affect the feedback mechanism of the pituitary and the hypothalamus as a result of their toxicity to the gonads (Pasqualini *et al.*, 1990). Furthermore, epidemiological and experimental studies strongly suggest that exposure to cypermethrin would have adverse effects on fertility and offspring impairments (Elbetieha *et al.*, 2001).

The decreased sperm motility in the current study may indicate the toxic effect of CYP on the germ cells, which has increased proportionally with increasing dose level, in which there is a clear relationship between sperm specific morphology and sperm motility, as it was reported earlier that reduced motility was probably owed to the spermatozoa morphological alterations (Kasker *et al.*, 1994).

The increase in the frequency of abnormal sperm production was speculated to be a consequence of organelles damaging, leading to sperm malformation (Narayana *et al.*, 2002) as it was noticed that CYP induced an important morphological alterations of sperm head in rats (Li *et al.*, 2013). Furthermore, mutagenic effects of pyrethroids on germ cells was confirmed by CYP (Codrington *et al.*, 2004) as well as deltamethrin (Bhunaya and Pati, 1990).

In the present investigation, the significant increase in plasma thyroxin at week 10 is due to the exposure to long days (19L: 5D). Therefore, thyroid gland plays a critical role in the etiological regulation of seasonal reproduction in birds (Boulakoud and Goldsmith, 1991), leading to the manifestation of refractoriness under long days. However, the thyroidectomized birds that held under long day lengths stayed fully mature (Goldsmith and Nicholls, 1984).

Plasma thyroxine was found to increase in starlings transferred from short days to long days (Dawson, 1989). Moreover, exogenous thyroxin administration into sexually mature starling held under long days has induced spontaneous gonadal atrophy, and decreased plasma gonadotrophin levels and plumage molt (Goldsmith and Nicholls, 1984). This, in turn, could lead to photo-refractoriness, and hence reduces GnRH output and gonadal regression (Boulakoud and Goldsmith, 1991).

On the other hand, pigeons exposed to CYP showed a considerable decrease in plasma thyroxin at the 10th week, which indicates the inhibiting effect of this insecticide on the regulating process of the thyroid activity. This result agrees with other findings that observed a decrease in T4

levels in antracol treated pigeon (Slimani *et al.*, 2014). A disruption in T4 and T3 levels of rats administrated with CYP (Yousef *et al.*, 2019; Azubuikwe, 2016). Moreover, the administration of the thyroxinor, a thyroxin inhibitor, to Japanese quail (Follett *et al.*, 1988) and starlings (Boulakoud and Goldsmith, 1991) caused disruptions of gonadal growth.

The results of molt scores throughout the experimental period are in proportionality with the trends indicated by the testicular volume data in control pigeons. Thus, the post-nuptial molt as a physiological effector is required with photo-refractoriness (Reinert and Wilson, 1997). Though, postnuptial molt in pigeons was known to begin between weeks 7 and 10 under a long photoperiod (Slimani *et al.*, 2014, 2018). Therefore, the absence of the molting process in birds, where male pigeons kept the primary flight feathers, is probably linked to the toxic effect of CYP on physiological activities, excluding the refractoriness effect.

In the present study, it has been shown that *P. odora* aqueous extract coadministration was effective in attenuating the reprotoxicity of CYP under an artificial long photoperiod (19L:5D), in which birds implemented a near complete reproductive cycle characterized by photostimulation and photorefractation represented by full mature testes at the 6th week, followed by spontaneous gonadal regression and a better molting scores at the 8th and 10th week. The beneficial effects of *P. odora* on CYP-intoxicated pigeons might be explained by the presence of many active antioxidant compounds like polyphenols. The latter may have free radical-scavenging activities (Imafidon *et al.*, 2016; Trivedi *et al.*, 2011).

Moreover, antioxidants can improve steroidogenesis by increasing testosterone synthesis and consequently enhancing Leydig cell function and promoting spermatogenesis (Prasad and rajalakshmi, 1989). *P. odora* is rich in quercetin (Williams *et al.*, 2003) that is a well-known flavonoid with a strong antioxidant activity, where it has been demonstrated to reduce oxidative stress in animals exposed to xenobiotics for a long period (Mahesh and Menon, 2004). Quercetin may have a direct free radical-scavenging activity as the superoxide radicals generated by the xanthine/ xanthine oxidase system (Dok-Go *et al.*, 2003). Moreover, quercetin at 1g/mL has not augmented the numbers of spermatogonial cells only, but it reduced Aroclor oxidative damage in the testes of embryonic chickens (species) (Zhang, 2005; Chandel *et al.*, 2008). In addition, *P. odora* roots essential oil was found to contains two major phenolic compounds; isobutyric acid 2-isopropyl-4-methyl-phenylester and 2-isopropyl-4-methylphenol (Zefzoufi *et al.*, 2020). The anti-oxidant activity of 2-isopropyl-4-methylphenol, was found to

be better than ascorbic acid and butylehydroxytoluene (Zefzoufi *et al.*, 2020). This could support the relieving effect shown in our study after *Pulicaria odora* treatment. Similarly, sage aqueous extract alleviated the toxic effects of cypermethrin on the sperm characteristics, the hypothalamic-pituitary-gonadal axis function and testicular histopathological alterations (Ahmadi *et al.*, 2013). Furthermore, Sesame oil (Abd El-Hameed *et al.*, 2020) and *H. odoratissimum* extracts (Meistrich, 1982) respectively prevented the reprotoxicity induced by cypermethrin and cyclophosphamide. Though, sperm parameter analysis is considered as the most credible sensitive test for spermatogenesis, as it provides important information on different stages of sperm production that is highly correlated with fertility potential.

The histological examinations of control pigeons subjected to a long photoperiod (19L: 5D) presented regular profiles after 10 weeks experimentation by demonstrating gonadal regression, which confirm the refractoriness period. On the other hand, the histological profiles of CYP groups revealed degenerative changes with an elongated and irregular diameter of seminiferous tubules, degenerative of Sertoli cells, severe atrophy of Leydig cells and pronounced decrease in the interstitial space. Besides, spermatogenesis appears unaffected with missing some stages, accompanied by immature and malformed spermatozoa of the lumen. Kouamo *et al.* (2021) demonstrated that Cypermethrin affects spermatogenesis as well as the histology of the seminiferous tubes, these modifications resulted in changes in reproductive parameters in the male quail (*Coturnix japonica*). Similar to our investigation. At larger doses, cypermethrin caused partial (20 days) to substantial (30 days) spermatogenesis loss at various stages in Japanese quail (Cigankova *et al.*, 1993). Because the Increase of morphological abnormalities in the middle piece and the flagellum can lead spermatozoa motility to decrease (Jahanian *et al.*, 2014). Another study found that anomalies in testicular structure included malformed and disorganized germ cells architecture, atrophic and distorted seminiferous tubules, reduced germ cells, Sertoli cells and Leydig cells, as well as spermatid vacuolization and multinucleated forms in the cypermethrin-treated rats (Yousef *et al.*, 2003). Adult pheasants treated to pyrethroid showed spermatocyte and spermatid deterioration and depletion (Creasy and Foster, 1991).

The *P. odora* aqueous extract co-administration to birds during 10 weeks seems protected the histological architecture of gonads through normalizing the seminiferous tubules and the total absence of spermatozoa in the lumen, indicating that this herb could preserve the ordinary physiological process by enabling birds to enter

into the refractoriness period safely.

The administration of *H. odoratissimum* extracts lessened the severity of Cyclophosphamide-induced histological damages in the testes, which may link to its antioxidant action (Watcho *et al.*, 2019), and also the *A. millefolium* inflorescences aqueous extract that was efficient in attenuating the action of free radicals generated during Cyclophosphamide-induced reprotoxicity in male Wistar rats (Shalizar *et al.*, 2013). A previous Histological study revealed that treatment with quercetin have ameliorated the marked damage and morphological changes in the seminiferous tubules caused by arsenic in adult male Sprague Dawley (SD) rats (Jahan *et al.*, 2015). Izawa *et al.* (2008) reported that quercetin can prevent testicular damage caused by diesel exhaust particles DEPs in mice. Another study showed that treatment with Vitamin C can protect the testis tissue against the imidacloprid' toxic effect in Japanese male quail bird from being malformed (Eissa, 2004).

CONCLUSIONS

In conclusion, this finding indicates that male pigeon (*Columba livia domestica*) under a long photoperiod of (19L: 5D) during ten weeks maintained a fully reproductive cycle characterized by testicular growth for 6 weeks, followed by gonadal regression. Spermogram parameters and the histological profiles indicated the existence of azoospermia in control birds with a higher plasma FT4 level towards the end of the experiment. The molting scores at the 8th and 10th week affirm the refractoriness period in these birds. However, the administration of CYP to male pigeons under long days adversely disrupted testicular development where sizes were raised. In addition, CYP had histopathological alterations demonstrated by enlarged diameter of seminiferous tubules, a Leydig cell atrophy, and a greater rate of malformed spermatozoa. The CYP-exposed pigeons were not in the refractoriness period with no evidence of flight feather molting. The PO aqueous extract co-administration has effectively alleviated most CYP adverse effects. As a whole, *P. odora* might be considered as a mitigating remedy against the reprotoxicity of CYP in male pigeons.

ACKNOWLEDGEMENTS

The authors would like to thank everyone who contributed financially and morally to this work. Thanks are given to the laboratory of animal Ecophysiology, the place where this research was conducted.

Statement of conflict of interest

The authors have declared no conflict of interest.

REFERENCES

- Abd El-Hameed, A.M., and Mahmoud, H.S., 2020. Cypermethrin induced apoptosis and testicular toxicity by upregulation of p53 in the brain and testis of male rats is alleviated by Sesame oil. *Taibah Univ. med. Sci.*, **14**: 1342-1349. <https://doi.org/10.1080/16583655.2020.1822057>
- Ahmadi, R., Balali, S., Tavakoli, P., Mafi, M., and Haji, G.R., 2013. The effect of hydroalcoholic leaf extract of *Salvia officinalis* on serum levels of FSH, LH, testosterone and testicular tissue in rats. *J. Kashan Univ. Med. Sci. (Feyz)*, **17**: 225-231.
- Azubiike, U.S., David, O., Ibrahim, R.P., Sankey, R.J., Chika, C.I., and James, S.S., 2016. Thyroid pathology of cypermethrin and its reproductive implications in Yankasa Rams. *Int. J. Biomed. Mater. Res.*, **4**: 43-48. <https://doi.org/10.11648/j.ijbmr.20160403.16>
- Barlow, S.M., Sullivan, F.M., and Lines, J., 2001. Risk assessment of the use of deltamethrin on bednets for the prevention of malaria. *Fd. Chem. Toxicol.*, **39**: 407-422. [https://doi.org/10.1016/S0278-6915\(00\)00152-6](https://doi.org/10.1016/S0278-6915(00)00152-6)
- Bellakhdar, J., 1997. *Contribution à l'étude de la pharmacopée traditionnelle au Maroc: la situation actuelle, les produits, les sources du savoir (enquête ethnopharmacologique de terrain réalisée de 1969 à 1992)*. Doctoral dissertation, Université Paul Verlaine-Metz.
- Bhunya, S.P., and Pati, P.C., 1990. Effect of deltamethrin, a synthetic pyrethroid, on the induction of chromosome aberrations, micronuclei and sperm abnormalities in mice. *Mutagenesis*, **5**: 229-232. <https://doi.org/10.1093/mutage/5.3.229>
- Biswas, N.M., and Ghosh, P., 2004. Effect of lead on male gonadal activity in albino rats. *Kathmandu Univ. med. J.*, **2**: 43-46.
- Blanco-Rodriguez, J., and Martinez-Garcia, C. 1998. Apoptosis precedes detachment of germ cells from the seminiferous epithelium after hormone suppression by short-term oestradiol treatment of rats. *Int. J. Androl.*, **21**: 109-115. <https://doi.org/10.1046/j.1365-2605.1998.00109.x>
- Boas, M., Feldt-Rasmussen, U., and Main, K.M., 2012. Thyroid effects of endocrine disrupting chemicals. *Mol. Cell. Endocrinol.*, **355**: 240-248. <https://doi.org/10.1016/j.mce.2011.09.005>
- Boulakoud, M.S., and Goldsmith, A.R., 1991. Thyroxine

- treatment induces changes in hypothalamic gonadotrophin-releasing hormone characteristic of photo refractoriness in starlings (*Sturnus vulgaris*). *Gen. Comp. Endocrinol.*, **82**: 78-85. [https://doi.org/10.1016/0016-6480\(91\)90298-K](https://doi.org/10.1016/0016-6480(91)90298-K)
- Boulakoud, M.S., and Goldsmith, A.R., 1994. Acquisition of photosensitivity in castrated male starlings (*Sturnus vulgaris*) under short day photoperiods. *Reproduction*, **100**: 77-79. <https://doi.org/10.1530/jrf.0.1000077>
- Budki, P., Rani, S., and Kumar, V., 2009. Food deprivation during photosensitive and photorefractory life-history stages affects the reproductive cycle in the migratory red-headed bunting (*Emberiza bruniceps*). *J. exp. Biol.*, **212**: 225-230. <https://doi.org/10.1242/jeb.024190>
- Chandel, A., Dhindsa, S., Topiwala, S., Chaudhuri, A., and Dandona, P., 2008. Testosterone concentration in young patients with diabetes. *Diabetes Care*, **31**: 2013-2017. <https://doi.org/10.2337/dc08-0851>
- Chapin, R.E., and Lamb, J.C., 1984. Effects of ethylene glycol monomethyl ether on various parameters of testicular function in the F344 rat. *Environ. Hlth. Perspect.*, **57**: 219-224. <https://doi.org/10.1289/ehp.8457219>
- Cigankova, V., Kacmar, P., Neuschl, J., Tomajkova, E., Poracova, J., and Konrad, V., 1993. Light and electron microscopical observations on the pheasant testis after pyrethroid application. *Folia Vet.*, **37**: 95-98.
- Codrington, A.M., Hales, B.F., and Robaire, B., 2004. Spermiogenic germ cell phase specific DNA damage following cyclophosphamide exposure. *J. Androl.*, **25**: 354-362. <https://doi.org/10.1002/j.1939-4640.2004.tb02800.x>
- Cowan, M.M.B., 1999. Isolation of carvacrol assimilating microorganisms. *Biotechnology*, **39**: 341-345.
- Creasy, D.M., and Foster, P.M., 1991. Male reproductive system. In: *Handbook of toxicological pathology* (eds. W.M. Haschetk and C.G. Rousseaux). Academic Press Inc. San Diaego. 1991. pp. 829-890. <https://doi.org/10.1016/B978-0-12-330220-5.50028-0>
- Crofton, K.M., Foss, J.A., Hass, U., Jensen, K.F., Levin, E.D., and Parker, S.P., 2008. Undertaking positive control studies as part of developmental neurotoxicity testing: A report from the ILSI research foundation/ risk science institute expert working group on neurodevelopmental endpoints. *Neurotoxicol. Teratol.*, **30**: 266-287. <https://doi.org/10.1016/j.ntt.2007.06.002>
- Dawson, A., 1989. Pharmacological doses of thyroxine simulate the effects of increased daylength, and thyroidectomy, decreased day length on the reproductive system of European starlings. *J. exp. Zool.*, **249**: 62-67. <https://doi.org/10.1002/jez.1402490112>
- Dawson, A., Follett, B.K., Goldsmith, A.R., and Nicholls, T.J., 1985. Hypothalamic gonadotrophin-releasing hormone and pituitary and plasma FSH and prolactin during photostimulation and photorefractoriness in intact and thyroidectomized starlings (*Sturnus vulgaris*). *J. Endocrinol.*, **105**: 71-77. <https://doi.org/10.1677/joe.0.1050071>
- Dawson, A., King, V.M., Bentley, G.E., and Ball, G.F., 2001. Photoperiodic control of seasonality in birds. *J. Biol. Rhythms.*, **16**: 365-380. <https://doi.org/10.1177/074873001129002079>
- Dixit, A.S., and Singh, N.S., 2011. Photoperiod as a proximate factor in control of seasonality in the subtropical male tree sparrow, *Passer montanus*. *Front. Zool.*, **8**: 1-12. <https://doi.org/10.1186/1742-9994-8-1>
- Dok-Go, H., Lee, K.H., Kim, H.J., Lee, E.H., Lee, J., Song, Y.S., and Cho, J., 2003. Neuroprotective effects of antioxidative flavonoids, quercetin, (+)-dihydroquercetin and quercetin 3-methyl ether, isolated from *Opuntia ficus-indica* var. *saboten*. *Brain Res.*, **965**: 130-136. [https://doi.org/10.1016/S0006-8993\(02\)04150-1](https://doi.org/10.1016/S0006-8993(02)04150-1)
- Eells, J.T., and Dubocovich, M.L., 1988. Pyrethroid insecticides evoke neurotransmitter release from rabbit striatal slices. *J. Pharmacol. exp. Ther.*, **246**: 514-521.
- Eissa, O.S., 2004. Protective effect of vitamin C and glutathione against the histopathological changes induced by imidacloprid in the liver and testis of Japanese quail. *Egypt. J. Hosp. Med.*, **16**: 39-54. <https://doi.org/10.21608/ejhm.2004.18174>
- Elbetieha, A., Da'As, S.I., Khamas, W., and Darmani, H., 2001. Evaluation of the toxic potentials of cypermethrin pesticide on some reproductive and fertility parameters in the male rats. *Environ. Contam. Toxicol.*, **41**: 522-528. <https://doi.org/10.1007/s002440010280>
- Flodström, S., Wärngård, L., Ljungquist, S., and Ahlborg, U.G., 1988. Inhibition of metabolic cooperation *in vitro* and enhancement of enzyme altered foci incidence in rat liver by the pyrethroid insecticide fenvalerate. *Arch Toxicol.*, **61**: 218-223. <https://doi.org/10.1007/BF00316637>
- Follett, B.K., Nicholls, T.J., and Mayes, C.R., 1988. Thyroxine can mimic photoperiodically induced

- gonadal growth in Japanese quail. *J. comp. Physiol.*, **157**: 829-835. <https://doi.org/10.1007/BF00691015>
- Giray, B., Gu'rbay, A., and Hincal, F., 2001. Cypermethrin-induced oxidative stress in rat brain and liver is prevented by vitamin E or allopurinol. *Toxicol. Lett.*, **118**: 139-146. [https://doi.org/10.1016/S0378-4274\(00\)00277-0](https://doi.org/10.1016/S0378-4274(00)00277-0)
- Goldman, J.M., Cooper, R.L., Laws, S.C., Rehnberg, G.L., Edwards, T.L., McElroy, W.K., and Hein, J.F., 1990. Chlordimeform-induced alterations in endocrine regulation within the male rat reproductive system. *Toxicol. appl. Pharmacol.*, **104**: 25-35. [https://doi.org/10.1016/0041-008X\(90\)90279-4](https://doi.org/10.1016/0041-008X(90)90279-4)
- Goldsmith, A.R., and Nicholls, T.J., 1984. Thyroidectomy prevents the development of photorefractoriness and the associated rise in plasma prolactin in starlings. *Gen. comp. Endocrinol.*, **54**: 256-263. [https://doi.org/10.1016/0016-6480\(84\)90179-5](https://doi.org/10.1016/0016-6480(84)90179-5)
- Goldsmith, A.R., and Nicholls, T.J., 1984. Thyroxine induces photorefractoriness and stimulates prolactin secretion in European starlings (*Sturnus vulgaris*). *J. Endocrinol.*, **101**: R1-3.
- Gupta, A., Nigam, D., Gupta, A., Shukla, G.S., and Agarwal, A.K., 1999. Effect of pyrethroid-based liquid mosquito repellent inhalation on the blood-brain barrier function and oxidative damage in selected organs of developing rats. *J. appl. Toxicol.*, **19**: 67-72. [https://doi.org/10.1002/\(SICI\)1099-1263\(199901/02\)19:1<67::AID-JAT540>3.0.CO;2-#](https://doi.org/10.1002/(SICI)1099-1263(199901/02)19:1<67::AID-JAT540>3.0.CO;2-#)
- Jahan, S., Iftikhar, N., Ullah, H., Rukh, G. and Hussain, I., 2015. Alleviative effect of quercetin on rat testis against arsenic: a histological and biochemical study. *Syst. Biol. Reprod. Med.*, **61**: 89-95. <https://doi.org/10.3109/19396368.2014.998350>
- Hahn, T.P., and MacDougall-Shackleton, S.A., 2008. Adaptive specialization, conditional plasticity and phylogenetic history in the reproductive cue response systems of birds. *Phil. Trans. R. Soc. Lond. B Biol. Sci.*, **363**: 267-286. <https://doi.org/10.1098/rstb.2007.2139>
- Hall, B.E., Vickers, J.A., and Hopkins, J.A., 1980. A study to determine the bioaccumulation of ¹⁴C-cypermethrin radioactivity in the rat following repeated oral administration. *WHO Report*, **20**: 2487-2472.
- Hanbali, F. E., Akssira, M., Ezoubeiri, A., Mellouki, F., Benherraif, A., Blazquez, A. M., and Boira, H. 2005. Chemical composition and antibacterial activity of essential oil of *Pulicaria odora* L. *J. Ethnopharmacol.*, **99**: 399-401. <https://doi.org/10.1016/j.jep.2005.01.012>
- He, F., 2000. Neurotoxic effects of insecticides current and future research: A review. *Neurotoxicology*, **21** : 829-835.
- Hould, R., 1998. *Techniques d'histopathologie et de cytopathologie*. Centre collégial de développement de matériel didactique; Cégep de Shawinigan; Direction générale des moyens d'enseignement.
- Hu, J.X., Li, Y.F., Li, J., Pan, C., He, Z., Dong, H.Y., and Xu, L.C., 2013. Toxic effects of cypermethrin on the male reproductive system with emphasis on the androgen receptor. *J. appl. Toxicol.*, **33**: 576-585. <https://doi.org/10.1002/jat.1769>
- Imafidon, C.E., Risikat, O.T., Samuel, B.F., Esther, O.O., and Aderonke, A.K., 2016. Cadmium-induced testicular toxicity, oxidative stress and histopathology in Wistar rats: Sustained effects of polyphenol-rich extract of Vernonia amygdalina (Del.) leaf. *J. Interdisciplin. Histopathol.*, **4**: 54-62. <https://doi.org/10.5455/jihp.20160618041629>
- Iwanicka, N.B., and Borzęcki, A., 2015. Subacute poisoning of mice with deltamethrin produces memory impairment, reduced locomotor activity, liver damage and changes in blood morphology in the mechanism of oxidative stress. *Pharmacol. Rep.*, **67**: 535-541. <https://doi.org/10.1016/j.pharep.2014.12.012>
- Izawa, H., Kohar, M., Aizawa, K., Suganuma, H., Inakuma, T., Watanabe, G., Taya, K. and Sagai, M., 2008. Alleviative effects of quercetin and onion on male reproductive toxicity induced by diesel exhaust particles. *Biosci. Biotech. Biochem.*, **72**: 1235-1241. <https://doi.org/10.1271/bbb.70705>
- Jahanian, E., Asadollahpour, N.H., and Moradi, K.N., 2014. Influence of oxidative stress on sperm quality in animal. *Int. J. Biosci.*, **4**: 10-16. <https://doi.org/10.12692/ijb/4.2.10-16>
- Jin, Y., Wang, L., Ruan, M., Liu, J., Yang, Y., Zhou, C., and Fu, Z., 2011. Cypermethrin exposure during puberty induces oxidative stress and endocrine disruption in male mice. *Chemosphere*, **84**: 124-130. <https://doi.org/10.1016/j.chemosphere.2011.02.034>
- Kale, M., Rathore, N., John, S., and Bhatnagar, D., 1999. Lipid peroxidation and antioxidant enzymes in rat tissues in pyrethroid toxicity: Possible involvement of reactive oxygen species. *J. Nutr. environ. Med.*, **9**: 37-46. <https://doi.org/10.1080/13590849961825>
- Kaskar, K., Franken, D.R., Van Der Horst, G., Oehninger, S., Kruger, T.F., and Hodgen, G.D., 1994. The relationship between morphology, motility and zona pellucida binding potential of

- human spermatozoa. *Andrologia*, **26**: 1-4. <https://doi.org/10.1111/j.1439-0272.1994.tb00744.x>
- Kelce, W.R., and Wilson, E.M., 1997. Environmental antiandrogens: developmental effects, molecular mechanisms, and clinical implications. *J. mol. Med.*, **75**: 198-207. <https://doi.org/10.1007/s001090050104>
- Kirby, M.L., Castagnoli, K., and Bloomquist, J.R., 1999. *In vivo* effects of deltamethrin on dopamine neurochemistry and the role of augmented neurotransmitter release. *Pestic. Biochem. Physiol.*, **65**: 160-168. <https://doi.org/10.1006/pest.1999.2440>
- Kjeldsen, L.S., Ghisari, M., and Bonefeld-Jørgensen, E.C., 2013. Currently used pesticides and their mixtures affect the function of sex hormone receptors and aromatase enzyme activity. *Toxicol. appl. Pharmacol.*, **272**: 453-464. <https://doi.org/10.1016/j.taap.2013.06.028>
- Klimek, J., 1990. Cytochrome P-450 involvement in the NADPHdependent lipid peroxidation in human placental mitochondria. *Biochem. biophys. Acta*, **1044**: 158-164. [https://doi.org/10.1016/0005-2760\(90\)90231-L](https://doi.org/10.1016/0005-2760(90)90231-L)
- Kouamo, J., Mayang, S.P., Djitie, F.K., and Mamoudou, A., 2021. Effects of cypermethrin on growth, biochemical and reproductive parameters in male quails (*Coturnix japonica*). *J. Vet. Androl.*, **6**:
- Kumar, V., Singh, B.P., and Rani, S., 2004. The bird clock: A complex, multi-oscillatory and highly diversified system. *Biol. Rhythms. Res.*, **35**: 121-144. <https://doi.org/10.1080/09291010412331313287>
- Landrigan, P.J., Claudio, L., Markowitz, S.B., Berkowitz, G.S., Brenner, B.L., Romero, H., and Wolff, M.S., 1999. Pesticides and inner-city children: Exposures, risks, and prevention. *Environ. Hlth. Perspect.*, **107(Suppl. 3)**: 431-437. <https://doi.org/10.1289/ehp.99107s3431>
- Latif, A., Khan, A., Khan, M.Z., Hussain, I., Mahmood, F., Sleemi, M.K., and Abdullah, I., 2012. Toxicopathological effects of cypermethrin upon male reproductive system in rabbits. *Pestic. Biochem. Physiol.*, **103**: 194-201. <https://doi.org/10.1016/j.pestbp.2012.05.004>
- Li, Y.F., Chen, P.A.N., Hu, J.X., Jing, L.I., and Xu, L.C., 2013. Effects of cypermethrin on male reproductive system in adult rats. *Biomed. environ. Sci.*, **26**: 201-208.
- Liu, P., Song, X., Yuan, W., Wen, W., Wu, X., Li, J., and Chen, X., 2006. Effects of cypermethrin and methyl parathion mixtures on hormone levels and immune functions in Wistar rats. *Arch. Toxicol.*, **80**: 449-457. <https://doi.org/10.1007/s00204-006-0071-7>
- Mahesh, T., and Menon, V.P., 2004. Quercetin alleviates oxidative stress in streptozotocin-induced diabetic rats. *Phytother. Res.*, **18**: 123-127. <https://doi.org/10.1002/ptr.1374>
- Manna, I., Jana, K., and Samanta, P.K., 2004. Intensive swimming exercise-induced oxidative stress and reproductive dysfunction in male Wistar rats: Protective role of α -tocopherol succinate. *Can. J. appl. Physiol.*, **29**: 172-185. <https://doi.org/10.1139/h04-013>
- Manna, S., Bhattacharyya, D., Mandal, T.K., and Dey, S., 2005. Neuropharmacological effects of alfacypermethrin in rats. *Indian J. Pharmacol.*, **37**: 18. <https://doi.org/10.4103/0253-7613.13849>
- Meistrich, M.L., 1982. Quantitative correlation between testicular stem cell survival, sperm production, and fertility in the mouse after treatment with different cytotoxic agents. *J. Androl.*, **3**: 58-68. <https://doi.org/10.1002/j.1939-4640.1982.tb00646.x>
- Michelangeli, F., Robson, M.J., East, J.M., and Lee, A.G., 1990. The conformation of pyrethroids bound to lipid bilayers. *Biochim. biophys. Acta Biomembr.*, **1028**: 49-57. [https://doi.org/10.1016/0005-2736\(90\)90264-O](https://doi.org/10.1016/0005-2736(90)90264-O)
- Mnif, W., Hassine, A.I.H., Bouaziz, A., Bartegi, A., Thomas, O., and Roig, B., 2011. Effect of endocrine disruptor pesticides: A review. *Int. J. environ. Res. Publ. Hlth.*, **8**: 2265-2303. <https://doi.org/10.3390/ijerph8062265>
- Nandi, P., Talukder, G., and Sharma, A., 1997. Dietary chemoprevention of clastogenic effects of 3, 4-benzo (a) pyrene by *Emblia officinalis* Gaertn. fruit extract. *Br. J. Cancer*, **76**: 1279-1283. <https://doi.org/10.1038/bjc.1997.548>
- Narahashi, T., Frey, J.M., Ginsburg, K.S., and Roy, M.L., 1992. Sodium and GABA-activated channels as the targets of pyrethroids and cyclodienes. *Toxicol. Lett.*, **64**: 429-436. [https://doi.org/10.1016/0378-4274\(92\)90216-7](https://doi.org/10.1016/0378-4274(92)90216-7)
- Narayana, K., D'Souza, U.J., and Rao, K.S., 2002. Ribavirin-induced sperm shape abnormalities in Wistar rat. *Mutat. Res. Genet. Toxicol. Environ. Mutagen.*, **513**: 193-196. [https://doi.org/10.1016/S1383-5718\(01\)00308-4](https://doi.org/10.1016/S1383-5718(01)00308-4)
- Nasuti, C., Gabbianelli, R., Falcioni, M.L., Di Stefano, A., Sozio, P., and Cantalamessa, F., 2007. Dopaminergic system modulation, behavioral changes, and oxidative stress after neonatal administration of pyrethroids. *Toxicology*, **229**:

- 194-205. <https://doi.org/10.1016/j.tox.2006.10.015>
- Orlu, E.E., 2014. Deltamethrin-induced alterations in sperm morphology and spermatogenesis impairment in adult sprague-dawley rats. *Res. J. appl. Sci. Eng. Technol.*, **7**: 2324-2331. <https://doi.org/10.19026/rjaset.7.532>
- Palanisamy, S., Telang, A.G., and Manimaran, A., 2012. Protective effect of curcumin on cypermethrin-induced oxidative stress in Wistar rats. *Exp. Toxicol. Pathol.*, **64**: 487-493. <https://doi.org/10.1016/j.etp.2010.11.003>
- Pareek, T.K., Joshi, A.R., Sanyal, A., and Dighe, R.R., 2007. Insights into male germ cell apoptosis due to depletion of gonadotropins caused by GnRH antagonists. *Apoptosis*, **12**: 1085-1100. <https://doi.org/10.1007/s10495-006-0039-3>
- Pasqualini, C., Sarrieau, A., Dussaillant, M., Corbani, M., Bojda-Diolez, F., Rostène, W., and Kerdelhué, B., 1990. Estrogen-like effects of 7, 12-dimethylbenz (a) anthracene on the female rat hypothalamo-pituitary axis. *J. Steroid Biochem.*, **36**: 485-491. [https://doi.org/10.1016/0022-4731\(90\)90092-7](https://doi.org/10.1016/0022-4731(90)90092-7)
- Prasad, M.R.N., and Rajalakshmi, M., 1989. Spermatogenesis and accessory gland secretions. *Textb. Biochem. Hum. Biol.*, **2**: 883.
- Reinert, B.D., and Wilson, F.E., 1997. Effects of thyroxine (T4) or triiodothyronine (T3) replacement therapy on the programming of seasonal reproduction and postnuptial molt in thyroidectomized male American tree sparrows (*Spizella arborea*) exposed to long days. *J. exp. Zool.*, **279**: 367-376. [https://doi.org/10.1002/\(SICI\)1097-010X\(19971101\)279:4<367::AID-JEZ6>3.0.CO;2-M](https://doi.org/10.1002/(SICI)1097-010X(19971101)279:4<367::AID-JEZ6>3.0.CO;2-M)
- Shalizar, A.J., Shapour, H., and Hassan, M., 2013. Beneficial effects of Achillea millefolium aqueous extract against cyclophosphamide-induced reproductive toxicity. *J. exp. Integr. Med.*, **3**: <https://doi.org/10.5455/jeim.110313.or.061>
- Sharma, P., Huq, A.U., and Singh, R., 2014. Cypermethrin-induced reproductive toxicity in the rat is prevented by resveratrol. *J. Hum. Reprod. Sci.*, **7**: 99. <https://doi.org/10.4103/0974-1208.138867>
- Sharma, S., Sharma, M., and Singh, G., 2020. A chaotic and stressed environment for 2019-nCoV suspected, infected and other people in India: Fear of mass destruction and causality. *Asian J. Psychiatr.*, **51**: 102049. <https://doi.org/10.1016/j.ajp.2020.102049>
- Slimani, S., Boulakoud, M.S., Abdennour, C., and Gueddah, D., 2014. Antracol administration has disturbed the reproductive cycle of domestic pigeon *Columba livia domestica*. *Adv. environ. Biol.*, pp. 82-92.
- Slimani, S., Hamouda, S., Souadi, C., Silini, S., Abdennour, C., and Delimi, L., 2018. The fungicide thiram may disrupt reproductive cycle of domestic male pigeon (*Columba livia domestica*) subjected to a long photoperiod. *Pakistan J. Zool.*, **50**: 1693-1701. <https://doi.org/10.17582/journal.pjz/2018.50.5.1693.1701>
- Solati, J., Hajikhani, R., and Toodeh, Z.R., 2010. Effects of cypermethrin on sexual behaviour and plasma concentrations of pituitary-gonadal hormones. *Int. J. Fertil. Steril.*, **4**: 23-28.
- Stefanovits-Bányai, É., 2003. Antioxidant effect of various rosemary (*Rosmarinus officinalis* L.) clones. *Acta Biol. Szeged*, **47**: 111-113.
- Suzan, A.A.A., 2012. The pathological effect of cypermethrin on domestic pigeons (*Culumba livia gaddi*) at Basrah City/ Southern Iraq. *Int. J. Poult. Sci.*, **11**: 302-310. <https://doi.org/10.3923/ijps.2012.302.310>
- Touati, N., Casas, L., Mantell, C., Martínez De La Ossam E., and Bedjou, F., 2014. *Green extraction methods of antioxidants from Pulicaria odora*. GPE 4th International Congress on Green Pro. Eng, Seville (Espagne).
- Trivedi, P.P., Tripathi, D.N., and Jena, G.B., 2011. Hesperetin protects testicular toxicity of doxorubicin in rat: role of NFκB, p38 and caspase-3. *Fd. Chem. Toxicol.*, **49**: 838-847. <https://doi.org/10.1016/j.fct.2010.12.005>
- Wang, Y.J., Soheil, N., Tung-Ti, C.J., 2001. Role of retinoblastoma tumor suppressor protein in DNA damage response. *Acta Oncol.*, **40**: 689-695. <https://doi.org/10.1080/02841860152619098>
- Wang, R.S., Yeh, S., Tzeng, C.R., and Chang, C., 2009. Androgen receptor roles in spermatogenesis and fertility: Lessons from testicular cell-specific androgen receptor knockout mice. *Endocr. Rev.*, **30**: 119-132. <https://doi.org/10.1210/er.2008-0025>
- Watcho, P., Mpeck, I.R., Defo, P.B.D., Wankeu-Nya, M., Ngadjui, E., Fozin, G.R.B., and Kamanyi, A., 2019. Cyclophosphamide-induced reproductive toxicity: Beneficial effects of *Helichrysum odoratissimum* (Asteraceae) in male Wistar rats. *J. Integr. Med.*, **17**: 366-373. <https://doi.org/10.1016/j.joim.2019.07.002>
- Williams, C.A., Harborne, J.B., Greenham, J.R., Grayer, R.J., Kite, G.C., and Eagles, J., 2003. Variations in lipophilic and vacuolar flavonoids among European *Pulicaria* species. *Phytochemistry*, **64**: 275-283. [https://doi.org/10.1016/S0031-9422\(03\)00207-3](https://doi.org/10.1016/S0031-9422(03)00207-3)

- Wingfield, J.C. and Farner, E., 1993. Endocrinology of reproduction in wild species. *J. Avian Biol.*, pp. 163-327.
- Wolansky, M.J., Gennings, C., and Crofton, K.M., 2006. Relative potencies for acute effects of pyrethroids on motor function in rats. *Toxicol. Sci.*, **89**: 271-277. <https://doi.org/10.1093/toxsci/kfj020>
- Xu, L.C., Sun, H., Chen, J.F., Bian, Q., Song, L., and Wang, X.R., 2006. Androgen receptor activities of p, p'-DDE, fenvalerate and phoxim detected by androgen receptor reporter gene assay. *Toxicol. Lett.*, **160**: 151-157. <https://doi.org/10.1016/j.toxlet.2005.06.016>
- Yousef, D.M., El-Fatah, S.S.A., and Hegazy, A.A., 2019. Protective effect of ginger extract against alterations of rat thyroid structure induced by cypermethrin administration. *J. exp. med. Biol.*, **1**: 19-25.
- Yousef, M.I., El-Demerdash, F.M., and Al-Salhen, K.S., 2003. Protective role of isoflavones against the toxic effect of cypermethrin on semen quality and testosterone levels of rabbits. *J. environ. Sci. Hlth. B*, **38**: 463-478. <https://doi.org/10.1081/PFC-120021666>
- Zefzoufi, M., Fdil, R., Bouamama, H., Mouzdahir, A., Sraidi, K., and Abouzaid, A., 2020. *Pulicaria odora* essential oil: A potential source of eco-friendly antioxidants and allelochemicals. *Mediterr. J. Chem.*, **10**: 608-618. <https://doi.org/10.13171/mjc10602006301405rf>
- Žegura, B., Lah, T.T., and Filipič, M., 2004. The role of reactive oxygen species in microcystin-LR-induced DNA damage. *Toxicology*, **200**: 59-68. <https://doi.org/10.1016/j.tox.2004.03.006>
- Zhang, Y.M.C., 2005. Protective effect of quercetin on Aroclor 1254-induced oxidative damage in cultured chicken spermatogonial cells. *Toxicol. Sci.*, **88**: 545-550. <https://doi.org/10.1093/toxsci/kfi333>
- Zitzmann, M., 2008. Effects of testosterone replacement and its pharmacogenetics on physical performance and metabolism. *Asian J. Androl.*, **10**: 364-372. <https://doi.org/10.1111/j.1745-7262.2008.00405.x>