



# Effect of Indigenous Probiotics on Gut Morphology and Intestinal Absorption Capacity in Broiler Chicken Challenged with *Salmonella enteritidis*

Imran Khan<sup>1</sup>, Muhammad Nawaz<sup>1,\*</sup>, Aftab Ahmad Anjum<sup>1</sup>, Mansur-ud-Din Ahmad<sup>2</sup>, Adnan Mehmood<sup>1</sup>, Masood Rabbani<sup>1</sup>, Amina Mustafa<sup>1</sup> and Muhammad Asad Ali<sup>1</sup>

<sup>1</sup>Department of Microbiology, University of Veterinary and Animal Sciences, Lahore

<sup>2</sup>Department of Epidemiology and Public Health, University of Veterinary and Animal Sciences, Lahore

## ABSTRACT

Probiotics are useful in modulating and strengthening the gut microbiota. Present study was designed to determine the effect of three previously characterized probiotic lactobacilli *i.e.* *L. fermentum* IKP 23, *L. fermentum* IKP 111 and *L. salivarius* IKP 333 on histomorphology of small intestine and D-xylose absorption capacity in broiler challenged with *S. enteritidis*. Negative control group was not supplemented with probiotics. Positive control groups received only the challenge bacteria (*S. enteritidis*) ATCC 13076 at day 07. Groups (3, 4 and 5) received probiotics (IKP23, IKP111, IKP333) at day 01 to 35 and challenge bacteria at day 07 in prevention model. Groups (6, 7 and 8) started receiving probiotic at day 07 to day 35 and challenge bacteria at day 07 in treatment model. Group 09 started receiving commercial probiotic Protexin (1g/litre) at day 01 to 35 and challenge bacteria at day 07. Group 10 started receiving antibiotic at day 01 to 10 and challenge bacteria at day 07. Birds were challenged with a single dose of 10<sup>6</sup> cfu of *Salmonella enteritidis* by oral gavage. D-xylose absorption capacity and gut morphometric parameters (villus height, crypt depth and villus height to crypt depth ratio) were studied at day 35. Broiler administered with IKP23, IKP111 and IKP333 significantly improved villus height and villus height to crypt depth ratio as compared to positive control. D-xylose absorption was also enhanced in groups administered with probiotics. It is concluded that IKP23, IKP111 and IKP333 may improve gut morphometric parameters and absorption capacity of broiler challenged with *S. enteritidis* which insinuate for their possible role in efficient broiler production.

## Article Information

Received 18 May 2019

Revised 12 June 2019

Accepted 29 June 2019

Available online 25 November 2019

## Authors' Contribution

MN, MUD and MR designed the project. IK and MAA collected samples. IK and AM executed experiments. MN and AAA analysed data. AM, IK and MN prepared the manuscript.

## Key words

Probiotics, *S. enteritidis*, Prevention model, Protexin, D-xylose.

## INTRODUCTION

Probiotics are live microorganisms which provide benefit to host upon sufficient administration (FAO-WHO, 2001). Probiotics provide a number of health benefits to poultry *i.e.* immune boosting, protection against gut pathogens, binding of mycotoxins, strengthening of gut function and microbiota, and increased absorption of nutrients leading to enhanced and efficient poultry production (Patterson and Burkholder, 2003; Park *et al.*, 2016; Azeem *et al.*, 2019). Poultry gastric tract is composed of crop, gizzard, jejunum, ileum, duodenum, and ceca. Intestinal health of poultry is directly linked with the gut function and nutrient absorption. Poultry gut contains a huge diversity of microorganisms including lactobacilli (Saleem *et al.*, 2018). Further strengthening of gut microbiome with probiotics provides huge benefits.

Probiotics increase villus height and crypt depth ratio in poultry gut intestine (Kim *et al.*, 2012). Increased villus height and crypt depth ratio are associated with growth performance in poultry (Ali *et al.*, 2017). Probiotics help in the improvement of gut health and can be used as growth promotor in broiler diets (Awad *et al.*, 2009).

Probiotics play an important role in improving the nutritional approach of poultry gut function and provide potential alternatives to antimicrobial growth promoter in poultry nutrition (Mountzouris *et al.*, 2007; Applegate *et al.*, 2010). *Salmonella enteritidis* is generally present in poultry gut and its transmission to human food chain is a major threat to public safety. It is one of the major causes of food poisoning and gastro-intestinal infections in human. It negatively impacts the nutrient absorption, gut function and intestinal health of birds (Ansari *et al.*, 2017). Use of antibiotics to control the Salmonellae in poultry is not only a risk factor for emergence of antibiotic resistance, it also leads to decreased gut microbiota and gut function (Apatha, 2012). Decreased gut microbiota may lead to reduced gut function and nutrient absorption. Prophylactic

\* Corresponding author: [muhammad.nawaz@uvas.edu.pk](mailto:muhammad.nawaz@uvas.edu.pk)  
0030-9923/2020/0001-0001 \$ 9.00/0

Copyright 2020 Zoological Society of Pakistan

use of antibiotics in poultry industry for the control and prevention of *Salmonella* have aggravated the problem of antibiotic resistance and antibiotic residues in animal and human food chains (Siddique *et al.*, 2018). Thus, the use of antibiotics especially as growth promoter should be prohibited in Pakistan and alternatives *i.e.* probiotics should be developed.

Probiotics play an important role in improving the nutrients availability and poultry gut function (Mountzouris *et al.*, 2007; Applegate *et al.*, 2010). Probiotics diet increase the villus height and villus height/crypt depth ratio in duodenum of poultry (Afsharmanesh and Sadaghi, 2014). Lactobacilli significantly increase weight of small intestine (jejunum and ileum) (Olnood *et al.*, 2015). Probiotics dietary treatments influence the histomorphological measurements in poultry and probiotics diet significantly increase the villus height/crypt depth ratio in duodenum and ileum (Awad *et al.*, 2009). D-xylose absorption test is very useful tool to assess the intestinal function efficiency. D-xylose is well absorbed from the small intestine and has been successfully used to evaluate the mal-absorption syndrome in birds caused by bacteria and viruses (Doerfler *et al.*, 2000). The birds with different health status show D-xylose absorption capacity (Shomali *et al.*, 2012).

Although there are few published reports on development of indigenous probiotics from Pakistan (Asghar *et al.*, 2016; Arif *et al.*, 2018), there still is insufficient data on effect of indigenously characterized probiotics on gut morphology and nutrient absorption capacity of broiler challenged with *Salmonella* from Pakistan. Therefore, current study was designed to analyse the effect of indigenously characterized probiotic strains on gut morphology and D-xylose absorption capacity in broiler.

## MATERIAL AND METHODS

### *Microorganisms and growth conditions*

Previously characterized potential probiotic strains *Lactobacillus fermentum* IKP 23 (MK350329), *L. fermentum* IKP 111 (MK350330) and *L. salivarius* IKP 333 (MK346270) were grown and maintained in MRS media. *Salmonella enteritidis* ATCC 13076 was procured from department of Microbiology, University of Veterinary and Animal Sciences, Lahore and grown in SS agar at 37°C.

### *Study design*

Day old broiler chicks (n=150) were procured from the local market and reared for 35 days in experimental shed in Department of Microbiology, University of Veterinary and Animal Sciences, Lahore. Chicks were

randomly distributed in 10 groups (15 chicks per groups). Negative control group was not supplemented with probiotics. Positive control groups received only the challenge bacteria (*S. enteritidis* ATCC 13076) at day 07. Groups (3, 4 and 5) received probiotics (IKP23, IKP111, IKP333) from day 1 to 35 and challenge bacteria at day 7 in prevention model (PM). Groups (6, 7 and 8) started receiving probiotic at day 7 to day 35 and challenge bacteria at day 7 in treatment model (TM). Group 09 started receiving commercial probiotic Protexin (Hilton Pharma) 1g/litre (10<sup>7</sup> cfu/ml) at day 1 to 35 and challenge bacteria at day 7. Group 10 started receiving antibiotic (enrofloxacin) at day 1 to 10 and challenge bacteria at day 7. Birds were challenged with a single dose of 10<sup>6</sup> cfu of *Salmonella enteritidis* by oral gavage, while probiotics were administered 10<sup>8</sup> cfu daily.

### *Intestinal morphometric parameters*

On day 35, 5 birds from each group were randomly slaughtered and intestinal tissue samples (duodenum, ileum and jejunum) were collected. Samples were fixed in 10% neutral buffered formaldehyde, embedded in paraffin, cut into fine sections, and stained with haematoxylin and eosin stain as described previously (Awad *et al.*, 2009). Slides were examined with a light microscope (Olympus CX31, USA) attached with a digital imaging system and analysed by using Labomed pixel pro software. The morphometric variable including villus height, crypt depth and villus height/crypt depth ratios were measured.

### *D-xylose absorption capacity test of broiler*

D-xylose absorption capacity in broiler of different groups was also determined on day 35 as described previously (Mansoori *et al.*, 2012). Briefly, five birds from each group were randomly selected for D-xylose absorption test. D-xylose (Merck, Germany) was given via oral route @ 500mg D-xylose/kg body weight to each bird. The blood samples were drawn from ulnar vein in wings at pre-inoculation and post-inoculation (30 min and 60 min) of D-xylose. D-xylose was measured from plasma using phloroglucinol reagent as described previously (Regassa *et al.*, 2016). Briefly, 20 µl plasma was mixed with 2 ml phloroglucinol reagent, heated for 4 min at 100°C, cooled to room temperature followed by reading the absorbance at 554 nm using spectrophotometer (UV-150-02 Shimadzu Corporation, Japan) Concentration of D-xylose in plasma was measured from a D-xylose standard curve prepared from different concentrations (5-75 mg/dl) of D-xylose.

### *Statistical analysis*

Data were expressed as Mean±S.D and means of different groups were compared by one way ANOVA

followed by Tukey's multiple comparison test at P value <0.05 by GraphPad Prism Software.

**Table I.- Effects of probiotic on gut (duodenum) morphology in broiler chickens.**

Groups	Villus height (um) (Mean± S.D)	Crypt depth (um) (Mean± S.D)	Villus height/ Crypt depth ratio
Negative control	646.67±52.51	98.33±16.07	6.58 <sup>a</sup>
Positive control	709.67±74.56	115.67±8.14	6.14 <sup>a</sup>
IKP 23-PM	818.53±52.47	108.67±24.24	8.03 <sup>b</sup>
IKP 111-PM	741.67±66.01	91.53±10.63	8.10 <sup>b</sup>
IKP 333-PM	725.43±83.71	90.33±11.67	8.07 <sup>b</sup>
Protexin-PM	660.59±101.91	86.28±5.46	7.66 <sup>a</sup>
Antibiotic-PM	656.67± 78.47	107.90± 5.85	6.09 <sup>a</sup>
IKP 23-TM	683.18±61.74	91.71±4.77	7.45 <sup>a</sup>
IKP 111-TM	596.40±28.71	96.74±14.41	6.17 <sup>a</sup>
IKP 333-TM	629.24±82.19	92.42±4.72	6.81 <sup>a</sup>

<sup>a,b</sup> different superscript show statistically significant difference at p ≤ 0.05.

**Table II.- Effects of probiotics on gut (jejunum) morphology in broiler chickens.**

Groups	Villus height (um) (Mean± S.D)	Crypt depth (um) (Mean± S.D)	Villus height/ Crypt depth ratio
Negative control	805.73±65.76	123.52±14.87	6.52 <sup>a</sup>
Positive control	686.67±37.52	107.57±2.40	6.38 <sup>a</sup>
IKP 23-PM	1231.47±45.36	103.67±10.88	11.88 <sup>b</sup>
IKP 111-PM	953.47±149.53	100.00±18.02	9.53 <sup>b</sup>
IKP 333-PM	1185.83±122.04	143.80±23.68	8.25 <sup>b</sup>
Protexin-PM	564.28±6.89	79.95±10.52	7.06 <sup>a</sup>
Antibiotic-PM	670.30±62.56	110.98±10.70	6.04 <sup>a</sup>
IKP 23-TM	1015.87±8.20	138.67±54.26	7.33 <sup>a</sup>
IKP 111-TM	675.99±10.53	100.33±21.70	6.74 <sup>a</sup>
IKP 333-TM	1036.78±29.30	109.77±19.98	9.45 <sup>b</sup>

<sup>a,b</sup> different superscript show statistically significant difference at p ≤ 0.05.

## RESULTS

### *Probiotics improve intestinal histomorphological measurement of broiler*

Mean villus height, crypt depth and villus height/crypt depth ratio of duodenum, jejunum and ileum of different groups are presented in Tables I, II and III, respectively. Representative intestinal histomorphology (duodenum) of different groups is shown in Figure 1. Villus height/crypt depth ratio of negative and positive control group were non-significantly different (P<0.05) in duodenum

(6.58 vs 6.14), jejunum (6.52 vs 6.38) and ileum (5.28 vs 6.06), respectively. Villus height/crypt depth ratio in broiler groups (IKP 23-PM, IKP 111-PM, IKP 333-PM) administered with probiotic before challenge was significantly increased in duodenum (8.03, 8.1, and 8.07, respectively), jejunum (11.88, 9.53, and 8.25, respectively) and ileum (7.59, 8.53, 8.25, respectively) as compared with positive control group. Results also revealed that broiler groups (IKP 23-TM, IKP 111-TM, IKP 333-TM) administered with probiotic post challenge showed non-significant treatment increase in villus height/crypt depth ratio in duodenum. IKP111 and IKP333 significantly increased villus height/crypt depth ratio in jejunum and ileum in respective groups of broilers.

**Table III.- Effects of probiotic on gut (ileum) morphology in broiler chickens.**

Groups	Villus height (um) (Mean± S.D)	Crypt depth (um) (Mean± S.D)	Villus height/ Crypt depth ratio
Negative control	632.30±65.90	119.77±8.88	5.28 <sup>a</sup>
Positive control	666.67±20.81	110.00±5	6.06 <sup>a</sup>
IKP 23-PM	762.47±27.06	100.43±20.70	7.59 <sup>b</sup>
IKP 111-PM	864.67±25.60	101.40±4.54	8.53 <sup>c</sup>
IKP 333-PM	761.63±73.55	92.23±17.03	8.26 <sup>c</sup>
Protexin-PM	710.47±37.21	102.29±3.93	6.94 <sup>b</sup>
Antibiotic-PM	417.91±35.67	78.67±13.86	5.31 <sup>a</sup>
IKP 23-TM	771.33±47.58	93.93±6.12	8.21 <sup>c</sup>
IKP 111-TM	664.13±48.24	95.08±9.06	6.99 <sup>b</sup>
IKP 333-TM	611.12±57.41	87.08±27.90	7.02 <sup>b</sup>

<sup>a,b,c</sup> different superscript show statistically significant difference at p ≤ 0.05.

**Table IV.- D-xylose concentration in plasma of broiler chicken at 0, 30 and 60 min on day 35 of age.**

Groups	D-Xylose concentration (Mean±SD, mg/dl) in plasma of broiler in different groups		
	0 min	30 min	60 min
Negative control	0	14.11±2.31 <sup>a</sup>	22.09±2.38 <sup>a</sup>
Positive control	0	13.51±1.89 <sup>a</sup>	22.30±1.95 <sup>a</sup>
IKP 23-PM	0	30±5.21 <sup>b</sup>	58.06±7.23 <sup>b</sup>
IKP 111-PM	0	26.92±4.32 <sup>b</sup>	52.75±5.64 <sup>b</sup>
IKP 333-PM	0	24.16±3.74 <sup>b</sup>	53.09±4.89 <sup>b</sup>
Protexin-PM	0	25.05±3.23 <sup>b</sup>	50.97±5.41 <sup>b</sup>
Antibiotic-PM	0	16.01±2.73 <sup>a</sup>	22.10±3.54 <sup>a</sup>
KP 23-TM	0	20.03±3.12 <sup>a</sup>	48.81±4.26 <sup>b</sup>
IKP 111-TM	0	22.80±2.56 <sup>a</sup>	46.71±8.23 <sup>b</sup>
IKP 333-TM	0	22.41±2.43 <sup>a</sup>	48.02±5.69 <sup>b</sup>

<sup>a,b</sup> different superscript in different rows of same column show statistically significant difference at p ≤ 0.05.

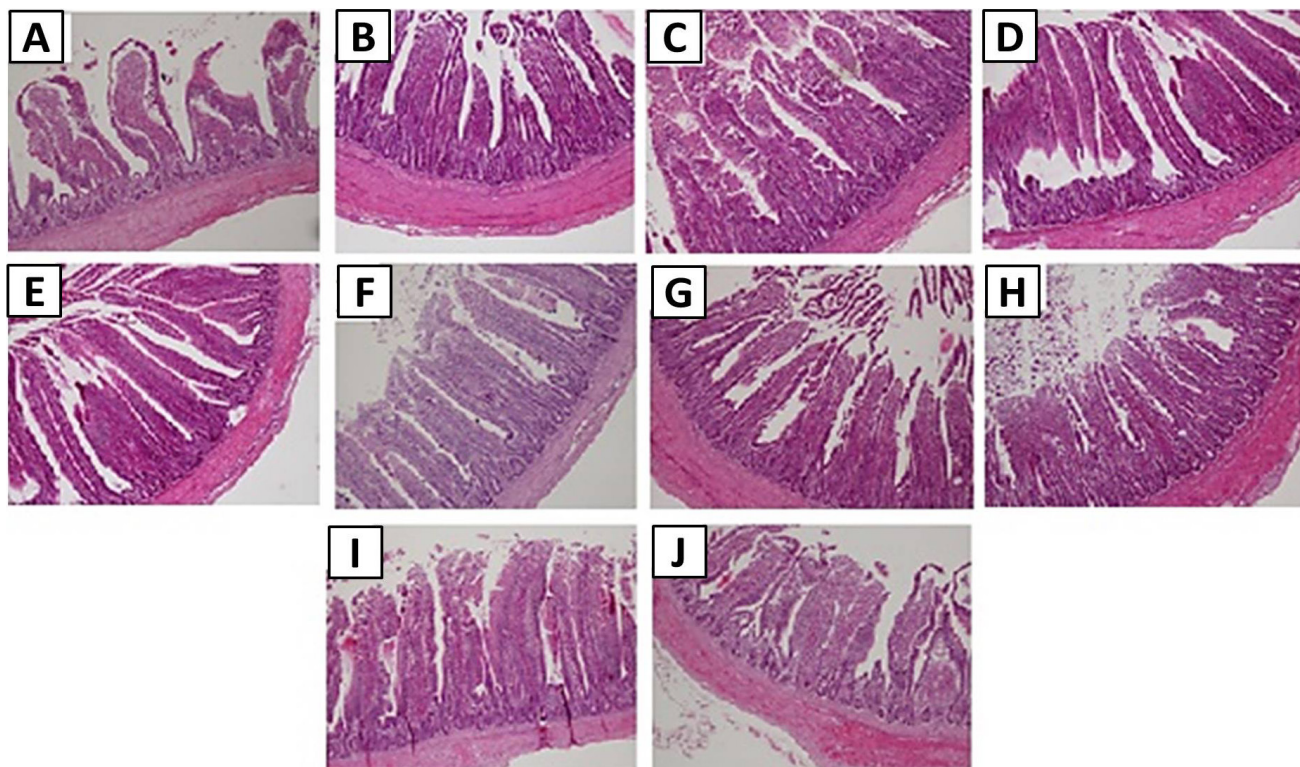


Fig. 1. Effects of probiotics on gut (duodenum) morphology of broiler challenged with *Salmonella enteritidis*. A, positive control; B, negative control; C, probiotic 23 (treatment); D, probiotic IKP111 Probiotic (treatment); E, probiotic 333 (treatment); F, probiotic 23 (preventive); G, probiotic (preventive) IKP 23; H, probiotic 333 (preventive); I, protexin; J, antibiotic.

#### *Probiotics enhance D-xylose absorption from intestine*

Results of D-xylose absorption capacity of broiler is given in Table IV. There was no significant difference ( $P < 0.05$ ) in the D-xylose absorption capacity of negative control group and positive control group. D-xylose concentration in plasma of negative control group and positive control group was 22.09 mg/dl vs 22.30 mg/dl, respectively at 60 min post administration. Results revealed that plasma D-xylose concentration in broiler groups administered with probiotics pre-challenge ( $58.06 \pm 7.23$ ,  $52.75 \pm 5.64$  and  $53.09 \pm 4.89$  mg/dl, respectively) or post challenge of *Salmonella* ( $48.81 \pm 4.26$ ,  $46.71 \pm 8.23$  and  $48.02 \pm 5.69$  mg/dl, respectively) was significantly higher ( $P < 0.05$ ) compared to negative control ( $22.09 \pm 2.38$  mg/dl), positive control ( $22.30 \pm 1.95$  mg/dl) and antibiotic group ( $22.10 \pm 3.54$ ). Commercial probiotic product protexin also significantly increased the D-xylose absorption ( $50.97 \pm 5.41$  mg/dl) from intestine as compared to positive and negative control group.

## DISCUSSION

Intestinal morphology including duodenal, ileal and

jejunum villus height and villus height crypt depth ratio are indicative of gut health. Increased villus height and villus height to crypt depth ratio are directly associated with an improved epithelial turn over (Fan *et al.*, 1997; Liu *et al.*, 2009) and longer villi are interrelated with stimulation of cell mitosis (Samanya and Yamauchi, 2002), while shortening of villi and reduced crypt depth ratio is indicative of poor nutrient absorption, increased secretions of gastrointestinal tract and reduced gut performance (Xu *et al.*, 2003). In the present study, supplementation of *L. fermentum* IKP 23, *L. fermentum* IKP 111 and *L. salivarius* IKP 333 in drinking water of broiler resulted in increased villus height and villus height to crypt depth ratio in duodenum, jejunum and ileum at day 35. Result obtained in the present study are consistent with previous study reported increased villus height and villus height to crypt depth ratio in duodenum, jejunum and ileum of broiler supplemented with probiotics (*Lactobacillus*). Similar study reported that supplementation of *Lactobacillus* in broiler increased villus height and villus height to crypt depth ratio in duodenum (Awad *et al.*, 2010; Ashraf *et al.*, 2013; Song *et al.*, 2014). *Lactobacillus* treatment caused similar changes in intestinal morphology of broiler



(Awad *et al.*, 2009; Thanh *et al.*, 2009; Salim *et al.*, 2013). Scientific data shows that probiotics have positive effect on physiological function in small intestine. Probiotics involved in crypt cells proliferation of small intestine increased with the probiotics as compared to control (Ahmad, 2006; Awad *et al.*, 2009; Sohail *et al.*, 2012). In past, researcher claimed that villus height and crypt depth ratio increased in broiler with probiotics supplementation (Awad *et al.*, 2009; Al-Fataftah and Abdelqader, 2014; Song *et al.*, 2014) and prebiotics supplementation (Chand *et al.*, 2018). Result obtained here in provides information that *L. fermentum* (IKP 23), *L. fermentum* (IKP 111) and *L. salivarius* (IKP 333) have potential of improving gastrointestinal morphology in broiler chicken as growth promotor. Present study also reported that the use of probiotics helped in an increase in villus height and crypt depth ratio in small intestine (duodenum, jejunum and ileum). Villus height and crypt depth ratio of duodenum, jejunum and ileum was measured in all experimental groups. In duodenum the highest villus height and crypt depth ratio (8.10) was observed in IKP 111 supplemented (day 01 to 35) group and lowest ratio (6.09) was in antibiotic supplemented group. Significant difference ( $p < 0.05$ ) was observed in villus height and crypt depth ratio in probiotics group (IKP 23, IKP111 and IKP 333 supplemented at day 01 to 35) and other experimental groups. In jejunum the highest villus height and crypt depth ratio (11.88) was measured in IKP 23 supplemented (day 01 to 35) group and lowest ratio (6.04) was measured in antibiotic supplemented. In ileum the highest villus height crypt depth ratio (8.53) was measured in IKP111 supplemented (day 01 to 35) group while lowest (5.28) in negative control group. It was evident, that IKP 23, IKP111 and IKP 333 probiotics supplemented groups had higher villus height and crypt depth ratio in all experimental groups.

D-xylose absorption test is very effective test to assess the intestinal absorption capacity of broiler (Mansoori *et al.*, 2012). Moreover, D-xylose absorption test has been proven a reliable display of intestinal absorptive function in poultry (Doerfler *et al.*, 2000). D-xylose absorption test is a sensitive tool used for the evaluation of intestinal absorption capacity of chicken and birds with different nutritional demands showed different result of D-xylose absorption capacity (Mansoori *et al.*, 2012). D-xylose absorption is a good serum selected parameter for broiler chicken (Shomali *et al.*, 2012). The intestine of broiler absorb D-xylose practically completely, thus any change in plasma concentration of D-xylose in early hours after consumption is sign of absorption capacity of intestinal tract (Schutte *et al.*, 1991; Doerfler *et al.*, 2000). In present study, it was reported that differences exist in absorption

function of small intestine for D-xylose in different groups of broilers which were supplemented with probiotics and without probiotics. D-xylose test was used to assess the small intestine absorption capacity of broiler groups administered with probiotics and broiler group without supplementation of probiotics in present study. Dietary supplementation of probiotics in broiler resulted in an increase in villus height and surface area of villi in small intestine (Awad *et al.*, 2009). D-xylose is well absorbed from the small intestine as D-glucose in birds (Doerfler *et al.*, 2000). In past, Mansoori (2010) claimed that reduced growth rate in chicken are linked with low D-xylose absorption capacity in small intestine. Groups had better D-xylose absorption capacities which were supplemented with probiotics at day 1 to 35 as compared to those groups in which probiotics were supplemented at day 7 to 35. The highest concentration of D-xylose 58.06 mg was measured in plasma of broiler group supplemented with IKP 23 at day 1 to 35 in all experimental groups. The lowest concentration 22.10 mg of D-xylose was measured in plasma of group supplemented with antibiotics. There was significant difference ( $p < 0.05$ ) in D-xylose concentration in plasma of probiotics supplemented groups both in preventive and treatment model in comparison with negative control group, positive group and antibiotic supplemented group.

## CONCLUSION

It is concluded that potentially probiotic *L. fermentum* IKP 23, *L. fermentum* IKP 111 and *L. salivarius* IKP 333 may have improve gut morphology and enhance nutrient absorption in broiler gut. It also insinuate for formulation and development of probiotic poultry product containing these strains.

## ACKNOWLEDGMENTS

This project was partially supported by Higher Education Commission/NRPU Project No. 7069/Punjab/NRPU/R&D/HEC/2017.

### Statement of conflict of interest

We declare that there is no conflict of interest

## REFERENCES

- Afsharmanesh, M. and Sadaghi, B., 2014. Effects of dietary alternatives (probiotic, green tea powder, and Kombucha tea) as antimicrobial growth promoters on growth, ileal nutrient digestibility, blood parameters, and immune response of broiler

- chickens. *Comp. clin. Pathol.*, **23**: 717-724. <https://doi.org/10.1007/s00580-013-1676-x>
- Ahmad, I., 2006. Effect of probiotics on broilers performance. *Int. J. Poult. Sci.*, **5**: 593-597. <https://doi.org/10.3923/ijps.2006.593.597>
- Al-Fataftah, A.R. and Abdelqader, A., 2014. Effects of dietary *Bacillus subtilis* on heat-stressed broilers performance, intestinal morphology and microflora composition. *Anim. Feed Sci. Technol.*, **198**: 279-285. <https://doi.org/10.1016/j.anifeedsci.2014.10.012>
- Ali, S., Masood, S., Zaneb, H., Masood, H.R.S., Khan, M. and Tahir, S., 2017. Supplementation of zinc oxide nanoparticles has beneficial effects on intestinal morphology in broiler chicken. *Pak. Vet. J.*, **37**: 335-339.
- Ansari, F., Pourjafar, H., Bokaie, S., Peighambari, S., Mahmoudi, M., Fallah, M. and Shabani, M., 2017. Association between poultry density and *Salmonella* infection in commercial laying flocks in Iran using a kernel density. *Pak. Vet. J.*, **37**: 299-304.
- Apata, D., 2012. The emergence of antibiotics resistance and utilization of probiotics for poultry production. *Sci. J. Microbiol.*, **2012**: 8-12.
- Applegate, T., Klose, V., Steiner, T., Ganner, A. and Schatzmayr, G., 2010. Probiotics and phytogenics for poultry: Myth or reality? *J. appl. Poult. Res.*, **19**: 194-210. <https://doi.org/10.3382/japr.2010-00168>
- Arif, A., Nawaz, M., Rabbani, M., Iqbal, S., Mustafa, A. and Yousuf, M., 2018. Screening, characterization and physicochemical optimization of phosphorus solubilization activity of potential probiotic *Lactobacillus* spp. *Pak. Vet. J.*, **38**: 316-320.
- Asghar, S., Arif, M., Nawaz, M., Muhammad, K., Ali, M. A., Ahmad, M. D., Iqbal, S., Anjum, A. A., Khan, M. and Nazir, J., 2016. Selection, characterisation and evaluation of potential probiotic *Lactobacillus* spp. isolated from poultry droppings. *Benef. Microbes*, **7**: 35-44. <https://doi.org/10.3920/BM2015.0020>
- Awad, W., Ghareeb, K., Abdel-Raheem, S. and Böhm, J., 2009. Effects of dietary inclusion of probiotic and synbiotic on growth performance, organ weights, and intestinal histomorphology of broiler chickens. *Poult. sci.*, **88**: 49-56. <https://doi.org/10.3382/ps.2008-00244>
- Azeem, N., Nawaz, M., Anjum, A.A., Saeed, S., Sana, S., Mustafa, A. and Yousuf, M.R., 2019. Activity and anti-aflatoxigenic effect of indigenously characterized probiotic lactobacilli against *Aspergillus flavus*: A common poultry feed contaminant. *Animals (Basel)*, **9**: 166. <https://doi.org/10.3390/ani9040166>
- Chand, N., Khan, R.U., Mobashar, M., Naz, S., Rowghani, E. and Khan, M.A. 2019. Mannanoligosaccharide (MOS) in Broiler ration during the starter phase: 1. Growth performance and intestinal histomorphology. *Pakistan J. Zool.*, **51**: 173-176. <http://dx.doi.org/10.17582/journal.pjz/2019.51.1.173.176>
- Doerfler, R., Cain, L., Edens, F., Parkhurst, C., Qureshi, M. and Havenstein, G., 2000. D-Xylose absorption as a measurement of malabsorption in poult enteritis and mortality syndrome. *Poult. Sci.*, **79**: 656-660. <https://doi.org/10.1093/ps/79.5.656>
- Fan, Y., Croom, J., Christensen, V., Black, B., Bird, A., Daniel, L., McBride, B. and Eisen, E., 1997. Jejunal glucose uptake and oxygen consumption in turkey poults selected for rapid growth. *Poult. Sci.*, **76**: 1738-1745. <https://doi.org/10.1093/ps/76.12.1738>
- FAO-WHO, 2001. *Report on Joint FAO/WHO Expert Consultation on evaluation of health and nutritional properties of probiotics in food including powder milk with live lactic acid bacteria*. Food and Agriculture Organization, World Health Organization. Available online: <ftp://ftp.fao.org/docrep/fao/meeting/009/y6398e.pdf>
- Kim, J., Ingale, S., Kim, Y., Kim, K., Sen, S., Ryu, M., Lohakare, J., Kwon, I. and Chae, B., 2012. Effect of supplementation of multi-microbe probiotic product on growth performance, apparent digestibility, cecal microbiota and small intestinal morphology of broilers. *J. Anim. Physiol. Anim. Nutr.*, **96**: 618-626. <https://doi.org/10.1111/j.1439-0396.2011.01187.x>
- Liu, F., Yin, J., Du, M., Yan, P., Xu, J., Zhu, X. and Yu, J., 2009. Heat-stress-induced damage to porcine small intestinal epithelium associated with downregulation of epithelial growth factor signaling. *J. Anim. Sci.*, **87**: 1941-1949. <https://doi.org/10.2527/jas.2008-1624>
- Mansoori, B., 2010. D-Xylose absorption capacity of broiler intestine in response to phytic acid. *Br. Poult. Sci.*, **51**: 158-161. <https://doi.org/10.1080/00071660903578602>
- Mansoori, B., Nodeh, H. and Modirsanei, M., 2012. Differences in intestinal absorptive capacity of chickens for D-xylose. *Iran. J. Vet. Med.*, **6**: 273-285.
- Mountzouris, K., Tsirtsikos, P., Kalamara, E., Nitsch, S., Schatzmayr, G. and Fegeros, K., 2007. Evaluation of the efficacy of a probiotic containing *Lactobacillus*, *Bifidobacterium*, *Enterococcus*,

- and *Pediococcus* strains in promoting broiler performance and modulating cecal microflora composition and metabolic activities. *Poult. Sci.*, **86**: 309-317. <https://doi.org/10.1093/ps/86.2.309>
- Olnood, C.G., Beski, S.S., Choct, M. and Iji, P.A., 2015. Novel probiotics: Their effects on growth performance, gut development, microbial community and activity of broiler chickens. *Anim. Nutr.*, **1**: 184-191. <https://doi.org/10.1016/j.aninu.2015.07.003>
- Park, Y.H., Hamidon, F., Rajangan, C., Soh, K.P., Gan, C.Y., Lim, T.S., Abdullah, W.N. and Liong, M.T., 2016. Application of probiotics for the production of safe and high-quality poultry meat. *Korean J. Fd. Sci. Anim. Resour.*, **36**: 567-576. <https://doi.org/10.5851/kosfa.2016.36.5.567>
- Patterson, J.A. and Burkholder, K.M., 2003. Application of prebiotics and probiotics in poultry production. *Poult. Sci.*, **82**: 627-631. <https://doi.org/10.1093/ps/82.4.627>
- Regassa, A., Kiarie, E., Sands, J., Walsh, M., Kim, W. and Nyachoti, C., 2016. Nutritional and metabolic implications of replacing cornstarch with D-xylose in broiler chickens fed corn and soybean meal-based diet. *Poult. Sci.*, **96**: 388-396. <https://doi.org/10.3382/ps/pew235>
- Saleem, N., Nawaz, M., Ghafoor, A., Javed, A., Mustafa, A., Yousuf, M. and Khan, I., 2018. Phenotypic and molecular analysis of antibiotic resistance in lactobacilli of poultry origin from Lahore, Pakistan. *Pak. Vet. J.*, **38**: 409-413.
- Salim, H., Kang, H., Akter, N., Kim, D., Kim, J., Kim, M., Na, J., Jong, H., Choi, H. and Suh, O., 2013. Supplementation of direct-fed microbials as an alternative to antibiotic on growth performance, immune response, cecal microbial population, and ileal morphology of broiler chickens. *Poult. Sci.*, **92**: 2084-2090. <https://doi.org/10.3382/ps.2012-02947>
- Samanya, M. and Yamauchi, K.E., 2002. Histological alterations of intestinal villi in chickens fed dried *Bacillus subtilis* var. natto. *Comp. Biochem. Physiol. A: Mol. Integr. Physiol.*, **133**: 95-104. [https://doi.org/10.1016/S1095-6433\(02\)00121-6](https://doi.org/10.1016/S1095-6433(02)00121-6)
- Schutte, J., Van Leeuwen, P. and Lichtendonk, W., 1991. Ileal digestibility and urinary excretion of D-xylose and L-arabinose in ileostomized adult roosters. *Poult. Sci.*, **70**: 884-891. <https://doi.org/10.3382/ps.0700884>
- Shomali, T., Mosleh, N. and Nazifi, S., 2012. Two weeks of dietary supplementation with green tea powder does not affect performance, D-xylose absorption, and selected serum parameters in broiler chickens. *Comp. Clin. Pathol.*, **21**: 1023-1027. <https://doi.org/10.1007/s00580-011-1220-9>
- Siddique, A., Nawaz, Z., Zahoor, M., Rafique, A., Aslam, B., Nazia, N. and Hussain, R., 2018. Efficacy of lytic bacteriophages against multidrug resistant *Salmonella enteritidis* from milk and meat. *Pak. Vet. J.*, **38**: 352-358.
- Sohail, M., Hume, M., Byrd, J., Nisbet, D., Ijaz, A., Sohail, A., Shabbir, M. and Rehman, H., 2012. Effect of supplementation of prebiotic mannan-oligosaccharides and probiotic mixture on growth performance of broilers subjected to chronic heat stress. *Poult. Sci.*, **91**: 2235-2240. <https://doi.org/10.3382/ps.2012-02182>
- Song, J., Xiao, K., Ke, Y., Jiao, L., Hu, C., Diao, Q., Shi, B. and Zou, X., 2014. Effect of a probiotic mixture on intestinal microflora, morphology, and barrier integrity of broilers subjected to heat stress. *Poult. Sci.*, **93**: 581-588. <https://doi.org/10.3382/ps.2013-03455>
- Thanh, N., Loh, T., Foo, H., Hair-Bejo, M. and Azhar, B., 2009. Effects of feeding metabolite combinations produced by *Lactobacillus plantarum* on growth performance, faecal microbial population, small intestine villus height and faecal volatile fatty acids in broilers. *Br. Poult. Sci.*, **50**: 298-306. <https://doi.org/10.1080/00071660902873947>
- Xu, Z., Hu, C., Xia, M., Zhan, X. and Wang, M., 2003. Effects of dietary fructooligosaccharide on digestive enzyme activities, intestinal microflora and morphology of male broilers. *Poult. Sci.*, **82**: 1030-1036. <https://doi.org/10.1093/ps/82.6.1030>
- Zoghi, A., Khosravi-Darani, K. and Sohrabvandi, S., 2014. Surface binding of toxins and heavy metals by probiotics. *Mini-Rev. Med. Chem.*, **14**: 84-98. <https://doi.org/10.2174/1389557513666131211105554>