

Research Article

Histochemical Assessment of AgNORs in Cutaneous Neoplasms of Dogs

Munuswamy Palanivelu,^{1*} Avinash Warundeo Lakkawar², Khub Chandh Varshney³, Raja Kumar⁴, Mariappan Asok Kumar⁵

^{1, 5} Division of Pathology, Indian Veterinary Research Institute, Izatnagar -243 122, ^{2, 3, 4} Department of Veterinary Pathology, Rajiv Gandhi College of Veterinary and Animal Sciences, Puducherry

*Corresponding author: drpalvet@gmail.com

ARTICLE HISTORY

Received: 2013-07-25
Revised: 2013-07-27
Accepted: 2013-07-29

Key Words: AgNORs, benign, cutaneous, histochemical, malignant, neoplasms

ABSTRACT

Fifty canine cutaneous growths from various breeds of dogs were assessed for cell proliferation potential employing AgNORs (Argyrophilic Nucleolar Organizing Regions) staining. Out of 50 growths, 41 were confirmed as neoplasms based on histopathological examination, which included 24 benign and 17 malignant neoplasms of different tissue origin. Histochemical assessment of AgNORs among the 41 confirmed cases of neoplasms revealed a higher count in malignant tumours in comparison to benign tumours. Highest AgNORs count was recorded in fibrosarcoma (6.98) followed by basal cell carcinoma (5.91) and squamous cell carcinoma (5.57). The lowest count was recorded in hepatoid adenoma (2.31) followed by haemangioma (2.67). AgNOR counts of malignant tumours differed significantly ($p < 0.01$) from benign tumours. Benign tumours had AgNOR values ranging from 2.67 to 4.80 per nucleus, while the malignant tumours had 3.38 to 6.98 per nucleus. A few benign tumours, which showed tendency towards malignancy, expressed higher AgNORs counts. Assessment of AgNORs in this study found to be very useful to differentiate benign, malignant and borderline cases of cutaneous neoplasms.

All copyrights reserved to Nexus® academic publishers

ARTICLE CITATION: Palanivelu M, Lakkawar AW, Varshney KC, Kumar R, Kumar MA (2013). Histochemical assessment of AgNORs in cutaneous neoplasms of dogs. *Adv. Anim. Vet. Sci.* 1 (3): 93 – 95.

INTRODUCTION

Neoplasia is the most common disease-associated cause of death or euthanasia in dogs, contributing to nearly 16 to 24 percent of deaths in dogs. Neoplasms involving the skin and subcutaneous tissue occur frequently in dogs and cats, and are the most commonly diagnosed tumours in veterinary practice. Appropriate diagnosis and prompt prognosis are very important to select suitable line of treatment for any kind of neoplasia. Although, there are several diagnostic and prognostic markers available for most of the neoplastic disorders but their use is limited at field level, particularly, in veterinary practice. The assessment of cell proliferation markers is very helpful tool to ascertain malignancy status of any neoplasm. The proliferative activity is an important component of the metastatic potential of tumours or prognosis in cancer patients. One of the most widely used cell proliferation marker in veterinary practice is AgNORs (Argyrophilic Nucleolar Organizer Regions). The AgNORs are loops of DNA present on the short arms of acrocentric chromosomes that have been associated with protein synthesis and ribosomal activity. These regions has been successfully visualized in the later interphase period on metaphase spreads by colloidal silver staining technique in routinely processed histological and cytological preparations. The number of AgNORs is thought to reflect the proliferative activity of tumour cells (Kidogawa et al., 2005). The mean number of AgNORs per nucleus accurately correlates with mitotic rate in tumor cell lines and AgNOR counts may thus provide an indirect measurement of mitotic rate in surgical specimens that is free of the bias produced by post excisional handling of tissue. The stained complex corresponds ultrastructurally to the binding sites of RNA polymerase 1 and

associated proteins regulating transcription and posttranslational modification of ribosomal RNA (Johnson et al., 1995).

These argyrophilic nuclear organizer region proteins said to be accumulated in highly proliferating cells of tumours due to its segregation during transcription which could be demonstrated as black dots with silver staining on routine paraffin embedded sections and called as argyrophilic nucleolar organizer regions (AgNORs). The number of interphase AgNORs in continuously proliferating cells have been strictly related to the rapidity of cell proliferation (Trere, 2000). Measurement and enumeration of AgNORs have been useful in prognosticating the behavior of a variety of neoplasms of humans, particularly in instances where mitotic rate is a poor determinant of eventual recurrence of metastasis. AgNORs have been less useful in epithelial tumours, in which there is a relatively high mitotic rate in the cell type of origin as compared with sarcomas. However, AgNORs have recently been utilized to successfully forecast the probability of canine mammary tumor recurrence and metastasis and to predict the probability of recurrence. Staining of these structures might also be of use in locating the border between neoplastic and normal tissue at the margins of surgical specimens (Johnson et al., 1995).

MATERIALS AND METHODS

AgNOR staining

Formalin fixed paraffin embedded tissue sections were stained according to the protocol of the standardized AgNORs staining method (Jesijevic et al., 2003) with little modification. Paraffin embedded sections of 4-5 micron thickness were deparaffinized and hydrated in graded alcohol to water and

washed in ultrapure water for 5 minutes. Then the sections were pre-treated by pressure-cooking for 20 minutes in 10 mM citrate buffer with pH 6.0, then cooled to room temperature and washed in ultrapure water for 2 minutes. The pre-treated sections were stained with two parts of freshly prepared 33% silver nitrate solution mixed with one part of 2% gelatin in 1% formic acid for 30-45 minutes (depending on the staining intensity of each tissue block) at room temperature in the dark in a humidified chamber. The stained sections were rinsed thoroughly with ultrapure water, and fixed in 2% sodium thiosulfate solution for 5 minutes. Finally, the sections were washed in distilled water, dehydrated in graded ethanol, cleared in xylene and mounted with DPX.

Quantification of AgNORs

Quantification of AgNORs was performed with the Image-Pro PLUS 6.0 software (Media Cybernetics, USA). On each slide, 250 tumour cells were counted within the area most typical for the histopathological diagnosis. The average number of AgNOR dots per nuclei was calculated and used for analysis. The results were compared between different benign and malignant tumours to assess their proliferative activity and level of malignancy.

Image analysis

Image analysis was carried out on all AgNOR stained sections. All images were captured using a binocular Olympus BX41 microscope (Olympus Co., Japan) fitted with an Evolution LC digital camera. The digital images were analyzed using a semi-

automated image processing and analysis software, Image-Pro® PLUS 6.0 (Media Cybernetics, USA). The software performs automatic measurement of areas defined using an interactive threshold editing functions.

RESULTS

After silver staining, the AgNOR appeared as discrete dots of varying sizes, seen as single to multiple dots in centre or towards periphery of the nucleus. Majority of the benign tumour cells expressed AgNORs as smaller dots of almost uniform size (Fig.1.), while, the malignant tumour cells showed relatively large dots of varying sizes (Fig. 2.) under high power magnification. Highest AgNOR counts were recorded in fibrosarcoma (6.98) followed by basal cell carcinoma (5.91) and squamous cell carcinoma (5.57).

The lowest count was recorded in hepatoid adenoma (2.31) followed by haemangioma (2.67). AgNOR counts of malignant tumours differed significantly ($p < 0.01$) from benign tumours. Benign tumours had AgNOR values ranging from 2.67 to 4.80 per nucleus, while the malignant tumours had 3.38 to 6.98 per nucleus. Some of the benign tumours including a solitary case of papilloma and cutaneous histiocytoma, which showed tendency towards malignancy, expressed very high AgNOR counts. AgNOR staining could not be carried out for the cases of lipoma. The average AgNOR counts per cell of all the neoplasms recorded in this study are depicted table 1.

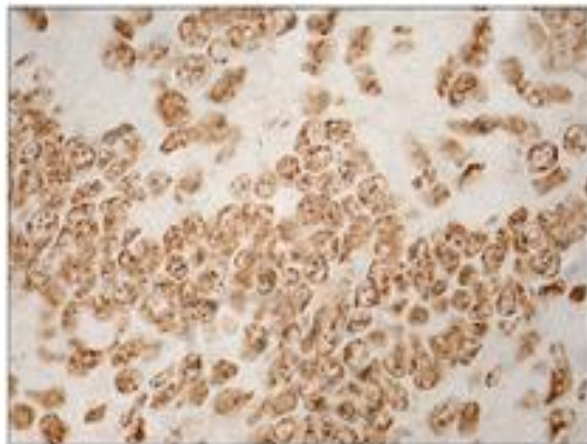


Figure 1: A benign neoplasm (papilloma) showing nucleolar organizer regions (AgNORs) as discrete, small black dots of uniform size inside the nuclei. Silver stain x1000.

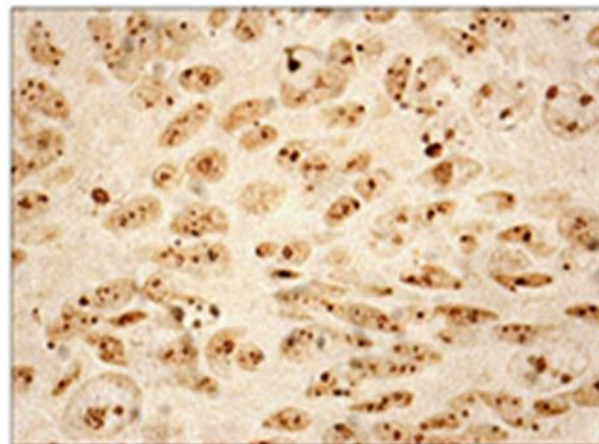


Figure 2: A malignant neoplasm (squamous cell carcinoma) showing nucleolar organizer regions (AgNORs) as discrete, larger black dots of variable size inside the nuclei. Silver stain x1000

Table 1: Average AgNOR counts of different cutaneous tumours

Benign Tumours	AgNORs count	Malignant Tumours	AgNORs count
Fibroma	5.26	Fibrosarcoma	6.98
Cutaneous Histiocytoma	4.80	Basal cell carcinoma	5.91
Fibromyxoma	3.91	Squamous cell carcinoma	5.57
Mast cell tumour	3.24	Ceruminous papillary cystadenocarcinoma	5.07
Sebaceous adenoma	3.22	Sebaceous adenocarcinoma	4.98
Melanoma	3.12	Apocrine adenocarcinoma	4.90
Papilloma	2.88	Haemangiosarcoma	4.83
Cutaneous Plasmocytoma	2.84	Cutaneous lymphoma	4.38
Haemangioma	2.67	Malignant melanoma	3.98
Hepatoid adenoma	2.31	Transmissible Venereal Tumour	3.38

DISCUSSION

The AgNOR staining in the present study was found to be a very useful prognostic marker to assess the rapidity of cell proliferation. The expression of NORs was relatively higher in mesenchymal tumour in comparison to epithelial and melanocytic tumours. Among all the neoplasms recorded in this study, the tumours of fibroblast origin showed consistently higher AgNOR counts per cell. In the present study, AgNOR counts of malignant tumours were significantly higher than that of benign tumours, which was in accordance to the earlier report (Akhtar et al., 2005; Manjunatha et al., 2007; Gulia et al., 2011 and Karki et al., 2012). A higher AgNOR count in malignant tumours might be attributed to high concentration of interphase AgNOR proteins in the rapidly proliferating cells (Destexhe et al., 1995 and Bratulić, 1996). Although, the basal cell carcinoma is considered as a locally malignant tumour, but, it showed a relatively higher AgNOR count even exceeding the count of other malignant epithelial and melanocytic neoplasms. The AgNOR count for hepatoid adenoma was lowest in the present study when compared to all other neoplasms, which might be attributed to low proliferating potential of the involved cells in the initial stages. None of the lipoma cases has shown reactivity to silver staining which needs to be investigated further.

CONCLUSIONS

To conclude, the assessment of AgNORs in canine cutaneous neoplasms is an effective tool to correlate the rate of cell proliferation between benign and malignant neoplasms. Moreover, AgNORs staining along with routine histopathological examination would have significant diagnostic and prognostic value in tumour pathology.

ACKNOWLEDGEMENT

The authors express sincere gratitude and thanks to the Dean, Rajiv Gandhi College of Veterinary and Animal Sciences, Puducherry for providing necessary facilities to conduct the research.

REFERENCES

- Akhtar K, Mehdi G, Maheshwari V, Ali Siddiqui S and Sharma R (2005). Diagnostic and prognostic significance of AgNOR counts in radiotherapy treated squamous cell carcinoma of the cervix. *J. Obstet. Gynecol. India.* 2: 163-166.
- Bratulić M, Grabarević Z, Artuković B and Capak D (1996). Number of nucleoli and nucleolar organizer regions per nucleus and nucleolus - prognostic value in canine mammary tumours. *Vet. Pathol.* 33: 527-532.
- Destexhe E, Bicker E and Coignoul F (1995). Image analysis evaluation of ploidy, S-phase fraction and nuclear area in canine mammary tumours. *J. Comp. Pathol.* 113: 205-216.
- Gulia S P, Sitaramam E and Reddy K P (2011). The role of silver staining nucleolar organizer regions (AgNORs) in lesions of the oral cavity. *J. Clin. Diag. Res.* 5: 1011-1015.
- Jelesijevic T, Jovanovic M, Knezevic Milijana and Aleksic-Kovacevic Sanja (2003). Quantitative and qualitative Analysis of AgNOR in Benign and Malignant canine Mammary Gland Tumours. *Act. Vet.* 53: 353-360.
- Johnson GC, Miller MA and Ramos-Vara JA (1995). Comparison of argyrophilic nucleolar organizer regions (AgNORs) and mitotic index in distinguishing benign from malignant canine smooth muscle tumours and in separating inflammatory hyperplasia from neoplastic lesions of the urinary bladder mucosa. *J. Vet. Diagn. Invest.* 7: 127-136.
- Karki S, Jha A and Sayami G (2012). The role of argyrophilic nucleolar organizer region (AgNOR) study in cytological evaluation of fluids, especially for detection of malignancy. *Kathmandu Univ. Med. J.* 37: 44-47.
- Kidogawa H, Nanashima A, Yano H, Matsumoto M, Yasutake T and Nagayasu T (2005). Clinical significance of double staining of MIB-1 and AgNORs in primary breast carcinoma. *Ant. Can. Res.* 25: 3957-3962.
- Manjunatha GB, Ram Kumar, Pawaiya RVS and Ravindran R (2007). Canine dermal neoplasms: evaluation of tumour proliferative fraction. *Indian J. Vet. Pathol.* 31: 108-112.
- Treere D (2000). AgNOR staining and quantification. *Micron.* 31: 127-13.