

## Histopathological effects of Lead Nitrate on body tissues of Herring gull (*Larus argentatus*)

NOREEN RAZA<sup>1\*</sup>, TASNEEM A. SAQIB<sup>2</sup>, SYED NAEEMUL HASSAN NAQVI<sup>3</sup>, MUHAMMAD ZAHEER KHAN<sup>2</sup> & MAZHAR HIJAZI<sup>3</sup>

<sup>1</sup> Defense Authority, College for Women, Phase-VIII, Karachi, Pakistan

<sup>2</sup> Department of Zoology, Faculty of Science, University of Karachi, Karachi-75270, Pakistan

<sup>3</sup> Baqai Medical University, Karachi, Pakistan

---

### ARTICLE INFORMATION

Received: 16-11-2018

Received in revised form:  
07-04-2019

Accepted: 22-04-2019

---

### \*Corresponding Author:

Noreen Raza:  
[noreenrazakhan@yahoo.com](mailto:noreenrazakhan@yahoo.com)

### Short Communication

---

### ABSTRACT

The effects of Lead nitrate on liver, gizzard, and kidney of Herring gull (*Larus argentatus*) were studied. Significant changes were observed after high and low concentrations of Lead nitrate were injected to *Larus argentatus*. Paraffin sections showed major alterations at high and low concentration of Lead nitrate in liver, gizzard and kidney. High concentration of Lead nitrate induced, severe dystrophy along with hepatic necrosis; reduction in thickness of muscular layer of gizzard and marked alterations in loop of Henle of kidney. While, low concentration of Lead nitrate showed slight alteration in loop of Henle in kidney; disruption and thinning of epithelium of gizzard and mild disruption of hepatic cords in liver. No laceration was observed in the mentioned body tissues of *Larus argentatus* of control group.

**Keywords:** Lead Nitrate, Herring gull, Histopathological effects, Liver, Gizzard, Kidney

---

### INTRODUCTION

For the purpose of mining and smelting, human has been using Lead (Pb) for centuries. Therefore, Lead (Pb) is found everywhere in air, water, & soil. It is also found in urban & countryside environment (Eisler, 2000). Lead (Pb) mainly enters living organisms through breathing and intake of food. As a result of anthropogenic activities, majority of animals show higher accumulation of Lead (Pb) in their tissues (Franson & Deborah, 2011). Lead (Pb) is also a risky heavy metal with negative effects on birds in natural and laboratory environment (Hassanpour *et al.*, 2012).

High level of Lead (Pb) poisoning is found in those water fowls which swallow Lead (Pb) shot pellets during their feeding in their habitats. These pellets enter their gizzard and shell of pellet is dissolved through grinding process & chemical actions of digestive juices of the gizzard. As a result of this process, Lead (Pb) enters intestine of the bird. Most of Lead (Pb) compounds are absorbed by blood through walls of intestine and these compounds damage liver, kidney, feathers, bones and muscles of digestive tract. Due to damaging effect of Lead (Pb) compounds on gastro-intestinal tract's muscles, normal activity of these muscles decreases which dangerously harm the process of

digestion and assimilation of food. (Jordan & Bellrose 1951).

Abrasions have been observed in avian species due to Lead (Pb) poisoning (Vyas *et al.*, 2001; Carpenter *et al.*, 2003; Pattee *et al.*, 2006)

Majority of avian species show muscle wasting & loss of fat reserves due to Lead (Pb) poisoning. However, impactions of esophagus, swelling in gall bladder, discolored gizzard lining, lesions in heart muscles, wasting of internal organs, degeneration of brain & peripheral nerves; heart and gizzard muscles are also observed. Impactions of pro-ventriculus, swelling of mandibles, necrosis in heart muscles, & stains in liver were found due to Lead (Pb) toxicity in water fowls (Beyer *et al.*, 1998). In wildlife, Lead (Pb) exposure is an increasing conservation threat that is being widely investigated. However, for some areas of the world (e.g., South America), research on this subject is still scarce or only local information is available (Wiemeyer *et al.*, 2017). Lead (Pb) concentrations on breeding physiology in Arctic birds have also been studied (Provencher *et al.*, 2016).

The work that was reported earlier on marine birds in Pakistan was limited to the population studies and very little work regarding effects of heavy metals on birds is available. Raza

*et al.*, (2016) conducted a study on induced effects of cadmium on liver, gizzard and kidney of *Larus argentatus*. The present investigation was conducted to find out the effects of Lead (Pb) on the body tissues (liver, gizzard and kidney) of *Larus argentatus* that were collected from coastal area of Hawks bay, Karachi, Pakistan. It is anticipated that this research will provide the information about the consequences of metals poisoning on birds.

## MATERIALS AND METHODS

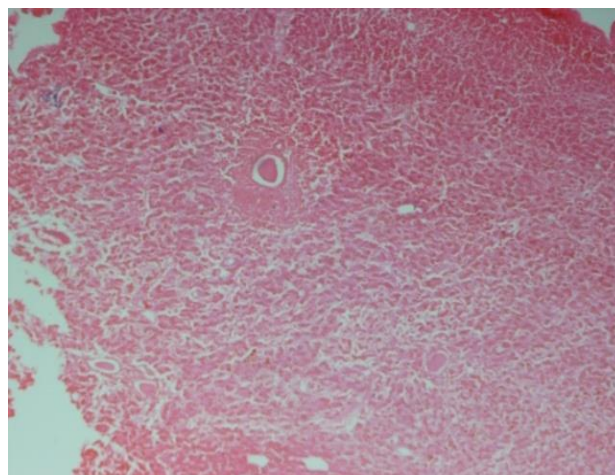
Alive herring gulls (*Larus argentatus*) were trapped with the help of local people from selected areas of Hawks bay, coast of Karachi, Pakistan. Collected herring gulls were kept in cages in the Lab, Department of Zoology, University of Karachi, Karachi. The gulls were given tap water and bread pieces as food. Nine herring gulls (*Larus argentatus*) were kept in cages in three groups i.e. Group A, B and C for 15 days before the treatment. Each group (A and B) had three birds for high and low concentrations of Lead Nitrate, respectively. Whereas, three birds were kept in group C as control. After 15 days, stock solution was prepared by dissolving 1 gram Lead Nitrate in 100 ml of distilled water. Then two dilutions were made of two concentrations i.e. 0.02 g Lead Nitrate /100 ml and 0.01 g Lead Nitrate / 100 ml distilled water.

To examine the effects of Lead Nitrate on body tissues of herring gulls, two concentrations i.e. 2 µg Lead Nitrate / 10 µl and 1 µg Lead Nitrate / 10 µl were injected subcutaneously in right leg of herring gulls. The effect of Lead Nitrate was established within eight hours as life span of all treated birds was not more than 8 hours. After the birds expired, all birds were sacrificed and dissection was done to get liver, kidney, and gizzard. All these organs were fixed in 10% Formalin. Histological study of all these organs was carried out by paraffin section method. For histopathological study, techniques of Bancroft and Stevens., (1990) were applied. Then photomicrographs were made by Olympus BX41 microscope with assessment of Olympus DP12 Camera.

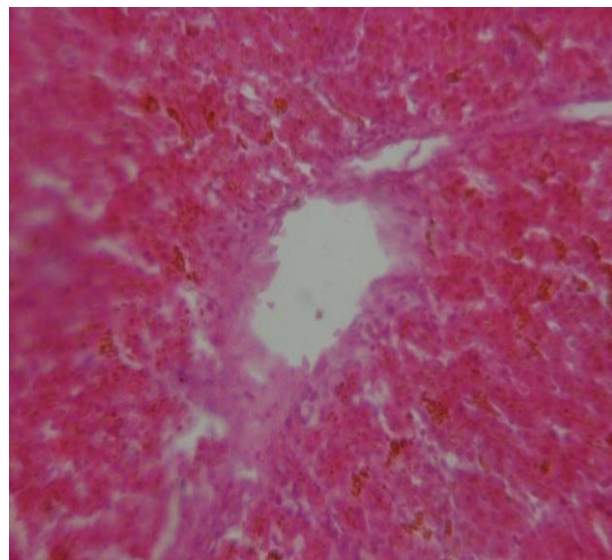
## RESULTS

As a result of high concentration of lead

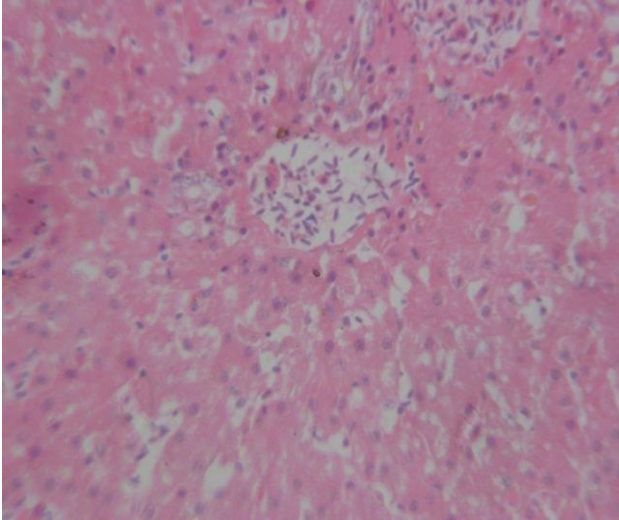
nitrate, severe dystrophy along with the hepatic necrosis was observed in Haematoxylin and Eosin (H&E) stained sections. The hepatocytes around the blood vessels were necrotized. In severely damaged areas, the hepatic cords were destroyed along with damaged cell membrane (Fig.1).The histopathological variations were also found as a result of low concentration of lead nitrate in the liver of *Larus argentatus*. The hepatic cells showed the changes in the arrangement of hepatic cords (Fig. 2). In control group of *Larus argentatus*, no significant changes were observed in liver (Fig.3).



**Fig. 1:** The Photomicrograph of liver of *Larus argentatus* showing effect of high dose of Lead nitrate. (X10)

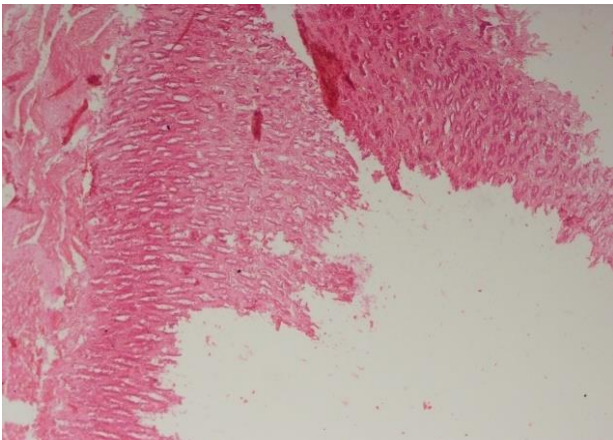


**Fig. 2:** The Photomicrograph of liver of *Larus argentatus* showing effect of low dose of Lead nitrate. (X40)

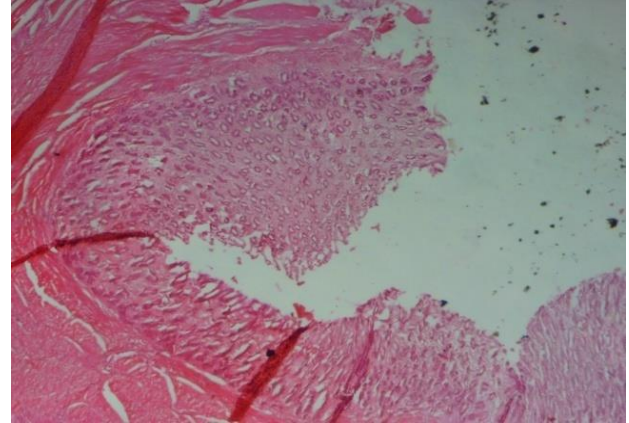


**Fig. 3:** The Photomicrograph of liver of a control group of *Larus argentatus*. (X400)

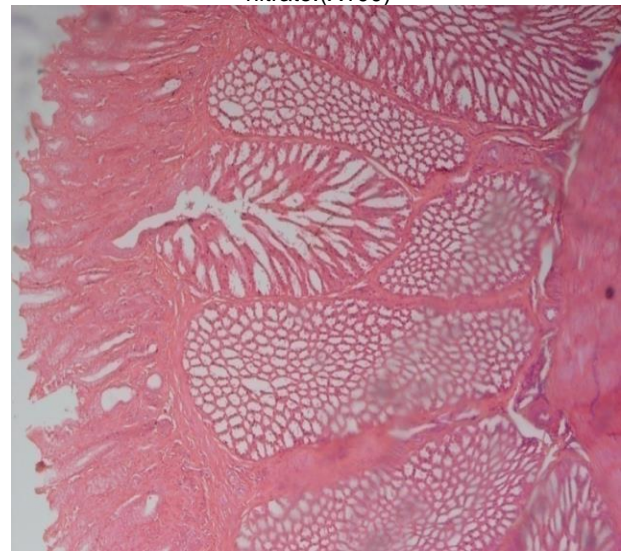
In the case of high concentration of lead nitrate, the histopathological study of the gizzard of *Larus argentatus* showed the disruption in the continuity of the lining cells with the reduction in thickness of the muscular layer of gizzard (Fig. 4). The effect of low concentration of lead nitrate on gizzard of *Larus argentatus* indicated the rigorous disruption of the lining epithelium of the gizzard with the thinness of the lining cells. The thickness of the epithelium was reduced as well as the muscular layer was also reduced (Fig. 5). However, controlled *Larus argentatus* gizzard exhibited normal morphology of mucosa and lining epithelium. The normal arrangement of different muscular layers was observed (Fig. 6).



**Fig. 4:** The Photomicrograph of gizzard of *Larus argentatus* showing effect of high dose of Lead nitrate. (X100)

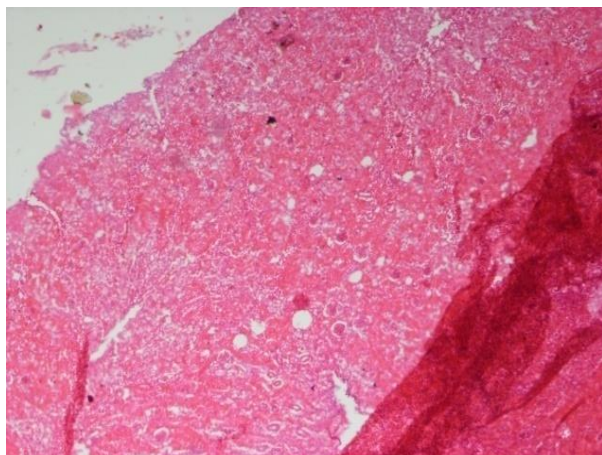


**Fig. 5:** The Photomicrograph of gizzard of *Larus argentatus* showing effect of low dose of Lead nitrate. (X100)

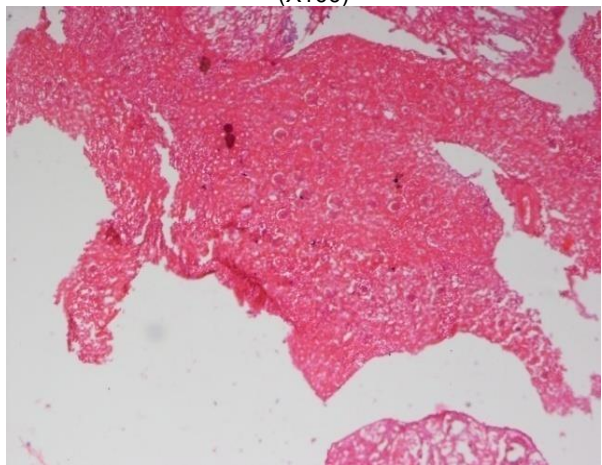


**Fig. 6:** The Photomicrograph of gizzard of control group of *Larus argentatus*. (X40)

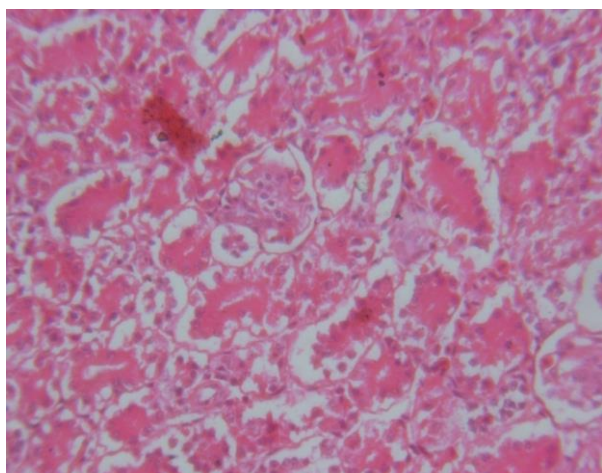
The effect of high concentration of Lead nitrate on kidney of the *Larus argentatus* showed marked changes in the loop of henle and reduction in the tubular cells around the glomeruli. The results also showed the appearance of the large number of vacuolated spaces in between the tubules (Fig. 7). The effect of low concentration of Lead nitrate showed slight alteration in the architecture of the tubules of the loop of henle in kidney of *Larus argentatus*. Scattered groups of proximal convoluted tubules with granular cytoplasm and with swollen granular cytoplasm were also found (Fig.8). Whereas, normal architecture in cells of kidney of *Larus argentatus* was observed (Fig. 9).



**Fig. 7:** The Photomicrograph of kidney of *Larus argentatus* showing effect of high dose of Lead nitrate. (X100)



**Fig. 8:** The Photomicrograph of kidney of *Larus argentatus* showing effect of low dose of Lead nitrate. (X100)



**Fig. 9:** The Photomicrograph of kidney of a control group of *Larus argentatus*. (X400)

## DISCUSSION

Heavy metals enter the body of animal through ingestion of contaminated food and water and produce lethal effects on different organs (Namroodi *et al.*, 2017). Lead (Pb) is one of the heavy metals that show a serious threat to wildlife and ecosystems (Pineau *et al.*, 2017). Lead (Pb) is poisonous metal and acts as non specific toxin. It affects systems of body in animals. That is why, absorption of little amount of Lead (Pb) causes sublethal effects. However, its elevated amount is responsible for mortality (Demayo *et al.*, 1982). Ingestion of Lead (Pb) shot pellets is the main cause of lead poisoning in avifauna. The effects of sublethal Lead (Pb) on immunity, sperm quality, reproductive success, egg properties, and laying performance were studied in red legged partridges (Vallverdu-Coll *et al.*, 2015, 2016).

About 700,000 individuals of 16 water bird species die annually in the European Union (EU) and one million across Europe as a direct effect of lead poisoning (Andreotti *et al.*, 2018)

Histopathological modifications such as transmission disorders, retrogressive alterations, swelling of leucocytes penetration in liver and kidney of mallards (*Anas platyrhynchos*) and coots (*Fulica atra*) were found as result of accumulation of Lead (Pb) (Binkowski *et al.*, 2013). Ultrastructure of liver was observed in mallards (*Anas platyrhynchos*) when they were given only Lead (Pb) shots (Pineau *et al.*, 2017). The results in treated mallards showed alterations in hepatic parenchyma. Histological changes in the liver of chickens treated with Lead Acetate II were observed (Ashrafizadeh *et al.*, 2018).

Histological alterations like Kupffer cell hemosideros, large bile plugs in canaculi and bile pigmentation in liver cells were observed due to Lead (Pb) poisoning in white fronted geese (*Anser albifrons*) (Ochiai *et al.*, 1993). Chronic exposure to subtoxic concentrations of Lead (Pb) showed changes in hepatocytes, portal vein congestion, kupffer cell hyperplasia and cytolysis in liver of the quail (*Coturnix coturnix*) (Al-Mansour *et al.*, 2009). Lead acetate toxicity was observed in broiler chickens in the form of paleness, fatty alterations & enlargement of liver (Shah *et al.*, 2016). Degeneration and necrosis were observed in liver parenchyma of chickens reared in an industrial area of West Bengal, India (Kar *et al.*, 2018). So, the consumption of this chicken meat from the industrially exposed site may cause a potential health threat to local residents of polluted sites. Gross lesions associated with lead toxicity were observed in heart, eyes, hemorrhagic necrosis in

brain, fibrinoid necrosis in arteries of Bald eagle (*Haliaeetus leucocephalus*) (Manning *et al.*, 2019).

In the present study, untreated herring gulls did not show any destructive changes in hepatic cords and cells around the blood vessels in liver of *Larus argentatus* (Fig. 3) but at high concentration (Fig.1) and low concentration of Lead Nitrate (Fig. 2), hepatic cords and cell membrane of liver cells were damaged and mild to moderate variations in hepatocytes around blood vessels were observed, respectively.

Lead (Pb) toxicity in confined birds was found. Pro-ventricular impaction was noted in some mallards (*Anas platyrhynchos*) (Beyer *et al.*, 1988). Effect of Lead (Pb) on whooper swans (*Cygnus Cygnus*) and Tundra swans (*Cygnus columbianus*) were investigated. Anorexia, glumness, green colored thin fecal material, light conjunctiva, and anemia was also reported (Nakade *et al.*, 2005). Behavior and growth of mallard ducklings were affected by Lead (Pb) contaminated sediments and nutrition (Douglas-Stroebel *et al.*, 2005). Different behaviors such as feeding, swimming, standing, pecking, preening, and dabbling are affecting as result of lead (Pb) poisoning in birds. Histological changes such as hemosiderosis, demyelination of sciatic and brachial nerves, and swelling of renal tubular epithelium were observed in Pb-exposed mallards (Mateo *et al.*, 2003). Lead (Pb) poisoning was also reported in confined and wild mallards (*Anas platyrhynchos*) in Spain (Rodríguez *et al.*, 2010). Degradation in gizzards in dosed birds was found and 34% of birds died during experimental stage and some birds which survived showed anorexia, tiredness and less reaction to exterior stimuli.

In the present study, the effect of high concentration of Lead nitrate on gizzard of *Larus argentatus* indicated the disruption in the continuity of the epithelial lining cells with the reduction in thickness of the muscular layer of gizzard (Fig. 4). In present work, the histopathological effects of low concentration of Lead nitrate showed the disruption of the lining epithelium of the gizzard and muscular layer was also reduced (Fig. 5). Normal morphology of the mucosa and the lining epithelium in gizzard of control group of *Larus argentatus* was found (Fig. 6).

Effects of 100 µg Pb/ml water on Ringed turtle doves have been determined (Kendall & Scanlon., 1981). Severe nephropathy, swelling of many cell nuclei, and reduction in mitochondria in proximal convoluted tubules were observed. Effects of Lead (Pb) were observed in captive avian

species. Intranuclear inclusion bodies were found in kidney. Necrosis in heart muscles and arteries was also noted (Beyer *et al.*, 1988).

Pathological effects of Lead (Pb) shot toxicity in mallard ducks were investigated (Clemens *et al.*, 1975). As a result, pro-ventricular epithelium was destroyed. Devastation occurred in osteocytes and pectoral muscles. Intraventricular inclusion bodies were also found in epithelium of proximal convoluted tubules of kidney. A study was conducted to observe effects of Lead (Pb) in Whooper swans (*Cygnus Cygnus*) in Japan (Ochiai *et al.*, 1992). Histopathologically, intranuclear inclusion bodies were found in kidney of swan. Lead (Pb) toxicity was also investigated in early embryogenesis of mallards and an adverse result of Lead (Pb) was also noted in hatching of ducklings (Kertesz & Fancsi., 2003). Oxidative stress, pathology and behavioral symptoms of Lead (Pb) were studied in mallards (Mateo *et al.*, 2003). For that, low and high doses of Vitamin-E (20 or 220 UI/KG) and Lead (Pb) (0 or 2g /Kg) were given to mallards. As a result, alveolar bleeding, destruction of myelin sheath of sciatica & brachial nerves, & swelling of epithelium of renal tubules occurred. Alterations in kidney of mallards (*Anas platyrhynchos*) including inflammation to infiltration were found (Binkowski *et al.*, 2013). Histological changes revealed necrotic lesions in the kidney of chickens reared in an industrial area of West Bengal, India. (Kar *et al.*, 2018).

In the present investigation, the effect of high concentration of Lead nitrate produced marked architectural changes of the tubules with alteration in the loop of henles and diminution in the tubular cells around the glomeruli in kidney of *Larus argentatus* (Fig. 7) However, the histopathological assessment as result of low concentration of Lead nitrate showed slight alteration in the structural design of the tubules of the loop of Henle in kidney of *Larus argentatus* (Fig. 8). In control group of *Larus argentatus*, the architecture shows to be normal in cells of kidney (Fig. 9).

## REFERENCES

- Al-Mansour, M. I., Al-Otaibi, N. M., Alarifi, S. S., Ibrahim, S. A. & Jarrar, B. M., 2009. Histological and histochemical alterations induced by lead in the liver of the quail (*Coturnix coturnix*). *Toxicol. Environ. chem.*, 91(6):1191-1203.

- Andreotti, A., Fabbri, I., Menotta, S., Borghesi, F. & Menotta, S., 2018. Lead gunshot ingestion by a Peregrine Falcon. (*Ardeola*). *Int. J. Ornithol.*, 65: 53–58.
- Ashrafizadeh, M., Rafiei, H. & Ahmadi, Z., 2018. Histological Changes in the Liver and biochemical Parameters of Chickens treated with Lead Acetate II. *Iranian J. Toxicol.*, 12(6): 1-5.
- Bancroft, J. D. & Stevens. A., 1990. *Theory and Practice of histological techniques*. 3rd Ed. Edinburgh: Churchill Livingstone.
- Beyer, W. N., Franson, J. C., Locke, L. N., Stroud, R. K. & Sileo, L., 1998. Retrospective study of the diagnostic criteria in a lead-poisoning survey of waterfowl. *Arch. Environ. Contam. Toxicol.*, 35(3):506-512.
- Beyer, W. N., Spann, J. W., Sileo, L. & Franson, J. C., 1988. Lead poisoning in six captive avian species. *Arch. Environ. Contam. Toxicol.*, 17(1):121-130.
- Binkowski, Ł. J., Sawicka-Kapusta, K., Szarek, J., Strzyżewska, E. & Felsmann, M., 2013. Histopathology of liver and kidney of wild living Mallards (*Anas platyrhynchos*) and Coots (*Fulica atra*) with considerably concentrations of lead and cadmium. *Sci. Total. Environ.* 450-451: 326-333.
- Carpenter, J. W., Pattee, O. H., Fritts, S. H., Rattner, B. A., Wiemeyer, S. N., Royle, J. A. & Smith, M. R., 2003., Experimental lead poisoning in turkey vultures (*Cathartes aura*). *J. Wildl. Dis.*, 39(1):96-104.
- Clemens, E. T., Krook, L., Aronson, A. L. & Stevens, C. E., 1975. Pathogenesis of lead shot poisoning in the mallard duck. *Cornell. Vet.*, 65(2):248-285.
- Demayo, A., Taylor, M. C., Taylor, K. W., Hodson, P. V. & Hammond, P. B., 1982. Toxic effects of lead and lead compounds on human health, aquatic life, wildlife plants, and livestock. *CRC Crit. Rev. Environ. Control.*, 12(4):257-305.
- Douglas-Stroebe, E. K., Brewer, G. L. & Hoffman, D. J., 2005. Effects of Lead-Contaminated Sediment and Nutrition on Mallard Duckling Behavior and Growth. *J. Toxicol. Environ. Health. A.*, 68(2): 113-128.
- Eisler, R., 2000. *Handbook chemical risk assessment*. Vol. 1, Metals. Boca Raton, FL: Lewis Publishers.
- Franson, J. C. & Deborah, J. P., 2011. Lead in birds. Published in *Environmental Contaminants in Biota: Interpreting Tissue Concentrations*. 2<sup>nd</sup> Ed. W. Nelson Beyer & James P. Meador (Boca Raton: CRC, 2011). pp, 563-572.
- Hassanpour, M., Pourkhabbaz, A. R. & Rajaei, G. H., 2012. Determine the toxicity of lead, chromium and iron in edible tissue of common coot from international wetland Gomishan. *J. Res. Livest. Poultry*. 1(1):25-33. [Persian]
- Jordan, J. S. & Bellrose, F. C., 1951. Lead poisoning in wild waterfowl. *Ill. Nat. Hist. Surv. Biol. Notes* No. 26.
- Kar, I., Mukhopadhyay, S. K., Patra, A. K. & Pradhan, S., 2018. Bioaccumulation of selected heavy metals and histopathological and hematobiochemical alterations in backyard chickens reared in an industrial area, India. *Environ. Sci. Pollut. Res.*, 25 (4):3905–3912.
- Kendall, R. J. & Scanlon, P. E., 1981. Chronic Lead ingestion and nephropathy in ringed turtle doves. *Poultry Sci.*, 60(9): 2028-2032.
- Kertes, V. & Fancsi, T., 2003. Adverse effects of (surface water pollutants) cadmium, chromium, and lead on the embryogenesis of the mallard. *Aqua. Toxicol.*, 65(4): 425-433.
- Manning, L. K., Wunschmann, A., Armien, A. G., Willette, M., MacAulay, K., Bender, J. B., Buchweitz, J. P. & Redig, P., 2019. Lead Intoxication in Free-Ranging Bald Eagles (*Haliaeetus leucocephalus*). *Vet. Pathol.*, 56(2):289-299.
- Mateo, R., Beyer, W. N., Spann, J. W., Hoffman, D. J. & Ramis, A., 2003., Relationship between oxidative stress, pathology, and behavioral sign of lead poisoning in mallards. *J. Toxicol. Environ. Health. A.*, 66(14): 1371-89.
- Nakade, T., Tomura, Y., Jin, K., Taniyama, H., Yamamoto, M., Kikkawa, A., Miyagi, K., Uchida, E., Asakawa, M., Mukai, T., Shirasawa, M. & Yamaguchi. M., 2005. Lead Poisoning in Whooper and Tundra Swans. *J. Wildl. Dis.*, 41(1):253–256.
- Namroodi, S., Farmani, M. & Rezaei, H., 2017. A survey on heavy metal bioaccumulation in tissues of wild and Rural Geese in Golestan Province, Iran. *J. Mazan. Univ. Med. Sci.*, 27(147): 409-414.
- Ochiai, K., Jin, K., Itakura, C., Goryo, M., Yamashita, K., Mizuno, N., Fujinaga, T. & Tsuzuki, T., 1992. Pathological Study of Lead Poisoning in Whooper Swans (*Cygnus cygnus*) in Japan. *Avian Dis.*, 36(2) : 313-323.
- Ochiai, K., Jin, K., Goryo, M., Tsuzuki, T. & Itakura, C., 1993. Pathomorphologic Findings of Lead Poisoning in White-fronted Geese

- (*Anser albifrons*). *Vet. Pathol.*, 30(6): 522-528.
- Pattee, O. H., Carpenter, J. W., Fritts, S. H., Rattner, B. A., Wiemeyer, S. N., Royle, J. A. & Smith, M. R., 2006. Lead poisoning in captive Andean condors (*Vultur gryphus*). *J. Wildl. Dis.*, 42(2):772-779.
- Pineau, A., Fauconneau, B., Plouzeau, E., Fernandez, B., Quellard, N., Levillain, P. & Guillard, O., 2017. Ultrastructural study of liver and lead tissue concentrations in young mallard ducks (*Anas platyrhynchos*) after ingestion of single lead shot. *J. Toxicol. Environ. Health A.*, 80(3): 188-195.
- Provencher, J. F., Forbes, M. R., Hennin, H. L., Love, O. P., Braune, B. M., Mallory, M. L. & Gilchrist, H. G., 2016. Implication of mercury and lead concentrations on breeding physiology and phenology in an Arctic bird. *Environ. Pollut.*, 218: 1014-1022.
- Raza, N., Saqib, T. A., Yasmeen, G., Naqvi, S. N. H. & Hijazi, M., 2016. Histopathological study on induced effects of cadmium on liver, gizzard and kidney of *Larus argentatus*. *J. Basics. App. Sci.*, 12:269-274.
- Rodríguez, J. J., Oliveira, P. A., Fidalgo, L. E., Ginja, M. M., Silvestre, A. M Ordoñez, C., Serantes, A. E., Gonzalo-Orden, J. M. & Orden, M. A., 2010. Lead toxicity in captive and wild mallards (*Anas platyrhynchos*) in Spain. *J. Wildl. Dis.*, 46(3):854-863.
- Shah, T. M., Patel, U. D., Nimavat, V. R., Fefar, D. T., Kalaria, V. A., Javia, B. B., Savsani, H. H. & Kotadiya, C. R., 2016. Toxicopathological studies on experimentally induced lead acetate toxicity in broiler chickens with protective effect of *Opuntia elatior* and *Withania somnifera*. *The Asian J. Animal Sci.*, 11(1): 33-39.
- Vallverdú-Coll, N., Ortiz-Santaliestra, M. E., Mougeot, F., Vidal, D. & Mateo, R., 2015. Sub lethal Pb exposure produces season-dependent effects on immune response, oxidative balance and investment in Carotenoid-based coloration in red-legged partridges. *Environ. Sci. Technol.*, 49(6):3839–3850
- Vallverdú-Coll, N., Mougeot, F., Ortiz-Santaliestra, M. E., Castano, C., Santiago-Moreno, J. & Mateo, R., 2016. Effects of Lead Exposure on Sperm Quality and Reproductive Success in an Avian Model. *Environ. Sci. Technol.*, 50(22):12484–12492.
- Vyas, N. B., Spann, J. W. & Heinz, G. H., 2001. Lead shot toxicity to passerines. *Environ. Pollut.*, 111(1):135-138.
- Wiemeyer, G. M., Perez, M. A., Bianchini, L. T., Sampietro, L., Bravo, G. F., Jacome, L., Astore, V. & Lambertucci S. A., 2017. Repeated conservation threats across the Americas: High levels of blood and bone lead in the Andean Condor widen the problem to a continental scale. *Environ. Pollut.*, 220 Part A: 672-679.