



# Retrospective Study of Clinical Manifestations and Multiple Treatment Outcomes in 57 Cats Diagnosed with Feline Chronic Gingivostomatitis

MOHAMMAD HUSSAIN HAIDARY<sup>1</sup>, ROZANALIZA RADZI<sup>1\*</sup>, MUHAMMAD WASEEM ASLAM<sup>1</sup>, SENG FONG LAU<sup>1</sup>, FARINA MUSTAFFA KAMAL<sup>2</sup>, AHMAD RASUL RADZALI<sup>1</sup>

<sup>1</sup>Department of Veterinary Clinical Studies, Faculty of Veterinary Medicine, Universiti Putra Malaysia, 43300 Serdang, Malaysia; <sup>2</sup>Department of Veterinary Pathology & Microbiology, Faculty of Veterinary Medicine, Universiti Putra Malaysia, 43300 Serdang, Malaysia.

**Abstract** | Feline chronic gingivostomatitis (FCGS) is a severe inflammatory oral disease of cats that is often refractory to treatment. The etiology is unknown but reported to incriminate bacterial, viruses, and immunologic factors. This retrospective study is aimed to describe the clinical manifestations and treatment outcomes in cats diagnosed with FCGS. Patient records with FCGS were retrieved from 2008-2018 at University Veterinary Hospital (UVH), Universiti Putra Malaysia (UPM). The diagnosis of FCGS was made based on oral examination with the inflammation at the caudal oral cavity and lateral to the palatoglossal folds. Descriptive statistics were derived from the retrospective data using simple percentages. Fifty-seven cats were analyzed up to the final treatment with known survival status. The majority affected cats age between 3-6 years old (24/57) and male (41/57). Most affected cats came from indoor multcats households. The two most common clinical signs were halitosis (42%) and anorexia (28%). Caudal stomatitis (100%) and gingivitis (93%) were the two most intraoral findings. Elevated total proteins (96.5%) and hyperglobulinaemia (96.5%) were remarkable findings in biochemistry results. Thrombocytopenia was prominent and found in 70.9% of cats. Treatment options were varied; 39% (22/57) of the cats showed no signs of FCGS with various medical combination treatments based on owner observation, while 33% (19/57) succumbed to death. Partial and full mouth dental extraction was applied in 16/57 (28%) cats and result exhibited 1.7% (n=1) death, 3.5% (n=2) partial remission, and 22.8% (n=13) full recovery. Intralesional triamcinolone injection was able to manage FCGS in the short term. Serratiopeptidase or papain alone was not effective in the management of the FCGS.

**Keywords** | Feline chronic gingivostomatitis, FCGS, Caudal stomatitis, Halitosis, Dental extraction

**Received** | October 06, 2021; **Accepted** | October 20, 2021; **Published** | January 10, 2022

**\*Correspondence** | Rozanaliza Radzi, Department of Veterinary Clinical Studies, Faculty of Veterinary Medicine, Universiti Putra Malaysia, 43300 Serdang, Malaysia; **Email:** rozanaliza@upm.edu.my

**Citation** | Haidary MH, Radzi R, Aslam MW, Lau SF, Kamal FM, Radzali AR (2022). Retrospective study of clinical manifestations and multiple treatment outcomes in 57 cats diagnosed with feline chronic gingivostomatitis. *J. Anim. Health Prod.* 10(1): 51-59.

**DOI** | <http://dx.doi.org/10.17582/journal.jahp/2022/10.1.51.59>

**ISSN** | 2308-2801

## INTRODUCTION

The feline chronic gingivostomatitis (FCGS) is a poorly understood disease condition, characterized by dysphagia, ptyalism, pain on manipulation of the mouth, pawing at the mouth, chronic debilitating condition, grooming

deficiency, and sometimes bleeding from the mouth (Healey et al., 2007; Bellei et al., 2008). FCGS occurs globally with a prevalence range of 0.7% to 12% (Winer et al., 2016). Clinically FCGS manifested as severe chronic inflammation of caudal, gingival, buccal, and labial, palatoglossal, and/ or other remaining part's mucosa of the oral cavity (Peralta and Carney, 2019). Factors such as innate

immune status of the cats, microbial agents like gram-negative anaerobic bacteria, Feline Calicivirus (FCV), and Feline Herpesvirus (FHV) studied in detail in the past but not concrete results on the etiology of FCGS (Harley et al., 1999; Harley, 2003; Kornya et al., 2014). Bacteria *Pasteurella multocida*, *Bartonella henselae*, *Bartonella clarridgeiae*, *Tannerella forsythia*, and dental plaque bacteria were reported to play a vital role in FCGS pathogenesis (Jameson et al., 1995; Southerden, 2010; Dolieslager et al., 2011; Dolieslager et al., 2013). A partial dental extraction (extraction of all premolar and molar teeth, leaving incisors and canine teeth) or full-mouth dental extraction provides the best long-term outcomes (Bellei et al., 2008; Jennings et al., 2015).

This study describes the clinical manifestations and treatment outcome of cats diagnosed with chronic gingivostomatitis presented to University Veterinary Hospital (UVH), Universiti Putra Malaysia (UPM).

## MATERIAL AND METHODS

This study involved 1160 cats diagnosed with FCGS presented to the UVH, UPM between 2008 and 2018 via a search from a practice management log. Only 57 cats met the inclusion criteria. Patient information was collected from patient medical records (PMR). The data recorded into excel spreadsheet were patient history/signalmen, clinical presentation, vaccination status, household management, hematology, and serum biochemistry data, feline leukemia virus (FeLV) antigen and feline immunodeficiency virus (FIV) antibody SNAP tests (SNAP Combo FeLV/FIV; Idexx Laboratories) results and complete treatment plan with/without dental extraction. Patient outcome and survival status data were obtained via phone call to the patient's owner.

### STATISTICAL ANALYSIS

Descriptive analysis was derived using IBM SPSS Statistics version 26 (IBM SPSS, USA).

## RESULTS

### HISTORY/SIGNALMENT

Fifty-seven cats data were included in this retrospective analysis. The young adult group (1-6 years) was mostly presented with FCGS (57.9%). Out of the 57 cats, 41 were males (19 castrated), and 16 were females (9 spayed) (Figure 1). The breeds recorded were Domestic Short Hair (DSH) (n=42), Persian (n=6), Siamese (n=4), DLH (n=3) and Bengal (n=2).

Based on the category of housing and lifestyle of the cats as in Figure 2, the majority of the cats, 45.6% were kept

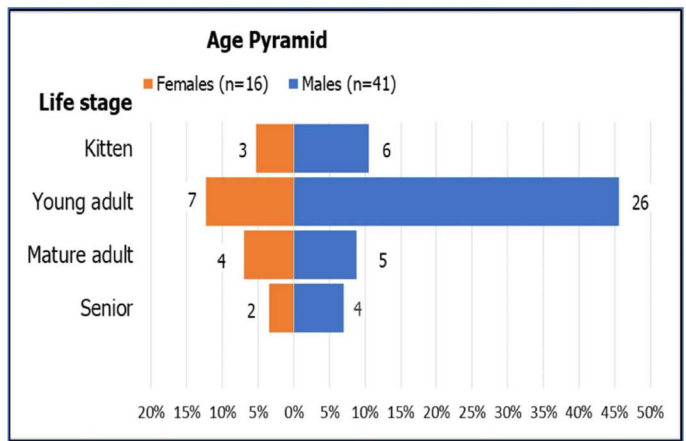


Figure 1: Pyramid age of 57 cats diagnosed with FCGS

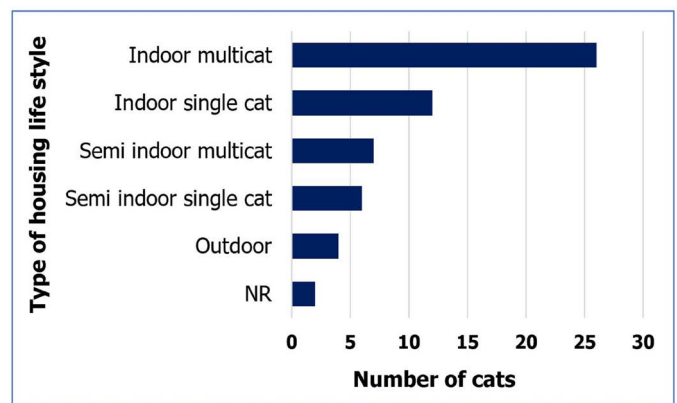


Figure 2: Type of housing and lifestyle of 57 cats with FCGS

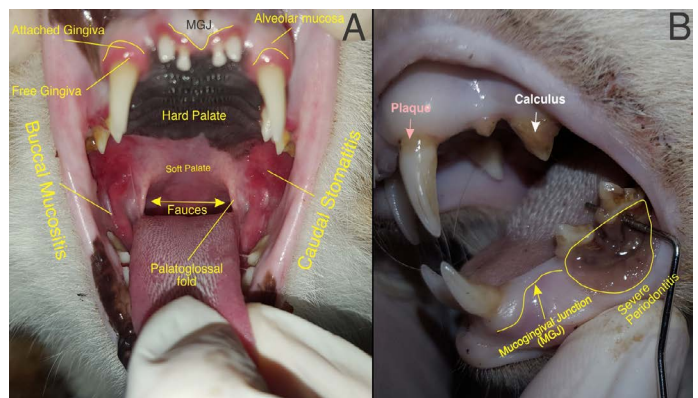


Figure 3: (A): A cat diagnosed with FCGS presented with gingivitis, buccal mucositis, caudal stomatitis (B): A cat was diagnosed with FCGS. Left mandibular third and fourth premolar (307,308) periodontal probe passes easily through the furcation.

indoor multi-cat households (26/57), 21% were kept indoor single cat (12/57), 12.3% were semi indoor multi-cat (7/57), 10.5% were semi indoor single cat (6/57), 4/57 were outdoor, and 2/57 had no record.

Out of these 57 cases, 12 cats were vaccinated (21.1%). The rest of the 45 (78.9%) cats were unvaccinated. All cats were

**Table 1:** Clinical signs of 57 cats diagnosed with FCGS

Clinical signs	Number of cases (N=57)	Percentage (%)
Halitosis	24	42
Anorexia	16	28
Ptyalism	8	14
Weight loss	5	9
Dysphagia	3	5
Bleeding gum	1	2

**Table 2:** Inflammatory regions of the oral cavity of 57 cats diagnosed with FCGS

Inflammation areas of the oral cavity	Number of cases N=57	Percentage (%)
Caudal stomatitis	57	100
Gingivitis	53	93
Glossitis	11	19
Buccal mucositis	7	12
Sublingual mucositis	4	7

**Table 3:** Hematological results of 57 cats diagnosed with FCGS

Parameters (n=57)	Normal range	Mean ± SE	Median	No. (%) Value >URL	No. (%) Value <LRL
PCV (n=57)	0.24 - 0.45 L/L	0.30 ± 0.007	0.3	0(0)	7(12.3)
CWCC (n=57)	5.5 - 19.5x 10 <sup>9</sup> /L	15.86 ± 1.01	14.3	16(28)	1(1.8)
Band Neut (n=57)	<0.3 x 10 <sup>9</sup> /L	0.34 ± 0.04	0.27	21(36.8)	0(0)
Seg. Neut (n=57)	2.5 - 12.5 x 10 <sup>9</sup> /L	11.34 ± 0.78	9.73	20(35)	0(0)
Lymphocytes (n=57)	1.5 - 7 x 10 <sup>9</sup> /L	2.34 ± 0.14	2.25	0(0)	10(17.5)
Monocytes (n=57)	0.2 - 0.8 x 10 <sup>9</sup> /L	0.77 ± 0.06	0.67	25(43.9)	2(3.5)
Eosinophils (n=56)	0.1 - 1.5 x 10 <sup>9</sup> /L	1.04 ± 0.01	0.87	14(25)	5(8.9)
Thrombocytes (n=55)	300 - 700 x 10 <sup>9</sup> /L	245.4 ± 39.36	180	1(1.8)	39(70.9)

SE: Standard error; URL: Upper reference limit; LRL: Lower reference limit; PCV: Packed Cell Volume; CWCC: Complete White Cell Count; Band Neut: Band Neutrophils; Seg. Neut: Segmented Neutrophils.

subjected to the SNAP test for FIV antibody and FeLV antigen detection. Ten cats were positive for FIV antibody, four cats positive for FeLV antigen, and two cats were positive for FIV and FeLV.

**CLINICAL FINDINGS**

Fourteen (24.6%) cats presented with pyrexia, five cats (8.8%) had hypothermia and 38 cats (66.7%) with normal temperatures. The clinical findings recorded were halitosis (42%), anorexia (28%), ptyalism (14%), weight loss (9%) dysphagia (5%), and gum bleeding (2%) in cats (Table 1). The intraoral Inflammations were localized to the various regions of the oral cavity where caudal stomatitis (100%) was the absolute finding Figure 3. Concurrent gingivitis (93%) and/ or glossitis (19%) and/or buccal mucositis (12%) and/ or sublingual mucositis (7%) are also noticed (Table 2).

**HEMATOLOGY AND SERUM BIOCHEMISTRY**

The hematology and serum biochemistry results for all the cats are reported in Table 3 and Table 4, respectively. Band neutrophilia (36.8%), segmented neutrophilia (35%), and monocytosis (43.9%) were seen in cats with FCGS. Thrombocytopenia (245.4 ± 39.36) was prominent and was found in 39/55 cats. The most prominent serum biochemistry findings were elevation of total proteins (96.5%), hyperglobulinaemia (96.5%), low albumin to globulin ratio (63.2%), increase urea (26.3%), and hypoalbuminemia (21%).

**TREATMENT MANAGEMENT AND MEDICATIONS**

The therapeutic regimen of all 57 cats were based on the combinations of 19 drugs ± complete or partial dental extraction and dental scaling are shown in Table 5. A successful follow-up with a survival status of all cases was analyzed. The patient records and descriptions from the owners indicated after partial and full mouth dental

**Table 4:** Serum biochemical results of 57 cats diagnosed with FCGS

Parameters (n=57)	Normal range	Mean ± SE	Median	No. (%) Value >URL	No. (%) Value <LRL
Sodium (n=57)	146 - 156mmol/L	151.8 ± 0.76	151.4	7(12.3)	4(7)
Potassium (n=57)	3.9 - 5.5 mmol/L	4.7 ± 0.08	4.6	5(8.8)	2(3.5)
Chloride (n=56)	110 - 132mmol/L	115.7 ± 0.9	116	1(1.8)	6(10.7)
Phosphate (n=12)	1.1 - 2.8 mmol/L	1.6 ± 0.23	1.46	1(8.3)	2(16.7)
Urea (n=57)	3 - 10 mmol/L	10.6 ± 1.43	8.6	15(26.3)	0(0)
Creatinine (n=57)	60 - 193 µmol/L	153.9 ± 19.45	132	6(10.5)	0(0)
ALT (n=57)	10 - 90 U/L	68.5 ± 12.71	44.4	7(12.3)	0(0)
ALKP (n=28)	<80 U/L	23.9 ± 4.04	16	1(3.6)	0(0)
Total protein (n=57)	55 - 75 g/L	98.1 ± 1.68	97.7	55(96.5)	0(0)
Albumin (n=57)	25 - 40 g/L	28.3 ± 0.6	28.6	0(0)	12(21)
Globulin (n=57)	25 - 45 g/L	69.8 ± 1.8	69.7	55(96.5)	0(0)
A:G ratio (n=57)	0.5 - 1.4 Unit	0.59 ± 0.11	0.4	4(7)	36(63.2)

SE: Standard error; URL: Upper reference limit; LRL: Lower reference limit; ALT: Alanine Transaminase; ALKP: Alkaline Phosphatase; A: G= Albumin: Globulin Ratio

**Table 5:** Therapeutic combination and the outcomes for 57 cats diagnosed with FCGS between 2008-2018 in UPM.

	Therapeutic Combinations (Total 19)	Survival Status N=57	Remarks	Recovery Outcome
1	AB+ENZ+SM	3 Dead, 1 Missing	Out of 3 dead cats, 2 partially responded to medicine, but one died because of FIV, another one because of infectious pneumonia during FCGS management. One didn't respond to medicine and died. One cat went missing, but the owner claimed medicine resolved the primary complaint	2 PR *1 FR 1/4 Died
2	AB+ENZ+ANALG+SAID	2 Dead, 3 Alive, 1 Missing	1 Died because of kidney disease, another one because of poisoning but the primary complaint resolved. For 1 missing and 3 alive cats, medicine resolved the primary complaint	*1 FR 4 FR 1/6 Died
3	AB+ANALG+NSAID+SM	1 Missing, 2 Dead	For 1 missing cat, medicine resolves the clinical signs. 2 dead cats didn't respond to medication and died due to not eating.	*1 FR 2/3 Died
4	AB+ENZ+OA	5 Dead, 2 Missing, 1 Alive	2 cats died because of kidney disease with FCGS persist. Another 2 died during FCGS management; 1 went for extraction and died after 2 days. For the alive cat, medicine able to suppress clinical signs. For missing cats, medicine controlled the clinical signs.	3 PR 5/8 Died
5	AB+ENZ+SAID+SM	4 Dead, 3 Alive	1 cat died because of kidney disease during FCGS management, and another two died because of FCGS; the 4 <sup>th</sup> died because of FIP but partially responded to medicine. For 2 alive cats, the disease is under control; FCGS persists in 3 <sup>rd</sup> cat.	3 PR 3/7 Died
6	AB+ANALG+SAID	1 Alive	On and off flare-up episodes if medicine stopped	1 PR
7	AB+OA	1 Dead	Diagnosed with FeLV and euthanized	



8	AB+ENZ+ANALG	3 Dead, 1 Alive	In 2 dead cats, partial remission was achieved for some time but died because of the FCGS, and one died because of jaundice during the management of FCGS. For 1 alive cat, medicine was adequate to control clinical signs	3 PR 2/4 Died
9	AB+ANALG+SM	1 Dead	No response to medication and died because of the FCGS problem	1/1 Died
10	AB+OA+SM	1 Dead	Partial improvement in clinical signs seen but died because of kidney disease.	1/1 Died
11	AB+ENZ+ANALG+DE	1 Dead	Partial remission was seen with medicine and partial dental extraction—cause of death unknown.	1 PR
12	AB+ENZ+ANALG+-SAID+SM+DE	3 Alive, 2 Dead	For 2 alive cats, intra-lesion triamcinolone injection and partial dental extraction resolved the primary complaint. The 3 <sup>rd</sup> alive cat full mouth dental extraction resolved FCGS clinical signs. For 1 dead cat, intra-lesion triamcinolone injection and partial dental extraction resolved the primary complaint but died because of kidney disease during FCGS management. 2 <sup>nd</sup> dead cat achieved complete remission with full mouth dental extraction but died because of poisoning.	1 PR 4 FR
13	AB+ENZ+ANALG+SM+DE	2 Alive, 2 Dead, 1 Missing	In 2 alive and 2 dead cats, complete remission was achieved after partial dental extractions. FIP was the reason for death. 1 missing cat went through the same treatment, boarded for some time in UPM, non-compliant owner, although clinical signs resolved during boarding	4 FR *1 FR
14	AB+SAID+SCALING	1 Dead	No response to the medicine and dental scaling. Cause of death unknown.	1/1 Died
15	AB+ENZ+ANALG+-SAID+DE	2 Alive, 1 Dead	For 2 alive cats, complete remission achieved with intra-lesion triamcinolone injection and full mouth dental extraction but partial remission seen in another cat which was euthanized later because of FIP, asthma, and CKD	1 PR 2 FR
16	AB+ENZ+SM+DE	1 Dead	Complete remission achieved with intra-lesion triamcinolone injection and full mouth dental extraction died because of kidney failure	1 FR
17	AB+ANALG+SAID+DE	1 Alive, 1 Dead	1 alive cat achieved full remission with full mouth dental extraction. In dead cat partial remission achieved with partial dental extraction and medicine, died because of some poisoning later	1FR 1 PR 1 Died
18	AB+ANALG+SAID+SCALING	2 Alive	For one cat caudal dental extraction done at another private clinic and in another cat medicine and scaling resolved the clinical signs	*2 FR
19	AB+ENZ+SCALING	1 Dead	Died because of kidney failure	1/1 Died

AB: Antibiotic/s (Amoxicillin, Amoxicillin-clavulanic acid, Metronidazole, Metronidazole and Spiramycin, Clindamycin, Doxycycline, Enrofloxacin, Marbofloxacin, Azithromycin); NSAID: Non-steroidal anti-inflammatory drug (Meloxicam); SAID: Steroidal anti-inflammatory drugs (Prednisolone, Methylprednisolone acetate, Triamcinolone acetonide); ENZ: Enzyme (Danzen/Serratiopeptidase, Papain); OA: Oral aid lotion (Lignocaine HCl 2.5%, Chlorhexidine HCl 0.5%, Triamcinolone Acetonide 0.1%), UPHA Pharmaceutical MFG. (M) SDN. BHD. Malaysia; ANALG: Analgesic (Tramadol); DE: Partial or complete dental extraction; SCALING: Dental scaling; SM: Supportive medicine/s; (Vitamin B Complex, Vitamin C, Vetri DMG); UPM: Universiti Putra Malaysia; FIP: Feline Infectious Peritonitis; PR: Partial Remission; FR: Fully recovered; \*n FR: number of cats which are described fully recovered by the owners on telephonic review but cats are either dead now or missing from home or owners were not hundred percent sure about the recurrence of disease after last successful treatment; Denominator for the cats which died because of treatment

failure in outcome section indicates the number of cats whose survival status is known, so it doesn't include cats whose follow up has been lost; Intra-lesion injection: Triamcinolone acetonide.

extraction of 28% (16/57) affected cats with FCGS, one (1.7%) cat died, 2 (3.5%) cats were achieved partial remission, and 13 (22.8%) cats were achieved fully recovered, while no clinical sign observed (anecdotal + reliable information from patient records and owners) in 22/57 (39%) cases. The death percentage was 33% (n=19), specifically included those cases where treatment failure of FCGS was considered the primary reason for the death. Twenty-five percent (n=23) of cats had dental extraction.

## DISCUSSION

All 57 cats were diagnosed with FCGS based on the pathognomonic lesions of the oral cavity, as shown in Figure 3. In this present study, the median age is 5 years old (range: 8 months to 15 years old) with 33/57 was from young adult category (1-6 years). Few studies also found the similar age range to be most presented with FCGS (Healey et al., 2007; Farcas et al., 2014).

Predisposed breeds previously reported were Burmese, Siamese, Abyssinian, Persian, and Himalayan (Healey et al., 2007; Farcas et al., 2014). However, in this study majority was DSH (42/57) due to overrepresentation in the sample size. Pedigree cat is usually a minority in our local setting. Dolieslager et al. (2013) and Hung et al. (2014) found DSH breed to be a major group of the population affected with FCGS.

In this study, 45.6% (26/57) of cats were living in the multi-cat household. Multi-cat household is considered as a risk factor of FCGS. One additional cat in the household increased the likelihood of getting FCGS by 70% (Peralta and Carney, 2019). The increased stress level and higher chances of exposed to infectious organisms from cohabitants could be the culprits.

Halitosis was the most presented clinical findings in cats with FCGS in this study. Halitosis generally can be caused by both systemic and oral disorders. However oral etiology is responsible for the majority of cases (Cortelli et al., 2008). Halitosis in FCGS cats had been reported in the previous study (Bellei et al., 2008). Halitosis could be the initial indicator of FCGS before other clinical signs kick in. The owner must be made aware of bringing their cats for early oral examination before the condition worsen.

Hematological and biochemistry analysis is an essential part of initial investigation to rule out other systemic diseases and potential causes of similar types of oral cavity inflammatory conditions (Milella, 2008; Bloor, 2013). He-

matological and biochemical findings suggest inflammatory processes (leukocytosis, neutrophilia, and elevation of globulin (Allison et al., 2009; Piek, 2010) were found in the majority of FCGS patients in this study.

Increases in the number of monocytes and eosinophils can be caused by tissue damage and chronic infections (Kratofil et al., 2017), or associated with FCGS progression. Monocyte recruitment to inflammatory sites is critical for host defense. Monocytes circulate through the blood and extravasate into inflamed tissues during inflammation, following the general leukocyte recruitment cascade (Ley et al., 2007).

Changes in cats' protein levels were due to systemic diseases, chronic infectious and inflammatory processes, and neoplastic disorders (Aslam et al., 2019; McGrotty and Knottenbelt, 2002). Serum globulin levels had been reported to increase in cats with FCGS (Mihaljevic, 2003).

A different veterinarian saw each case in the UVH. Hence no standardized treatment protocols were practiced, eventually, end up with multiple treatment combinations. Furthermore, most owners will decline partial or full mouth dental extraction during the first few visits as they presumed it was inhumane. They prefer to try on various medicine combination treatments.

In the present study, serratiopeptidase (Jadav et al., 2010) and papain (Rakhimov, 2001; Amri and Mamboya, 2012) have been used as an alternative to NSAIDS or SAIDS when applications are contraindicated in patients with concurrent kidney disease or diabetes. Serratiopeptidase works by reducing the amount of fluid in the tissues, which reduces swelling. Furthermore, its enzyme activity removes dead tissue, speeding up healing and relieve pain (Bhagat et al., 2013). Papain is a natural enzyme generated from papaya fruit latex (*Carica papaya*). A study reported that minor injuries healed faster with papain and cut recovery time from 8.4 days to 3.9 days (Amri and Mamboya, 2012). However, 50% of cats (with known survival status) died with serratiopeptidase/ papain were only used to manage inflammation and pain. Hence serratiopeptidase/ papain alone may not be adequate to manage pain and inflammation in cats diagnosed with FCGS. To improve FCGS patients, a combination of good oral hygiene, partial or complete dental extractions, plus adjunctive medical treatment is dedicated (Cannon, 2015).

Medical treatment with anti-inflammatory, antimicrobial, and analgesic medications are mostly experimentally tried, but long-term signs resolution associated with stomatitis in cats are rare (Jennings et al., 2015). The use of antibiot-

ics is not the first choice of treatment for FCGS. However, antibiotics must be used as bacteria do play a part as a secondary problem. Broad-spectrum antibiotics such as synthetic penicillin, cephalosporin, tetracycline, trimethoprim plus sulfamethoxazole, Lincocin have been used (Frost and Williams, 1986).

Corticosteroids are recommended in FCGS cases because of their immunosuppressive and anti-inflammatory effects (Frost and Williams, 1986; Diehl and Rosychuk, 1993; Lyon, 2005). Improvement was reported in 50% to 80% of cases in a research that looked at various corticosteroids (White et al., 1992). In this present study, 12 cats received prednisolone, methylprednisolone acetate, and triamcinolone acetonide as steroidal anti-inflammatory drugs.

Triamcinolone acetonide, a long-acting synthetic glucocorticoid, has been used for the treatment of inflammatory disease. Of the many drug delivery systems, buccal drug delivery has some advantages such the abundant blood supply in the buccal area, bypassing the hepatic first-pass effect, excellent accessibility. It is challenging to apply ointment, solutions, creams, and lotions as they are very easily removed by salivation, tongue movement, and swallowing reflex (Shin & Kim, 2000).

Triamcinolone intralesional injection is beneficial for FCGS cats that refuse to eat due to severe pain. Generally, cats able to resume food consumption after intralesional injection at the caudal stoma region. Recovery from anorexia is beneficial to improve the blood parameter such as hypoalbuminemia and prepare the cat for long general anesthesia and dental extraction.

Partial or complete dental extraction and topical application like oral aid lotion and/or oral medicine had been applied in 16/57 (28%) cats, and 1.7% (n=1) was dead, 3.5% (n=2) were achieved partial remission, and 22.8% (n=13) resolved clinical signs. A previous study reported that two-thirds of cats got substantial or complete improvement (Jennings et al., 2015). Dental extraction removes both the direct and indirect effects of dental bacterial plaque in the affected areas (Hennet, 1997).

By looking at the records and anecdotal information of recovery from owners it can be suggested that almost 30-39% (\*6+16) cats had FCGS clinical signs resolved from all types of therapeutic combinations. Only 10-19% (\*3+4) cats showed no sign of FCGS from the owner observation from combinations with medicines and/or oral aid only. 60-71% of patients had FCGS clinical signs resolved with combinations including dental scaling + partial or complete dental extraction and medicine before and after the dental extraction.

This study suggests a good prognosis of FCGS cases that undergo partial or full mouth dental extraction along with adjunctive therapy. In a previous study (Hennet, 1997), about 60% of cases have achieved complete resolution of inflammation after extraction, 20% left with minimal residual inflammation without any pain sign, 13% need adjunctive medical therapy and remaining 7% did not respond to extraction.

FCGS is characterized by severe oral pain and inflammation in the caudal region of the oral cavity, as well as swollen, ulcerated, and bleeding gums. If the condition is not treated, it may grow so painful that an affected cat will be unable to eat and will starve to death. Chronic disease has been associated with decreasing quality of life at the time of death (Gates et al., 2017). Hence the FCGS condition in cats must not be neglected. Inability to eat due to severe oral pain leading to anorexia is inhumane. To the author's knowledge, this is the first report of ineffective usage of serratiopeptidase and papain in the management of FCGS.

The limitation of this study is a retrospective study with a small sample size due to exclusion and inclusion criteria. Furthermore, no standardized treatment protocol for FCGS and loss of follow-up to evaluate treatment outcomes.

## CONCLUSIONS

FCGS is an idiopathic and frustrating syndrome to treat due to its complex etiology. The diagnosis depends on the clinical features and poor treatment response to initial ancillary therapy. The ability to recognize the early clinical presentation, such as halitosis, will prevent the cat from experiencing starvation due to the inability to eat. Dental extraction provides good long-term outcomes. Our findings suggest that partial or complete dental extraction ± intra-lesion triamcinolone acetonide injection is a good combination to manage FCGS. Enzymes like Serratiopeptidase and papain could not improve the quality of life to manage pain and inflammation.

## CONFLICT OF INTERESTS

The authors declare that they have no conflict of interest.

## AUTHORS CONTRIBUTION

Mohammad Hussain Haidary and Rozanaliza Radzi contributions in the design and major drafting, critical reviews of this article. Mohammad Hussain Haidary, Muhammad Waseem Aslam, Ahmad Rasul, Lau Seng Fong, and Farina Mustaffa Kamal were responsible for data collection and



analysis.

## REFERENCES

- Allison Robin W, James H Meinkoth, Theresa E Rizzi (2009). Abnormalities of the Standard Biochemical Profile. In *Small Anim. Med. Diagn.* 627.
- Amri E, Mamboya F (2012). Papain, A plant enzyme of biological importance: A review. *American J. Biochem. Biotechnol.* 8(2): 99–104. <https://doi.org/10.3844/ajbbsp.2012.99.104>
- Aslam MW, Lau SF, Chin CSL, Ahmad NI, Rahman NA, Kuppusamy K, Omar S, Radzi R (2019). Clinicopathological and radiographic features in 40 cats diagnosed with pulmonary and cutaneous *Rhodococcus equi* infection (2012–2018). *J. Feline Med. Surg.* 1–17. <https://doi.org/10.1177/1098612X19886395>
- Bellei E, Dalla F, Masetti L, Pisoni L, Joechler M (2008). Surgical therapy in chronic feline gingivostomatitis (FCGS). *Vet. Res. Comun.* 32(1): 231–234. <https://doi.org/10.1007/s11259-008-9153-8>
- Bhagat S, Agarwal M, Roy V (2013). Serratiopeptidase: A systematic review of the existing evidence. *Int. J. Surg.* 11(3): 209–217. <https://doi.org/10.1016/j.ijsu.2013.01.010>
- Bloor C (2013). Gingivostomatitis: An Update. *Vet. Nurse.* 4(7): 400–407. <https://doi.org/10.12968/vetn.2013.4.7.400>
- Cannon M (2015). Feline Chronic Gingivostomatitis. *Companion Anim.* 20(11): 618–623. <https://doi.org/10.12968/coan.2015.20.11.616>
- Cortelli JR, Barbosa MDS, Westphal MA (2008). Halitosis: A review of associated factors and therapeutic approach. *Brazilian Oral Res.* 22 (1): 44–54. <https://doi.org/10.1590/S1806-83242008000500007>
- Diehl K, Rosychuk RAW (1993). Feline Gingivitis-Stomatitis-Pharyngitis. *Vet. Clin. North America: Small Anim. Pract.* 23(1): 139–153. [https://doi.org/10.1016/S0195-5616\(93\)50009-8](https://doi.org/10.1016/S0195-5616(93)50009-8)
- Dolieslager SMJ, Riggio MP, Lennon A, Lappin DF, Johnston N, Taylor D, Bennett D (2011). Identification of bacteria associated with feline chronic gingivostomatitis using culture-dependent and culture-independent methods. *Vet. Microbiol.* 148(1): 93–98. <https://doi.org/10.1016/j.vetmic.2010.08.002>
- Dolieslager SMJ, Lappin DF, Bennett D, Graham L, Johnston N, Riggio MP (2013). The influence of oral bacteria on tissue levels of Toll-like receptor and cytokine mRNAs in feline chronic gingivostomatitis and oral health. *Vet. Immunol. Immunopathol.* 151(3–4): 263–274. <https://doi.org/10.1016/j.vetimm.2012.11.016>
- Farcas N, Lommer MJ, Kass PH, Verstraete FJ (2014). Dental Radiographic Findings in Cats with Chronic Gingivostomatitis (2002–2012). *J. American Vet. Med. Assoc.* 244(3): 339–345. <https://doi.org/10.2460/javma.244.3.339>
- Frost P, Williams CA (1986). Feline Dental Disease. *Vet. Clin. North America Small Anim. Pract.* 16(5): 851–873. [https://doi.org/10.1016/S0195-5616\(86\)50305-3](https://doi.org/10.1016/S0195-5616(86)50305-3)
- Gates MC, Hinds HJ, Dale A (2017). Preliminary description of aging cats and dogs presented to a New Zealand first-opinion veterinary clinic at end-of-life. *New Zealand Vet. J.* 65(6): 313–317. <https://doi.org/10.1080/00480169.2017.1360161>
- Harley R, Helps CR, Harbour DA, Gruffydd-Jones TJ, Day MJ (1999). Cytokine mRNA expression in lesions in cats with chronic gingivostomatitis. *Clin. Diagnost. Laborat. Immunol.* 6(4): 471–478. <https://doi.org/10.1136/vr.152.5.125>
- Harley R, TJ Gruffydd-Jones, MJ Day (2003). Salivary and Serum Immunoglobulin Levels in Cats with Chronic Gingivostomatitis. *Vet. Rec.* 152(5): 125–129. <https://doi.org/10.1136/vr.152.5.125>
- Healey KAE, Dawson S, Burrow R, Cripps P, Gaskell CJ, Hart CA, Pinchbeck GL, Radford AD, Gaskell RM (2007). Prevalence of feline chronic gingivostomatitis in first opinion veterinary practice. *J. Feline Med. Surg.* 9(5): 373–381. <https://doi.org/10.1016/j.jfms.2007.03.003>
- Hennet P (1997). Chronic Gingivostomatitis in Cats: Long-Term Follow-up of 30 Cases Treated by Dental Extractions. *J. Vet. Dentist.* 14(1): 15–21. <https://doi.org/10.1177/089875649701400103>
- Hung YP, Yang YP, Wang HC, Liao JW, Hsu WL, Chang CC, Chang SC (2014). Bovine lactoferrin and piroxicam as an adjunct treatment for lymphocytic-plasmacytic gingivitis stomatitis in cats. *Vet. J.* 202(1): 76–82. <https://doi.org/10.1016/j.tvjl.2014.06.006>
- Jadav SP, Patel NH, Shah TG, Gajera MV, Trivedi HR, Shah BK (2010). Comparison of anti-inflammatory activity of serratiopeptidase and diclofenac in albino rats. *J. Pharmacol. Pharmacotherap.* 1 (2): 116. <https://doi.org/10.4103/0976-500X.72362>
- Jameson P, Greene C, Regnery R, Dryden M, Marks A, Brown J, Cooper J, Glaus B, Greene R (1995). Prevalence of *Bartonella henselae* Antibodies in Pet Cats throughout Regions of North America. *J. Infect. Dis.* 172: 1145–1149. <https://doi.org/10.1093/infdis/172.4.1145>
- Jennings MW, Lewis JR, Soltero-Rivera MM, Brown DC, Reiter A M (2015). Effect of tooth extraction on stomatitis in cats: 95 cases (2000–2013). *J. American Vet. Med. Assoc.* 246(6): 654–660. <https://doi.org/10.2460/javma.246.6.654>
- Kornya MR, Little SE, Scherk MA, Sears WC, Bienzle D (2014). Association between oral health status and retrovirus test results in cats. *J. American Vet. Med. Assoc.* 245(8): 916–922. <https://doi.org/10.2460/javma.245.8.916>
- Kratofil RM, Kubes P, Deniset JF (2017). Monocyte conversion during inflammation and injury. *Arteriosclerosis, Thrombosis and Vasc. Biol.* 37(1): 1–8. <https://doi.org/10.1161/ATVBAHA.116.308198>
- Ley K, Laudanna C, Cybulsky MI, Nourshargh S (2007). Getting to the site of inflammation: The leukocyte adhesion cascade updated. *Nat. Rev. Immunol.* 7(9): 678–689. <https://doi.org/10.1038/nri2156>
- Lyon KF (2005). Gingivostomatitis. *Vet. Clin. North America - Small Anim. Pract.* 35 (4): 891–911. <https://doi.org/10.1016/j.cvsm.2005.02.001>
- McGrotty Y, Knottenbelt C (2002). Significance of Plasma Protein Abnormalities in Dogs and Cats. *Compan. Anim. In Pract.* 24(9): 512–517. <https://doi.org/10.1136/inpract.24.9.512>
- Mihaljevic SY (2003). First clinical experiences with omega-interferon in the treatment of chronic gingivitis-stomatitis-opharyngitis of cats. *Der Praktische Tierarzt.* 84(5): 350–361.
- Milella L (2008). Chronic Gingivostomatitis in Cats. *Compan. Anim.* 13(2): 77–81. <https://doi.org/10.1111/j.2044-3862.2008.tb00246.x>
- Peralta S, Carney PC (2019). Feline Chronic Gingivostomatitis



- Is More Prevalent in Shared Households and Its Risk Correlates with the Number of Cohabiting Cats. *J. Feline Med. Surg.* 21(12): 1165-1171. <https://doi.org/10.1177/1098612X18823584>
- Piek CJ (2010). The Interpretation of Automated Haematology Analyser Data in Practice. *Compan. Anim. Pract.* 20(2): 177-185.
- Quimby J, Gowland S, Carney HC, DePorter T, Plummer P, Westropp J (2021). 2021 AAHA/AAFP Feline Life Stage Guidelines. *J. American Anim. Hosp. Assoc.* 57(2): 51-72. <https://doi.org/10.5326/JAAHA-MS-7189>
- Rakhimov MR (2001). Anti-Inflammatory Activity of Domestic Papain. *Eksperimental'naiia i klinicheskaia farmakologiiia* 64(4): 48-49.
- Shin SC, Kim JY (2000). Enhanced permeation of triamcinolone acetone through the buccal mucosa. *European J. Pharmaceut. Biopharmaceut.* 50(2): 217-220. [https://doi.org/10.1016/S0939-6411\(00\)00101-6](https://doi.org/10.1016/S0939-6411(00)00101-6)
- Southerden P (2010). Review of Feline Oral Disease: 1. Periodontitis and Chronic Gingivostomatitis. *Compan. Anim. Pract.* 32(1): 2-7. <https://doi.org/10.1136/inp.b5501>
- White SD, Rosychuk RAW, Janik TA, Denerolle P, Schulthesis P (1992) Plasma-cell stomatitis-pharyngitis in cats - 40 cases (1973-1991). *J. American Vet. Med. Assoc.* 200(9): 1377-1380.
- Winer JN, Arzi B, Verstraete FJM (2016). Therapeutic Management of Feline Chronic Gingivostomatitis: A Systematic Review of the Literature. *Front. Vet. Sci.* 3(54). <https://doi.org/10.3389/fvets.2016.00054>