



# Anatomical Descriptions and Histological Observation Study of the Eyes in Domestic Duck (*Anas platyrhynchos*)

MOHAMMED A. ALI<sup>1\*</sup>, FIRAS A. ALHASSON<sup>1</sup>, THAER A. MOHSIN<sup>2</sup>

<sup>1</sup>Department of Anatomy, Histology and Embryology, College of Veterinary Medicine, University of Basra, Basra, Iraq; <sup>2</sup>Department of Pathology, College of Veterinary Medicine, University of Basra, Basra, Iraq.

**Abstract** | The eyes of birds play a crucial role in vision as well as other physiological activities including eating and movement. The eyes of the duck (*Anas platyrhynchos*) were studied in terms of anatomical and histological features in this study. From the exterior to the inside, light microscopic studies revealed that the eye of *Anas platyrhynchos* was made up of three layers: (a) the External layer (fibrous) (the sclera and cornea); (b) the Middle layer (Vascular) the choroid, ciliary body, and iris and (c) Internal layer (Nervous) the retina. A squamous corneal epithelium, the stroma, and the corneal endothelium were all well-defined layers of the cornea. *Anas platyrhynchos*' lens was spherical and encased by a lens capsule, with a monolayer of epithelial cells covering its anterior surface. Unlike terrestrial animals, the posterior sclera was made up of a cartilaginous cup contained in a collagenous matrix. The retina was avascular, and the layers of the retina were arranged in a normal vertebrate pattern.

**Keywords** | Eyes, Ducks, Anatomy, Histology, *Anas platyrhynchos*, Microanatomy.

Received | May 19, 2023; Accepted | June 20, 2023; Published | December 16, 2023

\*Correspondence | Mohammed Ali, Department of Anatomy, Histology and Embryology, College of Veterinary Medicine, University of Basra, Basra, Iraq;

Email: Firas.alhasson@uobasrah.edu.iq

Citation | Ali MA, Alhasson FA, Mohsin TA (2024). Anatomical descriptions and histological observation study of the eyes in domestic duck (*Anas platyrhynchos*). Adv. Anim. Vet. Sci. 12(1): 26-31.

DOI | <http://dx.doi.org/10.17582/journal.aavs/2024/12.1.26.31>

ISSN (Online) | 2307-8316



Copyright: 2023 by the authors. Licensee ResearchersLinks Ltd, England, UK.

This article is an open access article distributed under the terms and conditions of the Creative Commons Attribution (CC BY) license (<https://creativecommons.org/licenses/by/4.0/>).

## INTRODUCTION

The domestic duck is beyond the Mallard family (*Anas platyrhynchos*). Mallards can be found almost anywhere in the world. They dominate the Northern Hemisphere and can be found easily in Oceania, Asia, Africa, South America, and many other islands. Since these kinds of animals are found everywhere, knowing and understanding the anatomical and physiological can provide a wealth of information about these fascinating creatures. It can help us understand how birds are built, how they function, and how they have adapted to their environments. This knowledge can be useful for a variety of purposes, including conservation, research, and education.

The eyes are a vital organ in all animals that survive in the

wild and oscine. Even the eye's size is small compared with the body size, the eye plays a critical role in human and animal survival. For instance, the exterior eye structures' primary function is to protect the inside eye's tissue and help in refreshing eyes through blinking. The eye's internal elements also have the most important roles such as the cornea which is responsible for two-thirds of the eye's refractive capabilities and acts as a protective layer. The lens is responsible for the remaining one-third of refraction. Although there are many functions linked to the eyes, vision and light processing are still the most important ones. The process is more complex, involving additional structures and mechanisms, but the basic principle revolves around the interaction between light and the eyes. As light rays bend through the cornea and lens at the conclusion of the visual process, photon energy is converted to neurochemical action potentials by retinal cells, which subsequently

deliver these impulses to the brain through the optic nerve. (Tejus et al., 2021).

The anatomy of the eye is complex and fascinating, with each component playing an essential role in vision. Generally, the eye in the vertebrates consists of three main components, the optic components, which include the cornea, lens, and iris, the photosensitive layer, and the retina, which consists of a high-capacity neural network that processes nerve signals electronically. The electronic nerve signals originate mainly from the photoreceptors in the retina. The Visual pigment absorbs the light as well as Protects the casing consisting of the Pigmented choroid and the Retinal pigment epithelium. Functionally, these three parts are similar to the modern photographic camera (Marina et al., 2020; Firas et al., 2021). Histologically, the eyeball has three layers: The first layer is the fibrous layer that contains the sclera and cornea. The sclera is the tough, white layer outer layer of the eyeball. it is composed mainly of collagen fibers and fibroblasts. The cornea, on the other hand, is the transparent, dome-shaped structure that forms the front of the eye. It consists of five layers: epithelium, Bowman's layer, stroma, Descemet's membrane, and endothelium. The epithelium is composed of stratified squamous cells, Bowman's layer is acellular and composed of collagen fibers, the stroma is the thickest layer and consists of collagen fibers and keratocytes, Descemet's membrane is a thin layer of collagen, and the endothelium is a single layer of cells. The second layer is the uvea layer (Vascular layer) which includes the choroid, ciliary body, and iris. The choroid is a vascular layer located between the sclera and the retina. It supplies oxygen and nutrients to the outer layers of the retina. Histologically, it contains blood vessels, pigmented cells, and connective tissue. The ciliary body is located behind the iris and produces the aqueous humor that fills the anterior chamber of the eye. It is composed of ciliary muscle and ciliary processes. The iris is the colored part of the eye and regulates the amount of light entering the eye. Histologically, it consists of smooth muscle fibers and pigmented epithelial cells. Finally, the third layer, the Nervous layer (retina layer) The retina is the innermost layer of the eyeball that contains the photoreceptor cells responsible for sensing light. It consists of several layers (Mohammed, 2008; Mohammed, 2016; Maria et al., 2016; Chen and Terry, 2019). The purpose of this study is to understand the anatomical and histological structure of the eye in domestic ducks which in turn, allows us to explore the intricate details of the domestic duck eye's anatomy, physiology, and health. It contributes to various fields of study, including comparative biology, ecology, veterinary medicine, conservation, and evolutionary biology, enhancing our understanding of these remarkable creatures and aiding in their conservation and management. Finally, This study could contribute to understanding the anatomy of

birds can also help us appreciate their beauty and diversity, and can enrich our overall understanding of the natural world.

## MATERIALS AND METHODS

Ten of the male adult domestic Duck (*Anas platyrhynchos*), were purchased from Basra province's local markets. All ducks had a permit to food and water and were housed in a temperature-controlled room at 23–24°C with a 12-hour light/dark cycle. All animals were treated in strict accordance with the University of Basrah Guide for Laboratory Animals and Animal Care. After two weeks of purchasing, the animals were sacrificed for the anatomical and histological study. The eyes were isolated from the head, washed with buffer solution, and then fixed with 10% neutral buffered formalin. Hematoxylin and Eosin stain were used to stain paraffin slices that were (5-7) µm in thickness according to (Luna, 1968; Bancroft's, 2020). in summary, specimens underwent a series of processing starting with dehydration with ethanol( ascending 50-100%), clearing with xylene, and embedding with paraffin wax. Next, the specimens were blocked and sectioned using a microtome. Then, for staining, the slides were hydrated, stained, dehydrated, and mounted.

## RESULTS

### ANATOMICAL RESULTS

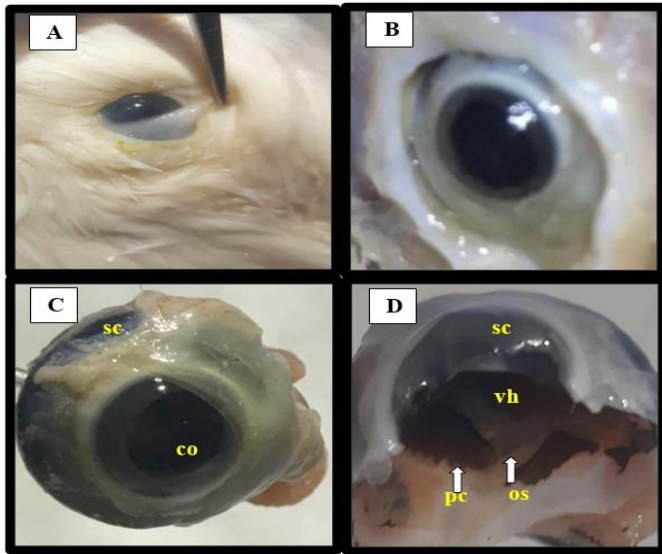
The general anatomical characteristics of eyes, according to the present study were like the following; the birds have three eyelids: one upper and one lower, with the lower being more moveable. Plus, there's a nictitating membrane that sits between the other two eyelids and the cornea, with its own lubricating channel that's similar to a tear duct. It's used to keep the eyes clean and safe Figure 1 (A). The muscles and contributory glands, as well as the conjunctiva, were obvious. The conjunctiva is a thin layer of tissue that coats the inside of the eyelids. Also covers the eyeball and is mostly of muscle tissue Figure 1 (B&C). Also, the photograph equatorial section of the eye duck was found.

### HISTOLOGICAL RESULTS

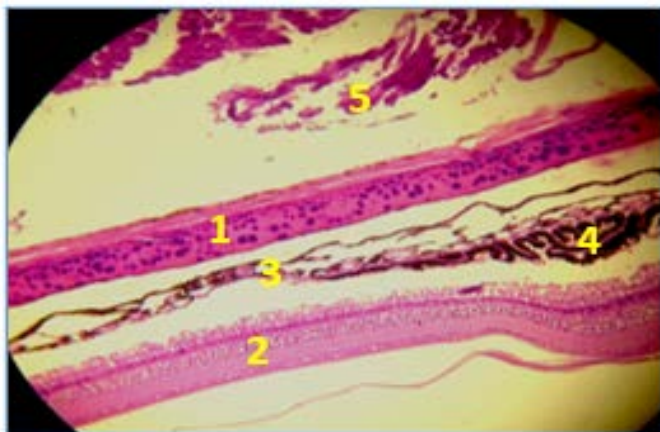
The internal structures of the eye in domestic ducks consist of three layers: External layers (Fibrous Tunica, subdivided into the sclera and cornea), the middle layer (vascular layer or uvea), subdivided into the iris, ciliary body, and choroid, and the internal layer(nervous layer or retina), consisting of ten layers. All of these layers can be further subdivided and classified histologically.

The external layers (Fibrous Tunica, subdivided into the sclera and cornea): The sclera was a thick connective tissue composed primarily of collagen fibers orientated in various

orientations. Episclera, stroma, lamina fusca, and endothelium were the four layers of the sclera, from exterior to interior. (Figures 2 and 3).



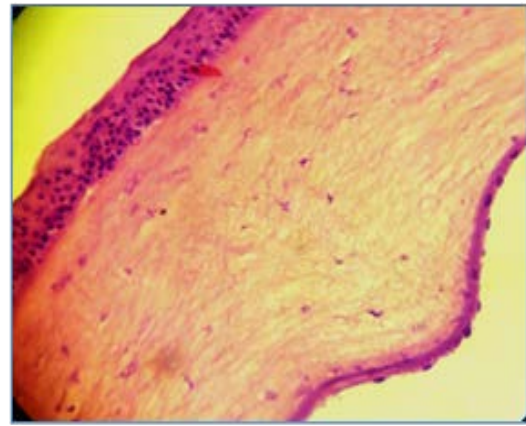
**Figure 1:** Anatomical structure of the eye in duck show Sclera (sc), Cornea (co), Vitreous humour (vt), Ora Serrata (os), and posterior chamber (pc).



**Figure 2:** Micrographic of eye in duck shows: 1- Sclera, 2- Retina, 3- Choroid, 4- Ciliary process and 5- Muscles. (H&E 200X).

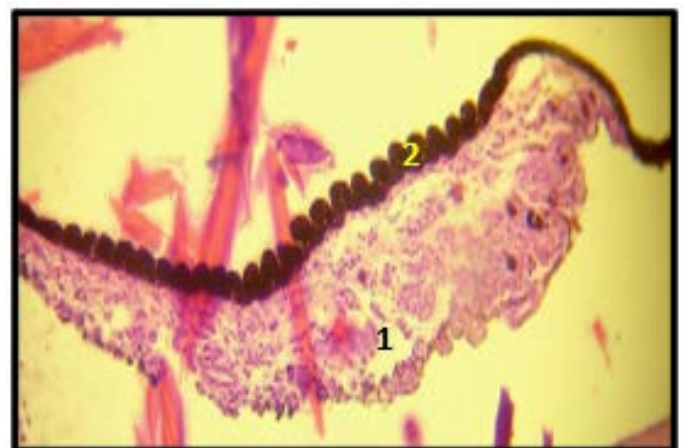To preserve transparency, the cornea (transparent front layer of the eye) was made up of collagen fibers that were arranged in a uniform parallel orientation. The epithelium (non-keratinized, stratified squamous epithelium), Bowman layer, stroma (also known as substantiapropria), Descemet’s membrane, and corneal endothelium are the five layers that made up the cornea. (Figures 2 and 3).

The second layer, the middle layer (vascular layer or Uvea), was subdivided into the iris, ciliary body, and choroid. Iris was made up of a pigmented stroma layer and fibro-vascular tissue and Underneath the stroma, there were pigmented epithelial cells. The Pigmented layer worked as a



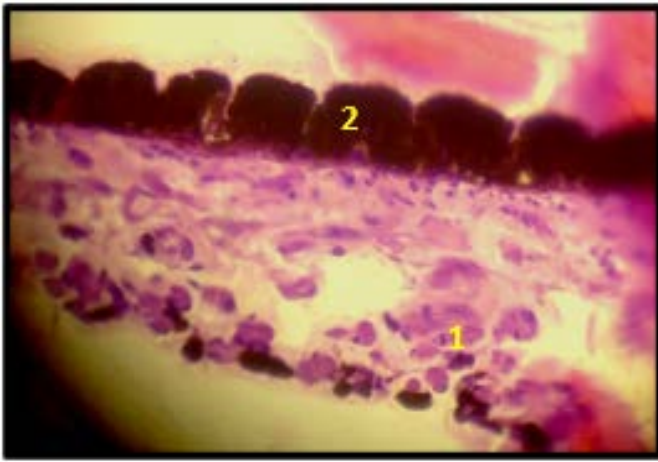
**Figure 3:** Micrographic of eye in duck shows section through the cornea: 1- Corneal epithelium Stratified squamous epithelium non- keratinized, 2- Bowman membrane, 3- Stroma (also called substantia propria), 4- Descemet’s membrane and 5- Corneal endothelium (H&E 400X)

light barrier to prevent light only through the pupil. The ciliary muscle and the ciliary epithelium made up the ciliary body, which separated the posterior chamber from the vitreous body. Aqueous humor was produced by the ciliary epithelium and filled the anterior compartment of the eye. (Figures 4 and 5). The choroid was a thick network of blood vessels that provided sustenance to the eye’s tissues and was contained in connective tissue loose type. (Figure 2). The third layer of the eyes was the internal layer (nervous layer or retina): Which consists of the Retina, Vitreous, and Lens. The lens was made up of an exterior capsule, a middle layer called the cortex, and an inner layer called a nucleus that separated the aqueous and vitreous chambers. The capsule was the lens epithelium’s basement membrane, which was located underneath the lens. (Figure 6).

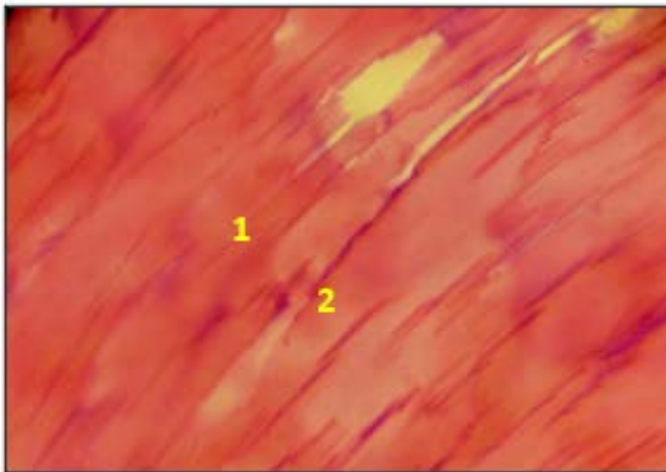


**Figure 4:** Micrographic of eye in duck shows ciliary body: 1- Ciliary muscle and 2- Ciliary epithelium (H&E stain X200).

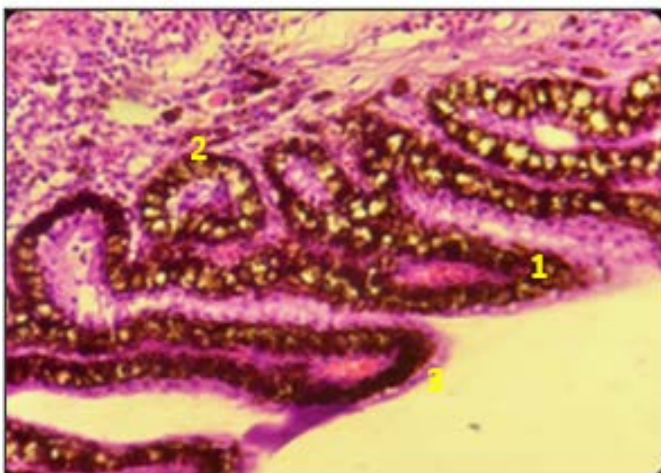
The retina, which is the part that converted light to neurochemical energy, was split into ten layers, as seen in the



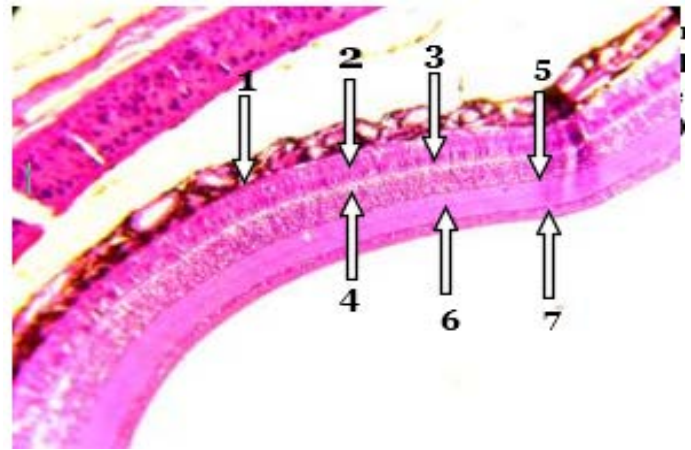
**Figure 5:** Micrographic of eye in duck shows ciliary body:1- Ciliary muscle and 2-pigmented epithelium (H&E stain X400).



**Figure 6:** Micrographic of eye in duck shows lens:1- Simple cuboidal lens epithelium and 2- Differentiating nucleated lens fibers (H&E stain 400X)



**Figure 7:** Micrographic of eye in duck shows ciliary body:1- Ciliary process. 2-Ciliary muscle and 3- Ciliary epithelium (H&E stain 400 X)



**Figure 8:** Micrographic of eye in duck shows:1-Retinal pigment epithelium, 2-Photoreceptors and glial cells (Rod and cone cells), 3- Outer nuclear layer, 4-Outer plexiform layer, 5-Inner nuclear layer, 6-Inner plexiform layer, and 7-Ganglion cell layer (H&E stain 400X).

following. (Figure 8); The first layer was the retinal pigment epithelium. This layer was made of cuboidal cells containing melanin which helps in absorbing light. The second layer was the glial cells and photoreceptors (cones and Rods). This layer is known as “rod and cone cells”. The light sensitivity was higher in rods while the color vision was specialized by cones. The third layer was the outer limiting membrane. This layer was made up of Muller cells and rod/cone junctions. The photosensitive portions of the retina were separated from the sections that sent electrical impulses by the outer limiting membrane. The fourth layer was the outer nuclear layer which was made up of nuclei of cone and rod cells. The fifth outer plexiform layer. Rod and cone cells’ synaptic processes are found in this layer. The inner nuclear layer made the sixth listed layer. Glial, amacrine, bipolar, and horizontal cells have their cell bodies in the inner nuclear layer. The seventh layer was named the inner plexiform layer. Information from cells in the inner nuclear layer is sent through this layer. The ganglion cell layer was the eighth layer. This layer was filled with the nuclei of retinal ganglion cells. The ninth layer was the nerve fiber layer, here, the axons of retinal ganglion cells were found in this layer. The tenth and final layer of the retina was the internal limiting membrane which was a thin layer containing glial cells and a basement membrane.

## DISCUSSION

Numerous studies have indicated that the avian eye’s primary features are comparable to those of other vertebrates, The outer layer of the eye consisted of the transparent cornea at the front, and the sclera, a strong white collagen fiber layer that surrounds the remainder of the eye and supported and protected the eye as a whole. (Mohammed, 2008; Mohammed, 2016; Maria and Erstelt, 2016;

The histological results of this study showed that the sclera layer in the eyes of ducks was composed of several rows of collagen fibers. They differ in thickness from one area to another in the eyeball as they appeared in the form of a thick layer of collagen fibers in the middle of the eye. The histological studies of the eyes have indicated that the sclera of the eye in birds was composed of two layers, the outer layer was represented by the collagen fiber layer, while the interior layer was represented by hyaline cartilage, accord with (Shehan, 2012; Nilsson., 2013).

Epithelium (non-keratinized, stratified squamous epithelium), Bowman layer, stroma (sometimes termed substantia propria), Descemet's membrane, and corneal endothelium were the five layers that make up the cornea. According to (Mohammed, 2008), the central cornea was made up of an epithelial tissue layer that was based on the basal membrane. The epithelial tissue was followed by Bowman's membrane, which was followed by an internal stroma made up of many layers of collagen fibers. The endothelium was lined with a membrane termed the Descemet membrane, which was based on the stroma.

The ciliary body, which was made up of smooth muscles, ciliary process, superciliary process, and pigmented ciliary epithelia, was studied in this work. This result agrees with (Mohammed, 2008; Shehan, 2012).

According to the present study, the iris was made up of two layers: a stroma, which was a pigmented fibrovascular layer, and pigmented epithelial cells, which were beneath the stroma, in conformity with Mohammed (2008).

## RECOMMENDATIONS

We recommend that working on other types of birds to document all similarities and differences between the eye structures of birds. also, we recommend using other techniques that link to different fields.

## ACKNOWLEDGEMENTS

I would like to extend my heartfelt appreciation to [Dr. Thaer Mhalhal], [Dr. Mustafa Saddam], and [Dr. Shereen Jameel] for their invaluable contributions to the data collection process and facilitating the central unite laboratory.

## CONFLICT OF INTEREST

Understanding and analyzing the anatomical and

## NOVELTY STATEMENT

Local ducks considered one of most important birds in Iraq. Since the researches are limited on duck's eyes, we've interested in the anatomical and histological structure of eyes.

## AUTHORS' CONTRIBUTION

Dr. Abbas and Dr. Alhasson worked on the anatomical and histological procession of samples and wrote the manuscript. Mr. Mohsin read the histological slides.

## REFERENCES

- Abed A.A, Abed Al Majeed, S.A. (2010). Anatomical, Histological Study Eye of the Bird Corncrake crexcrex. Journal of Science Rafidain. <https://doi.org/10.33899/rjs.2010.34944>
- Al-Khalefa, E.Kh.H. (2014). Anatomical, histological, and histochemical study of the eye of snake Hemorrhoids ravergeri. Iraqi Journal of Veterinary Sciences. <https://doi.org/10.33899/ijvs.2014.89338>
- Bancroft's J.D., Suvarna S.K., Layton C. (2020). Theory and practice of Histological Techniques. Book. 8th Edition.
- Bharti K.S., Miller H., Arnheite (2010). "The new paradigm: retinal pigment epithelium cells generated from embryonic or induced pluripotent stem cells". Pigment Cell Melanoma Res. <https://doi.org/10.1111/j.1755-148X.2010.00772.x>
- Bharti K. S. Miller, H. Arnheite (2010). "The new paradigm: retinal Comparative Anatomical Study of the Eye in Three Different Birds International J. Scient. Res. Biolog. Sci.
- Chen SY, Terry MA. (2019). Step-by-step Descemet's membrane endothelial keratoplasty surgery. Taiwan J. Ophthal. [https://doi.org/10.4103/tjo.tjo\\_108\\_18](https://doi.org/10.4103/tjo.tjo_108_18)
- Dayan M.O., T. Ozaydin. (2013). A comparative Morphometrical study of the pecten oculi in different Avian Species. Scient. World J. <https://doi.org/10.1155/2013/968652>
- Firas A.A., Thaer R.M., Ali M.A. (2021). Histological and Histomorphometric Study of Retina in Pigeon and Sturnus Vulgaris. Ann. Romanian Societ. Cell Biol.
- Gallego L.V. (2015). Imaging of physiological retinal structures in various raptor species using optical coherence tomography (oct.tiermedizinischenDoktorwürde der TierärztlichenFakultät der Ludwig - Maximilians - UniversitätMünchen.
- Kardong K.V. (2012). Vertebrates Comparative Anatomy, Function, Evolution", 6th ed., McGraw - Hill.
- Luna (1968). Manual of Histological Staining Methods of The Armed Forced Institute of Pathology. 3rd Ed. McGraw Hill Book Co. New York 15-
- Maria Y, Erstellt AM. (2016). Anatomy and function of the eye. www.kinderkrebsinfo.de provides hyperlinks to related websites on the internet.
- Marina I, Brigitha V, Marioara P, Mihai HPMCS, Daniela AI (2020) Photoprotection role of melanin in the human retinal pigment epithelium. Imaging techniques for retinal melanin.

- Romanian, J. Ophthal.
- Mohammed A. Ali. (2008). Anatomical and Histological study of eyes in local buffalos (Bubals bubals). M.sc. Thesis in veterinary anatomy, histology, and embryology. University of Basra, Basra-Iraq.
- Mohammed A. Ali. (2016). Histological and Histo-Morphometric Study of Retina in Pigeon and Duck. Basra J. Vet. Med. <https://doi.org/10.33762/bvetr.2016.124312>
- Neville S, Adrian J. F. K. Craig. (1991). Histological Basis of Age-Related Changes in Iris Color in the African Pied Starling (Spreo bicolor). Auk. J.
- Nilsson D.E (2013). Eye evolution and its functional basis. Vision Neurosci. J. <https://doi.org/10.1017/S0952523813000035>
- Ross M. H., Pawlina W. (2011). Histology a text and atlas with correlated cell and molecular biology, 6th ed., MPS Limited, Macmillan.
- Sanibel A., Abed Almajeed (2010). Anatomical, Histological Study Eye of the Bird Corncrake crexcrex. Rafidain J. Sci. <https://doi.org/10.33899/rjs.2010.34944>
- Schoenemann B., Pärnaste H., Clarkson E.N.K. (2017). Structure and function of a compound eye, more than half a billion years old. Proceedings of the National Academy of Sciences of the United States of America. <https://doi.org/10.1073/pnas.1716824114>
- Shaimaa AA (2016). A Comparative Histological Study of the Retina in the Two Types of Iraqi Vertebrates. International J. Sci. Technol.
- Shehan N.A. (2012). Anatomical and histological study of the eye in local chickens (Gallus domesticus) at Basrah city. AL-Qadisiya J. Vet. Med. Sci.
- Tejus P, Divy M, Patrick H. Le. (2021). Histology, Eye. National Center for Biotechnology Information, U.S. National Library of Medicine 8600 Rockville Pike, Bethesda MD, 20894 USA.
- Zhang G.D.L., Boyle Y., Zhang A.R., Rogers G.W (2012). Conrad, "Development and mineralization of embryonic avian sclera ossicles" Molecula. Vision J.