



Research Article

Predominance of Macular Corneal Dystrophy in Lahore Population

Shagufta Naz*, Saima Sharif, Hafsa Badar, Syeda Fareeha Tauheed

Department of Zoology, Lahore College for Women University Lahore, Pakistan.

Article History

Received: May 18, 2018

Revised: August 25, 2018

Accepted: October 03, 2018

Published: December 04, 2018

Authors' Contributions

SN presented the idea of research. SS did statistical analysis and review of manuscript. HB and SFT collected the data and analysed the results.

Keywords

Macular corneal dystrophy, Corneal dystrophies, Lahore, Cornea.

Abstract | Macular corneal dystrophy (MCD), an autosomal recessive hereditary disease, slowly progresses punctate opacities in the cornea which result in bilateral loss of vision and leads to corneal transplantation. A cross-sectional, analytical study was carried out from August, 2015 to May, 2016 on MCD patients were diagnosed by visiting different hospitals like, General Hospital, Al-Ehsan welfare Hospital, Mughal eye and Mayo Hospital with the help of ophthalmologist. The main purpose of such type of research was directed to find the prevalence of Macular corneal dystrophy in the families of Lahore. The techniques used for the diagnosis of MCD were visual Acuity test by Snellen chart, phoropter, slit lamp biomicroscopy, topography, keratometer and pachymetry. In this study, 50 patients of MCD were identified among which 40 were males and 10 were females, including 9 cases with family history. Main complaint was drop in visual acuity and loss of vision in all patients (100%) due to damage and accumulation of keratan sulfate (KS) in macular layer of corneal stroma. 87% cases have high vision loss and 13% patients have moderate vision loss. MCD were bilateral in all cases (100%). Cases of MCD were observed in all age groups but 40% cases were found in age 21-30 years. IOP was found to be normal in most of the cases and also increases as age increases. Corneal thickness was decreased in 73.8% cases due to accumulation in corneal stroma. Careful clinical evaluation, early diagnosis, genotyping, genetic counseling and proper treatment (corneal grafting) are necessary for the restoration of optimal vision and should be done to avoid the severe outcomes caused by MCD.

To cite this article: Naz, S., Sharif, S., Badar, H. and Tauheed, S.F., 2018. Predominance of macular corneal dystrophy in lahore population. *Punjab Univ. J. Zool.*, 33(2): 161-167. <http://dx.doi.org/10.17582/journal.pujz/2018.33.2.161.167>

Introduction

Human eye is an intricate organ of visual system used to collect information about the environment around us and reacts to light allowing vision (Manoj *et al.*, 2013). Human eye has 3 coverings, encasing 3 clear structures. The outermost layer, called fibrous tunic, comprises of cornea and sclera. The central layer, vascular tunic or uvea, is composed of choroid, ciliary body, and iris. The innermost is the retina. Cornea is bent, translucent and avascular structure that forms the anterior 1/6th of the outer surface of the eye ball (Michelacci, 2003). Transparency of cornea at the front surface of the eye is very important for a clear image on retina.

Histological from anterior to posterior cornea comprised of 5 different layers i.e. Epithelium, Bowman's layer, stroma, Descemet membrane and Endothelium. Any anatomical and physiological variation in cornea leads to loss of transparency to some degree (Sohail *et al.*, 2015). Disease and injury in the cornea are the 2nd most common reason for blindness affecting upto 10 million people through the world (Wilson, 2012). In industrialized countries corneal disease is the cause for less than 2% of blindness in children while in the poorest areas of Africa and Asia this percentage becomes 25-50% of childhood blindness (Garg, 2005).

Corneal dystrophies are characterized as bilateral, non-inflammatory, inherited diseases limited to cornea. Clinically they exist as variably shaped corneal opacities

*Corresponding author: Shagufta Naz
shagufta829@hotmail.com

and there are accretions of different types of deposits in the cornea which may result in blindness. In the starting stage of disease Corneal dystrophies may not affect vision however it can affect vision in advanced stages and that is why proper evaluation, correct diagnosis and treatment are necessary for the restoration of optimal vision (Sohail *et al.*, 2015). Clinically corneal dystrophies are classified into three groups based on structural location of the abnormality. Some affect mainly corneal epithelium and Bowman's layer known as anterior corneal dystrophies (ACDs), the stromal layer known as Stromal corneal dystrophies (SCDs) and Descemet membrane/Corneal endothelium known as Posterior corneal dystrophies (PCDs) (Klintworth, 2009).

Stromal Corneal Dystrophy are classified as Macular corneal dystrophy (MCD), Granular corneal dystrophy (GCD) type 1, Lattice corneal dystrophy (LCD), Schnyder corneal dystrophy (SCD), Fleck corneal dystrophy (FCD), Congenital stromal corneal dystrophy (CSCD) and Posterior amorphous corneal dystrophy (PACD) (Klintworth, 2009). Macular corneal dystrophy (MCD) is a rare but severe stromal corneal dystrophy. Macular corneal dystrophy is an IC3D category 1 dystrophy and it is characterized as autosomal recessive disorders which get arise due to intracellular and extracellular depositions inside the stroma of cornea leading to corneal opacities. These deposits comprise of glycosaminoglycan and resemble keratan sulfate. MCD is less prevalent as compared to granular dystrophy or lattice dystrophy. But there are some regions where higher prevalence of MCD is reported. CHST6 is the gene responsible for macular dystrophy, which locates on chromosome 16 (Mohammad-Rabei, 2012). Three immune-phenotypes of MCD are known as MCD type I, MCD type II and MCD type III: one has no noticeable keratan sulfate (KS) in the serum or cornea, other one has normal amounts of KS in the serum and cornea and a third has no noticeable antigenic keratan sulfate in the serum, but has stainable KS in the keratocytes respectively (Sohail *et al.*, 2015).

A cross-sectional, analytical study was performed between October, 2015 to June, 2016 on MCD patients by visiting, General Hospital, Al-Ehsan welfare Hospital, Mughal eye and Mayo Hospital during their ophthalmic diagnosis. The aim of this research was to identify prevalence of macular corneal dystrophy in Lahore population.

Materials and Methods

With the help of ophthalmologist MCD patients were acknowledged by visiting different hospitals in Lahore. The hospitals visited include Mayo hospital, General Hospital, Al-Ehsan Hospital and Mughal Eye Hospital. Different types of test are used by ophthalmologist to diagnose corneal dystrophies. One method is Snellen's chart

is used most frequently for testing visual acuity in which results are recorded as a fraction. Pachymetry is the process of measuring the thickness of the cornea (Klintworth, 2009). Keratometer, also called ophthalmometer which is used to measure the curvature of the epithelial surface of the cornea, particularly for assessing the level and axis of astigmatism. One more method that is corneal topography is a computer assisted diagnostic tool that convert surface curvature of the cornea in to three dimension map. Perform with preliminary information regarding age, gender, disease status, associated pathologies, family history and contact numbers were distributed and filled out by asking patients of corneal in these hospitals. Hospitals record of the corneal patients was also assessed. The staff of the hospitals was very cooperative and provided a friendly atmosphere. Doctors and staff members provided complete information about macular corneal dystrophy patients and helped us to complete our data.

Variables assessed

Case files of the patients of MCDs were reviewed. The variables examined were:

- Age
- Gender
- Visual acuity
- Intraocular pressure (IOP)
- Bilateral or unilateral
- Corneal thickness

Collected data was compiled and the chi square test was applied to check the prevalence and for comparing different age groups and was regarded significant at $P < 0.05$. The variables which studied were age, gender, main complaint, intraocular pressure, corneal thickness and far visual acuity.

Results

After visiting different hospitals of Lahore, we collected 13000 patients. About 50 cases of macular corneal dystrophies were identified among which 20% (10 cases) were females and 80% (40 cases) were males. One hundred eyes of 50 patients were evaluate; 20 of female and 80 of males. MCD was found to be bilateral in all the patients (100%; 50 cases). The most represented age group was 21-30 which include 40% (20 cases) patients among which 5 (25%) were females and 15 (75%) were males, followed by patient aged 11-20 years including 24% (12 cases), 5 (41.67%) were females and 7 (58.33%) were males. There were 22% (11 cases) patients in age group 31-40 years (100% males) and 14% (7 cases) patients in the age group of 41-50 years (100% male) (Figure 1). No patient was observed having age less than or equal to 10. There were less cases of MCD in large age groups.

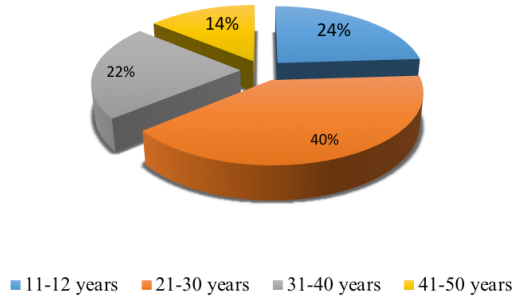


Figure 1: Age distribution of patients with macular corneal dystrophy.

Main complaint was drop in visual acuity and loss of vision which was found in all patients of MCD (100%). From total 50 patients of MCDs pain was observed in the eyes of 39 patients (78%) in which 33 were males and 6 were females. Refractive error was examined in 100 eyes from which 20 eyes were of females and 80 eyes were of males. The most common less refractive error found was 6/60 (22%) in 22 eyes and 6/30 (19%) 19 eyes, HM (13%) 13 eyes and 6/43 (12%) 12 eyes was found. Refractive error or loss of vision was found due to damage and accumulation of material in cornea in MCD patients. Nine patients (18%) of MCD were found to have the dystrophy in family.

Prevalence of visual disability in MCD

There were 100 eyes of MCD patients examined and visual acuity of all the eyes (100%) was recorded. It was observed that most of the patients have blur vision and high vision loss. Moderate vision loss (6/21, 6/23 and 6/24) was recorded in only 13 eyes (13%) out of 100. Rest of the eyes had high vision loss (6/30, 6/36, 6/40, 6/42, 6/43, 6/60, CF and HM) thus was observed in 87 eyes (87%). No patient was found to have normal visual acuity (Figure 2).

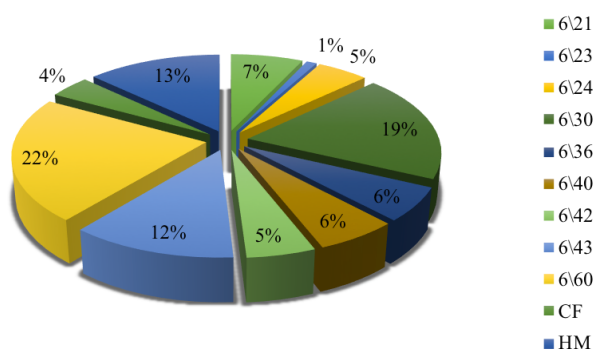


Figure 2: Prevalence of visual disability in 100 eyes of macular corneal dystrophy patients.

Among 13 eyes having moderate vision loss 7 eyes (53.84%) had the visual acuity 6/21, one eye 7.69% had visual acuity 6/23 and 5 eyes (38.46%) had 6/24 visual acuity. Among 87 eyes having high vision loss 19 eyes (21.8%) had 6/30 recording, 6 eyes (6.89%) had 6/36, 6 eyes (6.89%) had 6/40, 5 eyes (5.74%) had 6/42, 12 eyes (13.79%) had 6/43, 22 eyes (25.28%) had 6/60, 4 eyes (4.59%) had CF

and 13 eyes (14.94%) had HM visual acuity.

Visual acuity by gender

Among 100 eyes of MCD, visual acuity was recorded in 20 eyes (20%; 10 cases) of females and 80 eyes (80%, 40 cases) of males. In females, most common least visual acuity was 6/60 and was found in 9 eyes (45%). There were 6 eyes (30%) had visual acuity HM, 2 (10%) eyes had visual acuity 6/21, 2 (10%) eyes had visual acuity 6/43 and one eye (5%) had visual acuity CF (counting finger). In males, most common least visual acuity is 6/30 and was found in 19 eyes (23.75%). About 13 eyes (16.25%) had visual acuity 6/60, 10 eyes (12.5%) had visual acuity 6/43, 7 eyes (8.75%) had visual acuity HM, 6 eyes (7.5%) had visual acuity 6/36, 6 eyes (7.5%) had visual acuity 6/40, 5 eyes (6.25%) had visual acuity 6/21, 5 eyes (6.25%) had visual acuity 6/24, 5 eyes (6.25%) had visual acuity 6/42, 3 eyes (3.75%) had visual acuity CF, and one eye (1.25%) had visual acuity 6/23.

Visual acuity by age

In this study, most representative age group of Visual acuity in MCD was 21-30 years i.e. 40 eyes (40%). 24 eyes (24%) were present in age group 11-20 years, 22 eyes (22%) were found in age group 31-40 years and 14 eyes (14%) were found in 41-50 years age group. Among age group 11-20 years, common visual acuity is 6/60 that is found in 6 eyes (25%), followed by 4 eyes (16%) had visual acuity 6/30, 3 eyes (12.5%) had visual acuity 6/40, 3 eyes (12.5%) had visual 6/43 and 3 eyes (12.5%) had visual acuity HM. Least number of cases (eyes) observed were 2 eyes (8.33%), 2 eyes (8.33%) and one eye (4.17%) having visual acuity 6/21, 6/24 and 6/36 respectively. Among age group 21-30 years most common visual acuity is 6/60 found in 11 eyes out of 40 (27.5%) and least common visual acuity is 6/24 and 6/40, found in 1 eye (2.5%) each. Out of 40 eyes (20%) 8 eyes had visual acuity 6/30. 5 out 40 (12.5%) eyes had visual acuity HM. There were 4 eyes (10%) which had visual acuity 6/21. 3 eyes (7.5%) had visual acuity 6/36 and CF each.

Visual acuity 6/42 and 6/43 were present in each 2 eyes (5%). Among age 31-40 years, most common visual acuity is 6/43 found in 6 out of 22 eyes (27.27%). Least visual acuity recorded was 6/24 (1 eye; 4.54%), HM (1 eye; 4.54%) and CF (1 eye; 4.54%). Visual acuity in 2 eyes (9.09%) was found 6/36 and also 2 eyes (9.09%) had V.A 6/42. Four eyes (18.18%) out of 22 was recorded V.A 6/30. Out of 22 eyes (22.72%) 5 eyes had visual acuity 6/60. Among age 41-50 years, most common visual acuity recorded was HM found in 4 eyes out of 14 (28.57%) and least common visual acuity recorded was 6/21 (1 eye; 7.14%), 6/23 (1 eye; 7.14%), 6/24 (1 eye; 7.14%), 6/41 (1 eye; 7.14%) and 6/42 (1 eye; 7.14%). Visual acuity 6/30 was found in 3 eyes out of 14 (21.43%) and visual acuity 6/40 was recorded in 2 eyes out of 14 (14.29%).

Prevalence of intraocular pressure in MCD

Intraocular Pressure of 100 eyes was recorded from the patients of MCD. Out of 100 eyes, 58 eyes (58%) had normal IOP (10-15 mm Hg), 33 eyes (33%) had mildly high IOP (15-20 mm Hg), 6 eyes (6%) had high IOP (20-25 mm Hg) and only 3 eyes (3%) had extremely high IOP (25-30 mm Hg) (Figure 3).

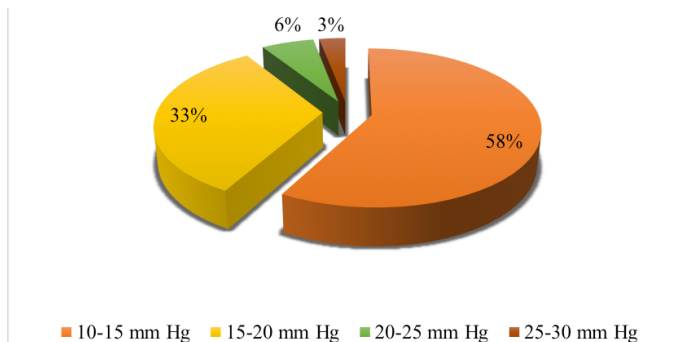


Figure 3: Prevalence of Intraocular Pressure (mm Hg) in 100 eyes of Macular Corneal Dystrophy (MCD) patients

Intraocular pressure by gender

Intraocular Pressure was recorded in 20 eyes of females (10 cases; 20%) and 80 eyes of males (40 cases; 80%). Among females, 13 eyes out of 20 (65%) had normal IOP (10-15 mm Hg), six (n=6) out of 20 eyes (30%) had mildly high IOP (15-20 mm Hg) and only 1 eye out of 20 (5%) had high IOP (20-25 mm Hg). No eye of females was found to have extremely high IOP (25-30 mm Hg). Among males, 45 eyes out of 80 (56.25%) had normal IOP (10-15 mm Hg), 27 out of 80 eyes (33.75%) had mildly high IOP (15-20 mm Hg), 5 eyes out of 80 (6.25%) had high IOP (20-25 mm Hg) and Out of 80 (3.75%) 3 eyes showed extremely high IOP (25-30 mm Hg).

Intraocular pressure by age

Out of 100 eyes studied, 24 eyes were present in age group 11-20 years, among which 16 out of 24 eyes (66.67%) had normal IOP (10-15 mm Hg), Out of 24 eyes (20.83%) 5 eyes had mildly high IOP (15-20 mm Hg), 2 eyes out of 24 (8.33%) had high IOP (20-25 mm Hg) and 1 eye out of 24 (4.17%) was found to have extremely high IOP (25-30 mm Hg). In age group 21-30 years, 23 out of 40 eyes (57.5%) had normal IOP and 17 out of 40 eyes (42.5%) had mildly high IOP (15-20 mm Hg). In age 31-40 years, 12 eyes out of 22 (54.5%) had normal IOP (10-15 mm Hg), 6 out of 22 eyes (27.3%) had mildly high IOP (15-20 mm Hg), Out of 22 (9.1%) 2 eyes had high IOP (20-25 mm Hg) and 2 eyes out of 22 (9.1%) were found to have extremely high IOP (25-30 mm Hg). In age 41-50 years, 7 eyes out of 14 (50%) had normal IOP (10-15 mm Hg), 5 out of 14 eyes (35.7%) had mildly high IOP (15-20 mm Hg), 2 eyes out of 14 (14.3%) had high IOP (20-25 mm Hg).

Prevalence of corneal thickness in MCD

Data for corneal thickness was found in 42 patients in MCD. Normal corneal thickness (500-550 μm) was found in 11 patients (26.2%) out of 42. Moderately less corneal thickness (450-500 μm) was found in 24 patients out of 42 (57.1%). Less Corneal thickness (400-450 μm) was found in 7 patients out of 42 (16.7%).

Corneal thickness by gender

Out of 42 patients whose corneal thickness was found, 6 were females (14.3%) and 36 were males (85.7%). Among females only 1 patient (16.7%) had normal corneal thickness (500-550 μm) and rest of the 5 patients (83.3%) had moderately less corneal thickness (450-500 μm). Among males, 10 patient out of 36 (27.8%) had normal corneal thickness (500-550 μm) and 19 patients out of 36 (52.8%) had moderately less corneal thickness (450-500 μm) and 7 patients out of 36 (19.4%) had less corneal thickness (400-450 μm).

Corneal thickness by age

Out of 42 patients studied for corneal thickness, 8 (19%) patients were found in age group 11-20 years, 18 patients (42.9%) were found in age group 21-30 years, 10 patients (23.8%) were found in age group 31-40 years and 6 patients (14.3%) were found in age group 41-50 years. In age group 11-20 years, 2 out of 8 patients (25%) had normal corneal thickness (500-550 μm), 5 out of 8 patients (62.5%) had moderately less corneal thickness (450-500 μm) and 1 patient out of 8 (12.5%) had less corneal thickness (400-450 μm). In age group 21-30 years, 4 out of 18 patients (22.2%) had normal corneal thickness (500-550 μm), 10 out of 18 patients (55.6%) had moderately less corneal thickness (450-500 μm) and 4 out of 18 patients (22.2%) had less corneal thickness (400-450 μm). In age group 31-40, 3 out of 10 patients (30%) had normal corneal thickness (500-550 μm), 6 out of 10 patients (60%) had moderately less corneal thickness (450-500 μm) and 1 out of 10 patients (10%) had less corneal thickness (400-450 μm). In age group 41-50, 2 out of 6 patients (33.3%) had normal corneal thickness (500-550 μm), 3 out of 6 patients (50%) had moderately less corneal thickness (450-500 μm) and 1 out of 6 patients (16.7%) had less corneal thickness (400-450 μm).

The chi square test was performed to study a comparison between different variables and was assumed significant at $P < 0.05$. The variables analyzed were age, gender, intraocular pressure, corneal thickness and far visual acuity.

Discussion

Human cornea is, a transparent structure having no blood vessels, present at the anterior 1/6th of the outer layer of eyeball. For a clear image the transparency of cornea is very necessary and any defect in cornea will result in loss

of transparency (Sohail *et al.*, 2015). Duke-Elder defined Corneal Dystrophies as “inherited deteriorations of the cornea of unknown etiology occurring bilaterally, revealing themselves occasionally at birth but more frequently during the first or second decades and sometimes later, either stationary or slowly progressive throughout life.” More recently, The American Academy of Ophthalmology define corneal dystrophies as “a group of hereditary corneal diseases that are typically bilateral, symmetric, slowly progressive, and not involving environmental or systemic factors.” A study in USA determined the occurrence of corneal dystrophies as 897 per million (Musch *et al.*, 2011).

In this study, our objective was to determine the incidence of Macular Corneal Dystrophy, a type of stromal corneal dystrophies. SCDs are a group of transmissible diseases of the cornea that are developed by progressive depositions within the stromal layer. They are not caused by swelling, infection, or trauma, they are just caused by inherited changes that results in abnormal proteins due to which accumulation of insoluble material within the stroma occurs (Bron, 2009). MCD, autosomal recessive disease, which is developed due to change in carbohydrate sulfotransferase 6 gene (CHST6) positioned on chromosome number 16 that becomes the reason for alteration in the synthesis of keratan sulfate, which is the major glycosaminoglycan of the cornea (Al-Sawailem, 2005). In our study, we observed 50 patients of Macular Corneal Dystrophy (MCD) out of which 80% were males and 20% were females. Thus, MCD is prevailed in males in our study and it results in bilateral loss of vision. In this study, we also found MCD to be 100% bilateral i.e. both eyes are affected in all patients of MCD (Akama *et al.*, 2000).

Predominance of Macular Corneal Dystrophy is not known. Instances of MCD have been distinguished around the world. This state is most normal in India, Saudi Arabia, Iceland and some regions of the USA (Klintworth, 2006). Despite the fact that MCD is less normal throughout the world than LCD or GCD, it is the most well-known of the corneal stromal dystrophies in spots, for example, Iceland and Saudi Arabia (Wiess *et al.*, 2015). Klintworth (2006) has registration of people with macular corneal dystrophy in the United States for a long time. His registry contains families, pedigrees and other data on around 200 influenced people from more than 100 families with this condition. This relates to 0.3 people for each 250,000 tenants, similar figure for Denmark is 0.512 and 19 for Iceland. In another study, sign for high predominance of macular corneal dystrophy in Iceland is the fact that about each third corneal graft performed on Icelanders amid the 15 year time of study was done because of macular corneal dystrophy (Jonasson *et al.*, 1989).

Macular Corneal Dystrophy (MCD) is slowly progressive disease with increasing corneal cloudiness

throughout life (Cheng *et al.*, 2012). In adolescence, opacities usually first appear but may become apparent anytime from the time of early infancy to the sixth decade of life. In MCD, opacities usually first become evident in both corneas at age of puberty. Initially irregular, ill-defined areas of diffuse clouding appear in the central cornea. With time, they progressively become affluent and hence involve the entire corneal stroma (Klintworth and Smith, 1977). In our study, MCD has been observed in different age groups but it is more prevalent in age group 21-30 (40%). In age group 11-20, 24% patients of MCD have been observed. 22% patients have been observed in age group 31-40 and 14% patients in age group 41-50.

Visual acuity is the power to distinguish one object from the other. It has been reported in different studies that MCD tend to impact vision more severely than other types of stromal corneal dystrophies and results in vision loss (Al-Sawailem *et al.*, 2005). Usually before the fifth decade of life the disease culminates in severe visual impairment. Vision can be restored by corneal grafting (Klintworth and Smith, 1977). In our study also no patient has observed with normal visual acuity. We observed 100 eyes in this study and have found 87% eyes with high vision loss and thus severe impact on vision due to MCD. Vision of rest of 13% eyes has been also affected but at a moderate level. Intraocular pressure (IOP) is the pressure of fluid within the eye. Tonometry is the ophthalmic technique used to determine this. It is measured in millimeters of mercury (mmHg). IOP also vary in patients of MCD (Henderer *et al.*, 1999). Normal IOP ranges from 10-15 mm Hg. In our study, we observed IOP of 100 eyes and most of them (58%) have normal IOP range. 33% eyes have been observed with mildly high IOP (15-20 mm Hg). 6% eyes have high IOP (20-25 mm Hg) and only small number i.e. 3% (3 eyes) have extremely high IOP (25-30 mm Hg).

Corneal Thickness is checked with a device called a pachymeter (Eisner and Israel, 2006). In MCD, the corneal stroma is thinner than normal (Klintworth, 2009). The cornea is thin as the disorder progresses (Bron, 2000). In this study, we also observe decrease in corneal thickness due to MCD. 73.8% patients have been observed with decrease corneal thickness. In our study, we observed data of 42 patients. Normal corneal thickness ranges from 500-550 μm . In this study normal corneal thickness was found only in 11 patients (26.2%). Moderately less corneal thickness (450-500 μm) was found in 24 patients out of 42 (57.1%) and less corneal thickness (400-450 μm) was found in 7 patients out of 42 (16.7%). It has been observed that corneal thickness decreases as the age increases. Decrease of corneal thickness is more prevalent in age group 21-30 years (14 out of 42 patients).

In conclusion, the present study of MCD shows that

it is a genetic disorder that leads to the accumulation of KS deposits in corneal stroma resulting in blur vision or complete vision loss and predominates in males as compared to females in Lahore population. This study also shows that MCD is rare in Lahore city of Pakistan. IOP tends to vary in patients of MCD and corneal thickness decreases in most of the patients due to decrease in inter-fibrillar spacing in collagen fibrils. Genetic counseling is something to consider for any serious inherited medical disorder. Macular corneal dystrophy has an autosomal recessive mode of inheritance, so it follows that both carrier parents will have a 25% chance of affected children. This type of information is obviously very critical and also the severity of the disease expression can vary for each individual affected. Once patients with MCD are identified, risk to family members can be established. This counseling relies on an exact diagnosis, findings of the mode of inheritance in each family and results of molecular genetic testing. This type of testing allows for individuals and families with knowledge, the type of inheritance and signifies the genetic disorder to help them make informed medical and personal decision. Most of the population in Lahore city Pakistan is unaware about Macular Corneal Dystrophy thus genetic counseling is advisable among families who carry MCD trait (Blain and Brooks, 2007).

Acknowledgments

We sincerely thank Macular corneal dystrophy patients and the staff of, General Hospital, Al-Ehsan welfare Hospital, Mughal eye and Mayo Hospital for their assistance in the clinical evaluation and collection of data.

References

- Akama, T.O., Nishida, K., Nakayama, J., Watanabe, H., Ozaki, K., Nakamura, T., Dota, A., Kawasaki, S., Inoue, Y., Maeda, N. and Yamamoto, S., 2000. Macular corneal dystrophy type I and type II are caused by distinct mutations in a new sulphotransferase gene. *Nat. Gen.*, **26**: 237. <https://doi.org/10.1038/79987>
- Al-Swailem, S.A., Al-Rajhi, A.A. and Wagoner, M.D., 2005. Penetrating keratoplasty for macular corneal dystrophy. *Ophthalmology*, **112**: 220-224. <https://doi.org/10.1016/j.ophtha.2004.08.017>
- Blain, D. and Brooks, B.P., 2007. Molecular diagnosis and genetic counseling in ophthalmology. *Arch. Ophthalmol.*, **125**: 196-203. <https://doi.org/10.1001/archophth.125.2.196>
- Bron, A.J., 2000. Genetics of the corneal dystrophies: What we have learned in the past twenty-five years. *Cornea*, **19**: 699-711. <https://doi.org/10.1097/00003226-200009000-00015>
- Cheng, J., Qi, X., Zhao, J., Zhai, H. and Xie, L., 2013. Comparison of penetrating keratoplasty and deep lamellar keratoplasty for macular corneal dystrophy and risk factors of recurrence. *Ophthalmology*, **120**: 34-39. <https://doi.org/10.1016/j.ophtha.2012.07.037>
- Eisner, R. and Israel, R., 2006. Corneal waveform measurements have advantages in pachymetry. *Ocular Surg. News*, **24**: 21.
- Garg, P., Krishna, P.V., Stratis, A.K. and Gopinathan, U., 2005. The value of corneal transplantation in reducing blindness. *Eye*, **19**: 1106. <https://doi.org/10.1038/sj.eye.6701968>
- Henderer, J.D., Budenz, D.L., Flynn, H.W., Schiffman, J.C., Feuer, W.J. and Murray, T.G., 1999. Elevated intraocular pressure and hypotony following silicone oil retinal tamponade for complex retinal detachment: incidence and risk factors. *Arch. Ophthalmol.*, **117**: 189-195. <https://doi.org/10.1001/archophth.117.2.189>
- Jonasson, F., Johannsson, J.H., Garner, A. and Rice, N.S.C., 1989. Macular corneal dystrophy in Iceland. *Eye*, **3**: 446. <https://doi.org/10.1038/eye.1989.66>
- Klintworth, G.K. and Smith, C.F., 1977. Macular corneal dystrophy: Studies of sulfated glycosaminoglycans in corneal explant and confluent stromal cell cultures. *Am. J. Pathol.*, **89**: 167.
- Klintworth, G.K., 2009. Corneal dystrophies. *Orphan. J. Rare Dis.*, **4**: 7. <https://doi.org/10.1186/1750-1172-4-7>
- Klintworth, G.K., Smith, C.F. and Bowling, B.L., 2006. CHST6 mutations in North American subjects with macular corneal dystrophy: a comprehensive molecular genetic review. *Mol. Vis.*, **12**: 159-76.
- Kumar, M., Agarwal, T., Kaur, P., Kumar, M., Khokhar, S. and Dada, R., 2013. Molecular and structural analysis of genetic variations in congenital cataract. *Mol. Vision*, **19**: 2436.
- Manoj, K., Punit, K., Sudarshan, K. and Rima, D., 2013. Molecular and structural analysis of genetic variations in congenital cataract. *Mol. Vision*, **19**: 2436-2450.
- Michelacci, Y.M., 2003. Collagens and proteoglycans of the corneal extracellular matrix
- x. *Brazil. J. Med. Biol. Res.*, **36**: 1037-1046. <https://doi.org/10.1590/S0100-879X2003000800009>
- Mohammad-Rabei, H., Shojaei, A. and Aslani, M., 2012. Concurrent macular corneal dystrophy and keratoconus. *Middle East Africa. J. Ophthalmol.*, **19**: 251. <https://doi.org/10.4103/0974-9233.95266>
- Musch, D.C., Niziol, L.M., Stein, J.D., Kamyar, R.M. and Sugar, A., 2011. Prevalence of corneal dystrophies in the United States: estimates from claims data. *Invest. Ophthalmol. Visual Sci.*, **52**: 6959-6963. <https://doi.org/10.1167/iovs.11-7771>
- Sohail, I., Noreen, F., Nawaz, S., Ahmed, S., Zafar, H. and Niaz, M., 2015. Frequency of corneal dystrophies on the basis of histopathology in surgically removed corneas. *J. Pak. Med. Assoc.*, **65**: 1056-1059.

- Weiss, J.S., Møller, H.U., Aldave, A.J., Seitz, B., Bredrup, C., Kivelä, T., Munier, F.L., Rapuano, C.J., Nischal, K.K., Kim, E.K. and Sutphin, J., 2015. IC3D classification of corneal dystrophies—edition 2. *Cornea*, **34**: 117-159. <https://doi.org/10.1097/ICO.0000000000000307>
- Wilson, S.L., El Haj, A.J. and Yang, Y., 2012. Control of scar tissue formation in the cornea: Strategies in clinical and corneal tissue engineering. *J. Fun. Biomat.*, **3**: 642-687. <https://doi.org/10.3390/jfb3030642>