



Clinical Effect of Apatinib Combined with Trastuzumab on Gastric Cancer with Ascites

Xiaowei Zhang*

Medical Oncology, Baoding No.1 Central Hospital, Baoding, 071000, China

ABSTRACT

The objective of this study was to investigate the effect of two chemotherapeutic drugs, apatinib and trastuzumab, on gastric cancer with ascites. 225 patients with gastric cancer and ascites received by the Oncology Department and Gastrointestinal Department of the Central Hospital during October 2019-2021 were selected. They were subsequently assigned into apatinib group, trastuzumab group and combined treatment group. Compared with other treatment groups, the long-term and short-term survival rate of the apatinib treatment group was lower. The effective rate and adverse reaction rate of the three therapeutic drug intervention groups were significantly different. The correlation between survival time and CEA, CA125, CA19-9 tumor markers was 0.611, 0.603, 0.598, respectively, and all were significant. It was concluded that the combined treatment group of apatinib and trastuzumab can effectively intervene gastric cancer with ascites disease, reduce postoperative adverse reactions, promote cell apoptosis, especially the survival rate of long-term and short-term patients.

Article Information

Received 23 December 2022

Revised 25 January 2023

Accepted 26 February 2023

Available online 10 April 2023
(early access)

Published 13 June 2024

Key words

Apatinib, Trastuzumab, Gastric cancer, Ascites, Clinical efficacy

INTRODUCTION

As one of the cancers threatening human health, the incidence rate and mortality of gastric cancer rank first (Amani *et al.*, 2021). The occurrence of this disease poses a dominant risk to the physical and mental health and life and property of patients. The occurrence of this disease will cause serious psychological problems for patients, and will also threaten the lives of patients. Patients with early gastric cancer rarely show no obvious symptoms. Usually, when they go to the hospital for diagnosis, the disease progresses to the middle and late stages, which causes them to miss the best operation time and are forced to choose chemotherapy. However, the chemotherapy treatment scheme lasts for a long time. At the same time, the basic chemotherapy usually shows drug resistance. The antineoplastic drugs used will produce drug resistance in the process of cancer cell elimination, thereby reducing the immune capacity of the body, thus causing adverse reactions (Hu *et al.*, 2019; Eum *et al.*, 2020). Gastric cancer with ascites refers to ascites caused by malignant tumor

involving peritoneum, which can be regarded as advanced gastric cancer (Hamamoto *et al.*, 2020; Suzuki *et al.*, 2021). As a new small molecule targeted drug, apatinib has a good inhibitory effect on the vascular endothelial growth factor formation, and has good safety, targeting and tolerance (Zhou *et al.*, 2021; Yang *et al.*, 2020). Trastuzumab can affect cell proliferation through the function of human epidermal growth factor-2 receptor, and this effect is to hinder cell growth (Wang *et al.*, 2019; Chung *et al.*, 2021). But at present, there is almost no research on apatinib combined with trastuzumab on this disease with ascites in clinical practice. The research has conducted in-depth analysis on this, aiming to bring a new combined drug scheme for the disease with ascites.

MATERIALS AND METHODS

The sample

Two hundred and twenty-five patients with gastric cancer and ascites received by the oncology department and gastrointestinal department of the central hospital from October 2019 to October 2021 were selected and subsequently assigned into apatinib group, trastuzumab group and combined treatment group, with 75 patients in each group. Patients with gastric cancer and ascites in all three groups were eligible to join the study if they met the following inclusion criteria: All subjects were diagnosed as gastric cancer by cytology and pathology, tumor node metastasis (TNM) was classified as stage IV, no allergic reaction to the drugs used, there was no chemotherapy or radiotherapy before the initial onset, and the patient

* Corresponding author: zhangxiaowei202211@163.com
0030-9923/2024/0004-1853 \$ 9.00/0



Copyright 2024 by the authors. Licensee Zoological Society of Pakistan.

This article is an open access article distributed under the terms and conditions of the Creative Commons Attribution (CC BY) license (<https://creativecommons.org/licenses/by/4.0/>).

did not have corresponding contraindications, complete clinical data, the patients were followed up for more than 2 chemotherapy cycles. Patients with a dysfunction of important organs, other malignant tumors, life cycle less than 3 months, having mental illness or coagulation dysfunction, actively participating in other drug trials were excluded from the study groups. Patients could withdraw from this research at any point without prejudice to their care. All the subjects signed the informed consent form on an equal and voluntary basis.

The treatment

Apatinib group was treated with apatinib, which originated from Jiangsu Hengrui Pharmaceutical Co., Ltd. with the registered batch number of National Drug Approval No. H2010105. The drug was orally administered 500mg each day, and the treatment was conducted once a week after continuous treatment. Trastuzumab group was treated with chemotherapy drugs of trastuzumab, which came from American Gene Technology Company with registered batch number of S20060026. The first dose was 8 mg/kg, the maintenance dose was 6 mg/kg, and the duration of intravenous drip was 1 day. In the combined treatment group, additional antipatinib chemotherapy drugs were added. The whole study lasted for 8 weeks. All patients need to be given dexamethasone and 5-hydroxytryptamine receptor antagonist for antiemetic treatment during chemotherapy. At the same time, the discomfort of patients during chemotherapy was observed and recorded.

Measures

Gastric cells were respectively extracted from four populations, i.e., a normal group, a trastuzumab group, an apatinib group and a combination treatment group, which were all healthy after physical examination. Cells were obtained from Dulbecco's Modified Eagle Medium; DMEM) and cultured in a 37°C incubator and 5% CO₂ until log phase, while cells were adjusted to 1 x 10⁵ cells/ml with 0.25% trypsin. Cell Counting Kit-8 (CCK-8) from Beijing Wobson Technology Co., Ltd was adopted to test cell proliferation.

After the experiment, the levels of serum tumor markers, efficacy, cell growth and apoptosis, quality of life, and adverse reactions. Tumor markers were carcinoembryonic antigen (CEA), carbohydrate antigen 19-9 (CA19-9), carbohydrate antigen 125 (CA125). The detection method was electrochemiluminescence. The efficacy evaluation was divided into progression (PD), stability (SD), partial remission (PR), and complete remission (CR), representing 20% increase or presence of lesions, the increase interval of lesions in PR and PD, the

reduction of the length of lesions at PR baseline by 30%, and the disappearance of all target lesions.

Statistical analyses

The data analysis software used in the study is the latest version of SPSS23.0. The test method between two groups is a non-parametric test method, and the test method for multiple group data is the Kruskal Wallis test method. If the measurement data follow a normal distribution, it must be expressed as a comparison between two groups by inspection, a comparison between several groups by one-way ANOVA, and data at different time points. scores are analyzed by repeated measures ANOVA; If it is not according to normal distribution, it is expressed by quartile, and the difference analysis method between groups is a non-parametric expression; The Kruskal Wallis test was hired when comparing groups.

RESULTS

Table I shows the basic information of the four groups of subjects. The basic disease, course of disease, surgical site, tumor classification, etc. of the four groups of subjects had statistical significance ($P < 0.05$). No statistical significance was confirmed ($P > 0.05$).

Figure 1 shows the effects of the three groups. The effective rates of apatinib group, trastuzumab group and combined treatment group were 64.00%, 72.00% and 80.00%, respectively, the effective rates of the three groups were significant ($P < 0.05$). After starting to take chemotherapy drugs, the treatment efficiency was assessed, and the values of trastuzumab group and the combined antipatinib group were lower ($P < 0.05$). At the same time, apatinib group's value was significantly higher than trastuzumab group's value.

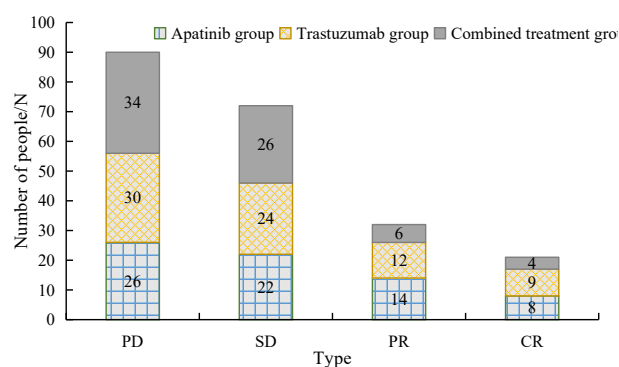


Fig. 1. Analysis and comparison of therapeutic effects of three groups of patients.

PD, progressive disease; SD, stable disease; PR, partial response; CR, complete response.

Table I. Basic information about the group of subjects.

Category	Normal group	Apatinib group	Trastuzumab group	Combined treatment group	F value	P value
Male/female (n)	34/41	35/40	38/37	37/38	0.832	0.456
Age	52.26±10.58	55.32±9.52	52.26±10.58	53.26±9.68	0.702	0.654
Course of disease/year	0	2.62±0.37	2.56±0.53	2.46±0.41	8.256	0.040
BMI (kg/m ²)	22.23±3.26	23.20±1.91	22.23±3.26	23.01±2.86	1.231	0.098
Basic diseases	0	27	29	24	8.365	0.043
Proximal gastric surgery	0	27	24	26	11.232	0.007
Distal surgery	0	25	26	24		
Total stomach surgery	0	23	25	25		
Adenocarcinoma	0	29	27	26	9.256	0.030
Mucinous carcinoma	0	24	24	25		
Undifferentiated carcinoma	0	22	24	24		

Figure 2 shows the OS (overall survival), DFS (progression-free survival), LC (local control) survival curves at 3 years, respectively. For the OS survival curve, the OS rates in the 1-,2- and 3-year-old patients of the antipathine group were 75.3%, 40.8% and 40.8%, respectively. The PFS rate was 75.8%, 35.8%, and 35.8%, respectively, and the LC rate was 74.2%, 42.1%, and 42.1%, respectively. The corresponding values were significantly lower than the other two groups' value ($P<0.05$). In the trastuzumab group, the OS rates in 1, 2, and 3 years were 78.2%, 47.6%, and 47.6%, respectively. The PFS rate was 77.2%, 39.5%, and 39.5%, respectively, and the LC rate was 76.8%, 48.6%, and 48.6%, respectively. The OS rates in the combined treatment group in one, two and three years were 87.6%, 54.6% and 54.6%, respectively. The PFS rate was 89.6%, 47.5%, and 47.5%, respectively, and the LC rate was 88.6%, 50.3%, and 50.3%, respectively.

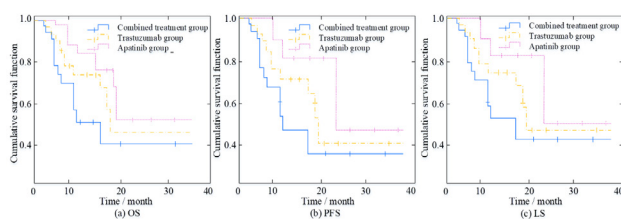


Fig. 2. Survival curves at 3 years, (a) OS, overall survival; (b) PFS, progression-free survival; (c) LC, local control.

In order to further verify the correlation between survival time and three tumor marker levels, Figure 3 show the correlation between survival time of three groups and three tumor marker levels. Different icons in the figure represent different groups of study samples. The correlation between survival time and CEA, CA125, CA19-9 tumor markers was 0.611, 0.603, 0.598, respectively, and all were significant ($P<0.05$).

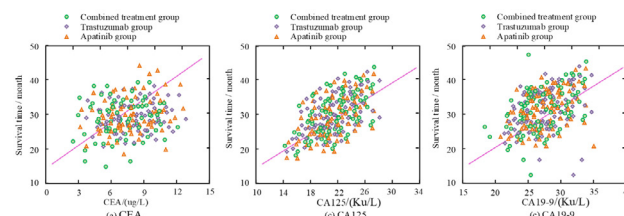


Fig. 3. Correlation of survival time with CEA, CA125, CA19-9 tumor markers in three groups.

Table II shows the adverse reactions of the patients in the three groups. The overall incidence of adverse reactions in the apatinib group, the trastuzumab group, and the combination treatment group were (29/75) 38.67%, (22/75) 29.33%, (14/75) 18.67%, respectively. The incidence among those groups was statistically significant after starting to take chemotherapy drugs ($P<0.05$). After starting to take chemotherapy drugs, the index was compared with the single drug group, and the values of trastuzumab group and the combined antipatinib group were higher ($P<0.05$). At the same time, apatinib groups corresponding value was lower than trastuzumab groups value ($P<0.05$).

Table II. Adverse reactions (n%).

Outcomes	Apatinib group	Trastuzumab group	Combined treatment group
Vertigo	6(8.00)	5(6.67)	4(5.33)
Fever	6(8.00)	4(5.33)	3(4.00)
Cardiotoxicity	2(2.67)	33(4.00)	0(0.00)
Diarrhea	4(5.33)	2(2.67)	0(0.00)
Vomit	2(2.67)	1(1.33)	1(1.33)
Renal dysfunction	4(5.33)	3(4.00)	3(4.00)
Abnormal liver function	5(6.67)	4(5.33)	3(4.00)

DISCUSSION

The effect of antiangiogenic therapy at this stage is not particularly satisfactory. In most cases, it is combined with chemotherapy. Yang and other researchers found that the main pathological feature of malignant tumors is neonatal angiogenesis, which can provide a lot of nutrients for tumor growth, thereby promoting tumor cell proliferation and metastasis (Yang *et al.*, 2022). Honda *et al.* (2020) studied gastric adenocarcinoma patients with ascites, and analyzed the connection between ascites grading and survival time by establishing a grading evaluation system. Tanaka *et al.* (2021) in view of the fact that peritoneal metastasis of gastric cancer is a marker of advanced gastric cancer, identified genes through multiple histone characteristics and targeted therapy. The research results gave two different molecular subtypes, which inhibit gene expression through pathways. Apatinib is an oral angiogenesis inhibitor. It binds to the angiogenic factor receptor 2 in a competitive way to block the proliferation and inhibition of tumor cells (Xu *et al.*, 2021). Afatinib has an anti-angiogenesis and anti-cancer role by inducing apoptosis, inhibiting proliferation and metastasis and other mechanisms. Zhao *et al.* (2021) analyzed the inhibitory effect of apatinib on gastric cancer by immunohistochemistry and microarray analysis and confirmed that apatinib can reduce glutathione overexpression by inhibiting the transcription factor sterol regulatory element-binding protein 1a. Oxidase expression and its effects on cell viability, cell death, glutathione level and protein expression. Most chemotherapy drugs can cause immune stimulation, which has been confirmed in preclinical studies (Peng *et al.*, 2021).

Trastuzumab, as a monoclonal antibody drug targeting Her-2 protein, has outstanding advantages in blocking cardiovascular formation (Kim *et al.*, 2019; Nagata *et al.*, 2020; Zhou *et al.*, 2019). However, the treatment effect of a single chemotherapy drug is not particularly ideal, and the adverse reactions shown in the late treatment period are relatively serious. Therefore, chemotherapy drugs generally play a synergistic role with other drugs. Tumor markers CEA, CA125, CA19-9 are specific manifestations of activity. They mainly exist in the serum as mucin, but the level will change according to the patient's condition, which has important value in the process of disease diagnosis and evaluation. As a kind of acid glycoprotein, CA125 contains clusters generated by human embryonic characteristics, which can predict the invasion and metastasis of cancer cells. Before treatment, the tumor marker level and QLQ-C30 score of the three groups had no statistical significance. After treatment, for the single treatment group, the effective rate of the combined treatment group was significantly higher, while

for the afatinib group, the effective rate of the trastuzumab group was higher ($P < 0.05$). Thus, combination therapy has a positive influence, can significantly reduce the level of tumor markers, and also has a certain role in enhancing the patients' life quality. This may be that apatinib can specifically bind to tyrosine in the receptor cells, thereby inhibiting the growth of vascular endothelial cells, thereby inhibiting tumor growth (Jia *et al.*, 2019; Zhang *et al.*, 2020; Ma *et al.*, 2020). Jia *et al.* (2019) have analyzed the mechanism of action of apatinib in treating gastric cancer, and the research results show that the drug can induce the expression of apoptosis promoting genes. At the same time, as a targeted therapeutic drug, this drug is the first anti angiogenic drug in China. The drug is administered orally and has the characteristics of high efficiency and accuracy in disease treatment. China is a high incidence area of gastric cancer, which is about twice the global average level. It is often found to be in the middle and late stages. The mechanism of this disease is complex, which is not only related to abnormal proliferation and apoptosis, but also closely related to autophagy. Autophagy is a process that maintains the normal physiological function of cells, promotes DNA damage repair, regulates malignant tumor metastasis, and then highly precisely regulates tumor formation. As an inflammatory factor in the tumor microenvironment, IL-32 is important for regulating the acts of tumors. However, whether it affects such phenomena through autophagy remains to be explored. Studies showed that IL-32 is highly expressed in lung, colorectal, liver, gastric and esophageal cancer, but whether its specific mechanism is related to autophagy is still unclear. Inflammation and autophagy are related to the pathogenesis of malignant tumors. Moderate autophagy is important role for energy metabolism, immune regulation and cell differentiation. Autophagy disorder can lead to cell nutrient deficiency and failure to perform normal physiological functions, thus accelerating cell death.

Further study found that there was statistical significance in the inhibition of cell proliferation, apoptosis and Bax protein expression in the three treatment groups. This also reflects the synergistic effect of trastuzumab combined with apatinib in the treatment of tumors. This may be because the inhibitory effect of trastuzumab targeted therapy drugs on Her-2 protein may not be able to prevent angiogenesis mediated by angiogenic factors, and may even cause the activation of alternative angiogenesis pathways, while combined drug therapy can effectively enhance their inhibition on angiogenesis, thus leading to apoptosis of gastric cancer cells (Kim *et al.*, 2021; Shitara *et al.*, 2021). At the same time, studies have also shown that combination therapy drugs can reduce the expression of the anti-apoptotic gene Bcl and the growth-regulating

gene Her-2 in gastric cancer cells, and can also increase the expression of the apoptotic gene Bax (Komatso *et al.*, 2022; Schade *et al.*, 2022). The treatment effect and the total incidence of adverse effects in the three groups were statistically significant. According to the research literature, adverse effects after antitumor chemotherapy include diarrhea, fatigue, congestion, hand-foot syndrome, anorexia, granulocytopenia, thrombocytopenia, and leukopenia (Chongqing, 2020; Lu *et al.*, 2017; Li *et al.*, 2021). Liu (2020) also pointed out that, compared with the treatment of single drug, combined chemotherapy drugs have higher therapeutic effect, can improve the disease control effect and appropriately prolong the survival time of patients, but the measurement time may be longer (Liu *et al.*, 2020). At present, there is no effective treatment plan for gastric cancer with ascites at home and abroad, and the treatment methods are quite different. Although many studies have conducted many experimental tests on different types of treatment methods, few studies have mentioned the comparative analysis of treatment schemes (Liu *et al.*, 2020). The follow-up time was 1 year, 2 years and 3 years. The OS rate in the apatinib group was 75.3%, 40.8% and 40.8% respectively. The PFS rate was 75.8%, 35.8% and 35.8% respectively, and the LC rate was 74.2%, 42.1% and 42.1% respectively.

CONCLUSION

It can be concluded that the levels of the three tumor markers and the survival time of gastric cancer patients shows a high correlation. However, due to the sample size is limited, the study has some limitations. According to the research results at home and abroad, the combination of apatinib and trastuzumab is greatly valuable for the clinical treatment of gastric cancer with ascites. This treatment can decrease the incidence of toxic and side effects, and enhance the life quality of patients to a large extent, reduce the adverse reactions of patients after treatment, and thus help gastric cancer patients get effective treatment.

ACKNOWLEDGMENTS

The author gratefully acknowledges scientific assistance from Baoding No.1 Central Hospital. The support of Baoding No.1 Central Hospital for statistical analysis is highly acknowledged.

Funding

Not applicable.

IRB approval

This study was approved by the Advanced Studies

Research Board of Baoding No.1 Central Hospital, Baoding, 071000, China.

Ethical approval

The study was carried out in compliance with guidelines issued by ethical review board and institutional biosafety committee of Baoding No.1 Central Hospital. The official letter would be available on fair request to corresponding author.

Statement of conflict of interest

The authors have declared no conflict of interest.

REFERENCES

- Amani, N., Shariati, M., Ahmadi, R., Mokhtari, M. and Khatamsaz, S., 2021. Testosterone enanthate induces cell death in human colon (HCT) and gastric (AGS) cancer cells. *Pakistan J. Zool.*, **54**: 1153-1161. <https://doi.org/10.17582/journal.pjz/20201013081036>
- Chongqing, C., 2020. Adverse events and management of apatinib in patients with advanced or metastatic cancers: A review. *Neoplasma*, **67**: 715-723. https://doi.org/10.4149/neo_2020_190801N701
- Chung, H.C., Bang, Y.J., S Fuchs, C., Qin, S.K., Satoh, T., Shitara, K., Tabernero, J., Van Cutsem, E., Alsina, M., Cao, Z.A. and Lu, J., 2021. First-line pembrolizumab/placebo plus trastuzumab and chemotherapy in HER2-positive advanced gastric cancer: KEYNOTE-811. *Future Oncol.*, **17**: 491-501. <https://doi.org/10.2217/fon-2020-0737>
- Eum, H.H., Kwon, M., Ryu, D., Jo, A., Chung, W., Kim, N., Hong, Y., Son, D.S., Kim, S.T., Lee, J. and Lee, H.O., 2020. Tumor-promoting macrophages prevail in malignant ascites of advanced gastric cancer. *Exp. mol. Med.*, **52**: 1976-1988. <https://doi.org/10.1038/s12276-020-00538-y>
- Hamamoto, Y., Piao, Y. and Makiyama, A., 2020. Achieving sequential therapy in advanced gastric cancer: The importance of appropriate patient management for the elderly and/or those with ascites. *Gastric Cancer*, **23**: 363-372. <https://doi.org/10.1007/s10120-020-01067-3>
- Honda, M., Kawamura, H., Kobayashi, H., Takiguchi, K., Muto, A., Yamazaki, S., Teranishi, Y., Shiraso, S., Kono, K., Hori, S. and Kamiga, T., 2020. An ascites grading system for predicting the prognosis of gastric cancer with peritoneum dissemination. *Anns. Gastroenterol. Surg.*, **4**: 660-666. <https://doi.org/10.1002/ags3.12386>
- Hu, Y., Qi, C., Liu, X., Zhang, C., Gao, J., Wu, Y.,

- Yang, J., Zhao, Q., Li, J., Wang, X. and Shen, L., 2019. Malignant ascites-derived exosomes promote peritoneal tumor cell dissemination and reveal a distinct miRNA signature in advanced gastric cancer. *Cancer Let.*, **457**: 142-150. <https://doi.org/10.1016/j.canlet.2019.04.034>
- Jia, X., Wen, Z., Sun, Q., Zhao, X., Yang, H., Shi, X. and Xin, T., 2019. Apatinib suppresses the proliferation and apoptosis of gastric cancer cells via the PI3K/Akt signaling pathway. *J. Buon.*, **24**:1985-1991. PMID: 31786865.
- Kim, H., Son, S.M., Woo, C.G., Lee, O.J., Kim, D.H., Yun, H.Y., Yun, J., Kim, H.K., Yang, Y., and Han, H.S., 2019. Discordance in HER2 status between primary gastric adenocarcinoma tumors and cells from the corresponding malignant effusions. *BMC Cancer*, **19**: 1-9. <https://doi.org/10.1186/s12885-019-6035-0>
- Kim, T.H., Do Cho, H., Choi, Y.W., Lee, H.W., Kang, S.Y., Jeong, G.S., Choi, J.H., Ahn, M.S. and Sheen, S.S., 2021. Trastuzumab-based palliative chemotherapy for HER2-positive gastric cancer: A single-center real-world data. *BMC Cancer*, **21**: 1-8. <https://doi.org/10.1186/s12885-021-08058-2>
- Komatsu, Y., Hironaka, S., Tanizawa, Y., Cai, Z., Piao, Y. and Boku, N., 2022. Treatment pattern for advanced gastric cancer in Japan and factors associated with sequential treatment: A retrospective administrative claims database study. *Adv. Ther.*, **39**: 296-313. <https://doi.org/10.1007/s12325-021-01931-3>
- Li, Z., Liu, Z., Wu, Y., Li, H., Sun, Z., Han, C., Zhang, X. and Zhang, J., 2021. Efficacy and safety of apatinib alone or apatinib plus paclitaxel/docetaxel versus paclitaxel/docetaxel in the treatment of advanced non-small cell lung cancer: A meta-analysis. *Thorac. Cancer*, **12**: 2838-2848. <https://doi.org/10.1111/1759-7714.14131>
- Liu, J., Xu, J., Zhang, W., Chen, J., Zhou, X., Li, Z. and Han, X., 2020. Safety and efficacy of drug-eluting bead transarterial chemoembolization combined with apatinib in patients with advanced hepatocellular carcinoma. *Acad. Radiol.*, **27**: 704-709. <https://doi.org/10.1016/j.acra.2019.07.003>
- Liu, J.Y., Zhu, B.R., Wang, Y.D. and Sun, X., 2020. The efficacy and safety of Apatinib mesylate in the treatment of metastatic osteosarcoma patients who progressed after standard therapy and the VEGFR2 gene polymorphism analysis. *Int. J. clin. Oncol.*, **25**: 1195-1205. <https://doi.org/10.1007/s10147-020-01644-7>
- Lu, W., Jin, X.L., Yang, C., Du, P., Jiang, F.Q., Ma, J.P., Yang, J., Xie, P. and Zhang, Z., 2017. Comparison of efficacy between TACE combined with apatinib and TACE alone in the treatment of intermediate and advanced hepatocellular carcinoma: A single-center randomized controlled trial. *Cancer Biol. Ther.*, **18**: 433-438. <https://doi.org/10.1080/15384047.2017.1323589>
- Ma, L., Wang, Z., Xie, M., Quan, Y., Zhu, W., Yang, F., Zhao, C., Fan, Y., Fang, N., Jiang, H. and Wang, Q., 2020. Silencing of circRACGAP1 sensitizes gastric cancer cells to apatinib via modulating autophagy by targeting miR-3657 and ATG7. *Cell Death Dis.*, **11**: 1-18. <https://doi.org/10.1038/s41419-020-2352-0>
- Nagata, Y., Kato, K., Miyamoto, T., Hirano, H., Shoji, H., Iwasa, S., Honma, Y., Takashima, A., Hamaguchi, T., Matsushita, H. and Nagashima, K., 2020. Safety and efficacy of cell-free and concentrated ascites reinfusion therapy (CART) in gastrointestinal cancer patients with massive ascites treated with systemic chemotherapy. *Support. Care Cancer*, **28**: 5861-5869. <https://doi.org/10.1007/s00520-020-05401-4>
- Peng, Z., Wei, J., Wang, F., Ying, J., Deng, Y., Gu, K., Cheng, Y., Yuan, X., Xiao, J., Tai, Y. and Wang, L., 2021. Camrelizumab combined with chemotherapy followed by camrelizumab plus apatinib as first-line therapy for advanced gastric or gastroesophageal junction adenocarcinoma first-line regimen for advanced G/GEJ adenocarcinoma. *Clin. Cancer Res.*, **27**: 3069-3078. <https://doi.org/10.1158/1078-0432.CCR-20-4691>
- Schade, S., Koenig, U., Mekolli, A., Gaedcke, J., Neesse, A., Reinecke, J., Brunner, M., Hosseini, A.S.A., Kitz, J., Stroebel, P. and Lotz, J., 2022. Cure is possible: Extensively metastatic HER2-positive gastric carcinoma with 5 years of complete remission after therapy with the FLOT regimen and trastuzumab. *Case Rep. Gastroenterol.*, **16**: 80-88. <https://doi.org/10.1159/000520057>
- Shitara, K., Baba, E., Fujitani, K., Oki, E., Fujii, S. and Yamaguchi, K., 2021. Discovery and development of trastuzumab deruxtecan and safety management for patients with HER2-positive gastric cancer. *Gastric Cancer*, **24**: 780-789. <https://doi.org/10.1007/s10120-021-01196-3>
- Suzuki, H., Yamada, T., Sugaya, A., Ueyama, S., Yamamoto, Y., Moriwaki, T. and Hyodo, I., 2021. Retrospective analysis for the efficacy and safety of nivolumab in advanced gastric cancer patients according to ascites burden. *Int. J. clin. Oncol.*, **26**: 370-377. <https://doi.org/10.1007/s10147-020-01810-x>

- Tanaka, Y., Chiwaki, F., Kojima, S., Kawazu, M., Komatsu, M., Ueno, T., Inoue, S., Sekine, S., Matsusaki, K., Matsushita, H. and Boku, N., 2021. Multi-omic profiling of peritoneal metastases in gastric cancer identifies molecular subtypes and therapeutic vulnerabilities. *Nat. Cancer*, **2**: 962-977. <https://doi.org/10.1038/s43018-021-00240-6>
- Wang, Y., Zhao, C., Chang, L., Jia, R., Liu, R., Zhang, Y., Gao, X., Li, J., Chen, R., Xia, X. and Bulbul, A., 2019. Circulating tumor DNA analyses predict progressive disease and indicate trastuzumab-resistant mechanism in advanced gastric cancer. *EBio Med.*, **43**: 261-269. <https://doi.org/10.1016/j.ebiom.2019.04.003>
- Xu, J., Shen, J., Gu, S., Zhang, Y., Wu, L., Wu, J., Shao, G., Zhang, Y., Xu, L., Yin, T. and Liu, J., 2021. Camrelizumab in combination with apatinib in patients with advanced hepatocellular carcinoma (RESCUE): A nonrandomized, open-label, Phase II trial camrelizumab plus apatinib in advanced HCC. *Clin. Cancer Res.*, **27**: 1003-1011. <https://doi.org/10.1158/1078-0432.CCR-20-2571>
- Yang, Q.K., Chen, T., Wang, S.Q., Zhang, X.J. and Yao, Z.X., 2020. Apatinib as targeted therapy for advanced bone and soft tissue sarcoma: A dilemma of reversing multidrug resistance while suffering drug resistance itself. *Angiogenesis*, **23**: 279-298. <https://doi.org/10.1007/s10456-020-09716-y>
- Yang, Y., Kim, H.J., Go, S.I., Bae, W.K., Song, E.K., Byeon, S., Kim, H.K., Jeong, Y., Kwon, J., Lee, K.H. and Chae, H.B., 2022. Diagnostic value of ascitic tumor markers for gastric cancer-associated malignant ascites. *Korean J. Helicobacter Up. Gastrointest. Res.*, **22**: 38-49. <https://doi.org/10.7704/kjhugr.2021.0058>
- Zhang, B., Qi, L., Wang, X., Xu, J., Liu, Y., Mu, L., Wang, X., Bai, L. and Huang, J., 2020. Phase II clinical trial using camrelizumab combined with apatinib and chemotherapy as the first-line treatment of advanced esophageal squamous cell carcinoma. *Cancer Commun.*, **40**: 711-720. <https://doi.org/10.1002/cac2.12119>
- Zhao, L., Peng, Y., He, S., Li, R., Wang, Z., Huang, J., Lei, X., Li, G. and Ma, Q., 2021. Apatinib induced ferroptosis by lipid peroxidation in gastric cancer. *Gastric Cancer*, **24**: 642-654. <https://doi.org/10.1007/s10120-021-01159-8>
- Zhou, C., Wang, Y., Zhao, J., Chen, G., Liu, Z., Gu, K., Huang, M., He, J., Chen, J., Ma, Z. and Feng, J., 2021. Efficacy and biomarker analysis of camrelizumab in combination with apatinib in patients with advanced nonsquamous NSCLC previously treated with chemotherapy efficacy and biomarker analysis of camrelizumab and apatinib. *Clin. Cancer Res.*, **27**: 1296-1304. <https://doi.org/10.1158/1078-0432.CCR-20-3136>
- Zhou, S., Xu, B., Qi, L., Zhu, D., Liu, B. and Wei, J., 2019. Next-generation sequencing reveals mutational concordance between cell-free DNA from plasma, malignant pleural effusion and ascites and directs targeted therapy in a gastric cancer patient. *Cancer Biol. Ther.*, **20**: 15-20. <https://doi.org/10.1080/15384047.2018.1504720>