

# Evaluation of Protective Effect of Naringenin on Cadmium-Induced Kidney Injury in Rats

Chen Zhao, Lulu Ding, Ying Ye, Congying Kou, Haoran Xiao, Jing Zhu and Jicang Wang\*

College of Animal Science and Technology, Henan University of Science and Technology, No.263, Kaiyuan Avenue, 471023, Luoyang, PR China

## ABSTRACT

Cadmium (Cd) is a silver-white, toxic and rare metal that exists in nature and can adversely affect the health of living organisms. Naringenin (Nar) is a natural flavonoid that protects many tissues of the body from the toxic effects of heavy metals. Studies have explored the adverse effects of Cd on rats and other animals, but the mechanism of Cd-induced autophagy in the kidney and the antagonistic effect of Nar on Cd are still unclear. In this study, SD rats were treated with Cd and/or Nar to investigate the protective effect of Nar on Cd-induced toxicity. The rats were treated for 4 weeks. The histopathological observation, oxidative stress index and autophagy-related gene expression level were detected of rat kidneys. The results showed that Cd caused the pathological changes of kidneys. And Cd also increased the content of glutathione and malondialdehyde and decreased the content of catalase and total superoxide dismutase. Instead, Nar significantly attenuated these Cd-induced toxic activities. Furthermore, the protein expression levels of Beclin1 and P62 were increased in the Cd-treated group. Treatment with Nar can significantly inhibit the increase of P62 protein expression level caused by Cd, indicating that Nar has a certain inhibitory effect on cell autophagy. In general, this study shows that Cd caused oxidative stress and autophagy. Nar can reduce the toxicity of Cd by attenuating oxidative stress and inhibiting autophagy. The specific mechanism of Nar antagonizing the toxicity of Cd can provide new ideas for anti-Cd toxicity, and also provide theoretical basis for the clinical application of Nar.

## Article Information

Received 28 June 2022  
Revised 18 July 2022  
Accepted 01 August 2022  
Available online 15 September 2022 (early access)  
Published 31 July 2023

## Authors' Contribution

CZ conceptualization, project administration, software, writing-original draft, review, editing. LD conceptualization, formal analysis, writing-editing, data curation, writing-review and editing. YY methodology, visualization. CK data curation, formal analysis. HX data curation, formal analysis. JZ methodology, formal analysis. JW resources, validation, formal analysis, funding acquisition.

## Key words

Cadmium, Naringenin, Kidney, Oxidative stress, Autophagy

## INTRODUCTION

Cadmium (Cd) is a kind of silver-white natural rare metal element that exists in nature (Gong *et al.*, 2022). When Cd exists in the body, the organ with the highest accumulation content is the kidney, which will cause the metabolic dysfunction of the kidney and cause serious impact on the kidney function. The damage to the kidney during Cd poisoning is relatively mild in the renal corpuscle and renal tubule, but more serious in the proximal convoluted tubule, which can cause renal tubular dysfunction and even cause autophagy (Wang *et al.*, 2017). Damaged organelles and protein-degrading fractions in the cytoplasm can be removed by the process of autophagy. The relationship between autophagy and cell death is complex.

Under normal physiological conditions, cells can perform low levels of autophagy. However, autophagy is activated when cells are stimulated by various stimuli, for example alimentary deficiency, hypoxia, organelle damage, exposure to certain chemicals, invasion of cells by certain microorganisms, excessive accumulation of abnormal proteins within cells, etc. In these cases, autophagy functions to protect cell survival. But excessive autophagy can lead to cell death, manifested by the destruction of the basic components of the cell, known as autophagic cell death (Codogno and Meijer, 2005; Gurusamy and Das, 2009; Kasprowska-Liskiewicz, 2017).

Flavonoids are the most abundant antioxidants in plants and human diet (Zhao *et al.*, 2021). Naringenin (Nar), a natural polyphenolic compound, has received extensive attention for its role in preventing and treating oxidative stress damage (Wang *et al.*, 2021). Nar has diverse pharmacological activities, including antioxidant, anti-inflammatory, immunomodulatory, neuroprotective, nephroprotective, hepatoprotective, anticancer and antidiabetic properties (Rauf *et al.*, 2022; Renugadevi and Prabu, 2010). Its content is as high as 43.5 mg/100mL in grapefruit, 2.13 mg/100mL in orange juice, and only 0.38 mg/100mL in lemon juice. For the sake of study, the effect and mechanism of Nar on rat kidney damage caused by

\* Corresponding author: wangjicang@126.com  
0030-9923/2023/0005-2229 \$ 9.00/0



Copyright 2023 by the authors. Licensee Zoological Society of Pakistan.

This article is an open access article distributed under the terms and conditions of the Creative Commons Attribution (CC BY) license (<https://creativecommons.org/licenses/by/4.0/>).

Cd, this study established a *in vivo* model in experimental animal rats. This study aimed to explore the protective effect of Nar on Cd-induced oxidative damage, and provide theoretical basis for the clinical application of Nar.

## MATERIALS AND METHODS

### *Chemicals*

Glutathione (GSH), malondialdehyde (MDA), total superoxide dismutase (T-SOD) and catalase (CAT) kits were purchased from Nanjing Jiancheng Bioengineering Institute, Ltd (Nanjing, China), CdCl<sub>2</sub> (99.99%) was purchased from Sigma-Aldrich Co., Ltd (Shanghai, China), naringenin was purchased from Beijing Bailingwei Technology Co., Ltd (98%, Beijing, China), glacial acetic acid, PBS buffer, 10% formaldehyde, anhydrous ethanol, xylene (all analyzing pure). Primary antibodies P62, Beclin1 and  $\beta$ -actin were purchased from Proteintech Group (Rosemont, USA). Secondary antibodies were purchased from the Beijing Zhongshan Golden Bridge Biotechnology Co., Ltd. (Beijing, China).

### *Animals*

The experimental animals were SD rats with a weight of about 150 g at the age of 5 weeks. They were provided by Henan Experimental Animal Center.

### *Experimental design*

Healthy male SD rats (n=24), fed with rat chow, allowed free access to food and water, natural lighting in the animal rearing room, and maintained at room temperature (24°C±2°C). After 1 week of adaptive feeding, the rats were randomly divided into four groups, with six rats per group. They were treated as follows: The control group received 1 mL/kg b.w. of 0.9% NaCl by intraperitoneal injection, the Cd-treated group received 1 mg/kg b.w. of CdCl<sub>2</sub> by intraperitoneal injection, the Nar-treated group received 100 mg/kg b.w. of Nar by oral gavage, and the Cd + Nar-treated group received 1 mg/kg b.w. of CdCl<sub>2</sub> by intraperitoneal injection and 100 mg/kg b.w. of Nar by oral gavage.

The experiment lasted for 4 weeks. Respiratory anesthesia was performed on the rats in each group with diethyl ether. Then, the rats were killed by dislocation, and the kidneys were collected. Then, some kidneys were placed in 10% formaldehyde solution for fixation, and a kidney section was prepared for later use. Some kidney tissues were chopped, homogenized (10%, w/v) in PBS solution (pH 7.4), and centrifuged (3000 rpm for 10 min). Stored the clarified supernatant at -80 °C for later use to detect the content and activity of relevant biochemical indicators in the tissue.

### *Histopathological analysis*

Fresh kidneys were immersed in formaldehyde solution for 24 h for fixation, and then cut into 1 × 1 × 0.5 cm cuboids. Gradual dehydration was carried out with different concentrations of gradient ethanol as dehydrating agent. After removing the water, the tissue blocks were placed in xylene. The clearly treated kidney tissue is immersed in completely liquefied pure paraffin. The solidified paraffin was placed in a microtome to be fixed for slicing, and the slice thickness was set to 4  $\mu$ m. The paraffin sections containing kidney tissue were placed in water at 42°C and stretched out naturally. The kidney tissue was placed in the center of the slide glass, and then put it into a 45°C incubator to dry for about 40 minutes. Dyeing was carried out according to the instructions of the HE dyeing process. Then the prepared slices to take pictures and observe.

### *Antioxidant analysis*

GSH and MDA contents, T-SOD and CAT activities were detected using a diagnostic kit according to the method on the kit instructions. These results were measured spectrophotometrically.

### *Detection of protein expression by western blot*

First, the total protein of kidney tissue was extracted. Rinse kidney tissue with 4°C PBS buffer, cut the tissue into small pieces with surgical scissors and place them in a grinder. Add lysis buffer to the grinder (tissue block: lysis buffer = 1:9), the mixture was triturated in an ice-water bath to prepare a tissue homogenate. The tissue homogenate was then transferred to a centrifuge tube, shaken on a shaker for 6-10 s, and centrifuged (12000 rpm for 10 min) at 4°C. After the end, the protein supernatant was taken for use. The next step is protein denaturation. According to the ratio of protein loading buffer: Protein supernatant = 1:4, add 5 protein loading buffer. After the denaturation is completed in a boiling water bath for 15min, put it in the refrigerator at -20°C for later use. Then, SDS-PAGE electrophoresis, membrane transfer, immunoreaction and chemiluminescence were performed in sequence. Finally, the protein expression level was detected by gel image analysis.

### *Statistical analysis*

Statistical analysis was performed on the data, and SPSS 15.0 software was used to analyze the variance (ANOVA). Determination results are expressed as mean Standard Error (SE),  $P > 0.05$  means no statistical significance, that is, no significant difference,  $P < 0.05$  means statistically significant, significant difference,  $P < 0.01$  means extremely significant difference.

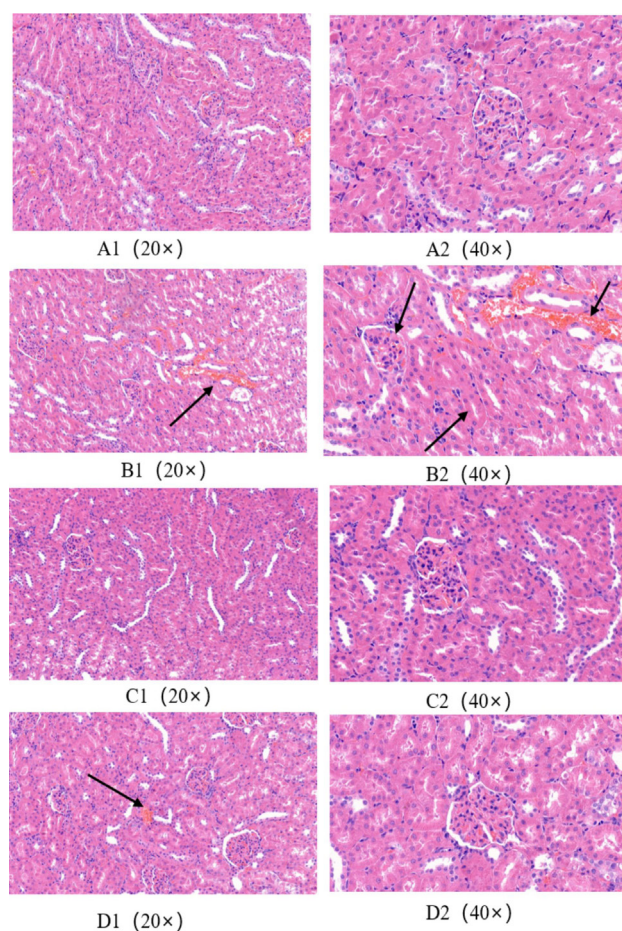


Fig. 1. Effect of naringenin on Cadmium-induced kidney injury in rats. Rats were treated with Cd an/or Nar for 4 weeks. A1 and A2, the control group showing normal renal tissue structure, and structures such as glomerulus, renal tubule and renal cortex were clearly visible. B1 and B2, the Cd-treated group showing that renal glomerular cells atrophy, the structure of renal tubules was severely damaged, epithelial cells were disordered and degenerated, inflammatory cells infiltrated, interstitial congestion, and extensive lesions occurred: Cells are exfoliated and necrotic and interstitial fibrosis, cells are destroyed, and cell membrane boundaries are blurred; C1 and C2, the Nar-treated group showing normal kidney structure; D1 and D2, the kidney structure of the rats in the Cd+ Nar-treated group was basically normal. Stain: H&E.

## RESULTS

### Histological evaluation of rat kidney

It can be observed from Figure 1A1, A2, C1 and C2, there was no abnormal change in renal tissue structure in the control group and the Nar-treated group, and the

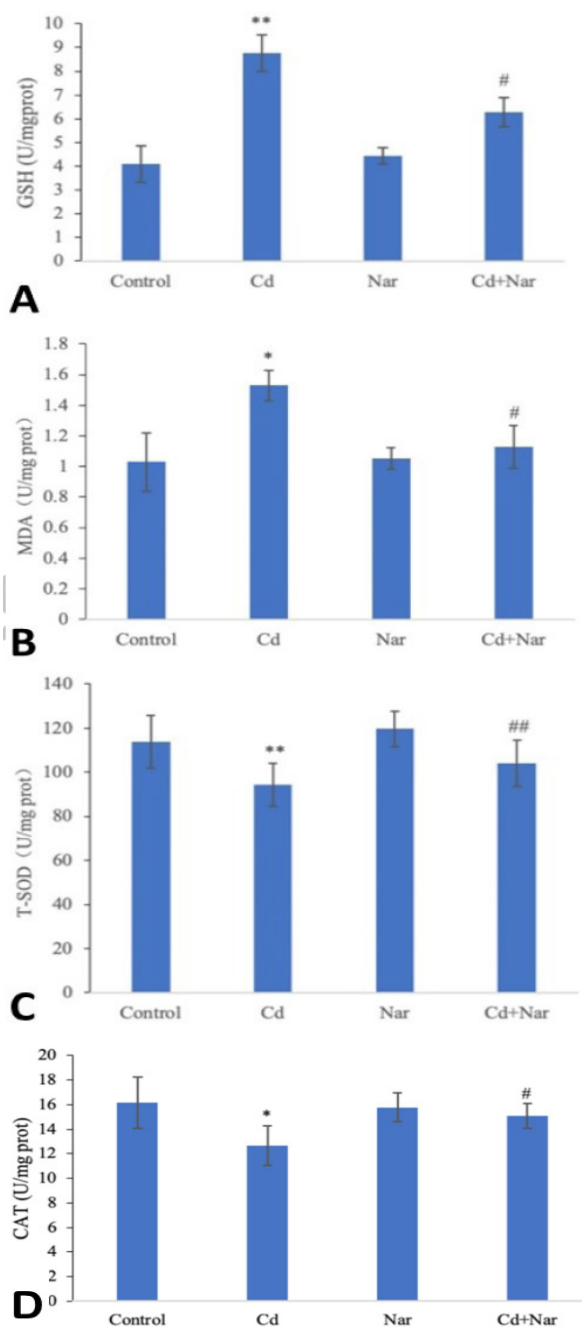


Fig. 2. Effect of naringenin on GSH (A), MDA (B), and T-SOD activity (C) in rat kidney. Rats were treated with Cd an/or Nar for 4 weeks. Then, the content of GSH and activities of catalase and SOD in kidney tissue of rats in different treatment groups were detected. Data are represented as mean  $\pm$  SE.  $n=6$ . “\*” or “\*\*” means that the difference is significant ( $* P<0.05$ ) or extremely significant ( $** P<0.01$ ) compared with the control group; “#” or “##” means that the difference is significant ( $# P<0.05$ ) or extremely significant ( $## P<0.01$ ) compared with the Cd-treated group.

structures of the glomerulus, renal tubule and renal cortex were clearly visible, and no obvious lesions were found. Figures 1B1, B2 and 1A1, A2 show that in the Cd-treated group, glomerular cells atrophy, the structure of renal tubules is severely damaged, epithelial cells are disordered and degenerated, inflammatory cells infiltrate, interstitial congestion, and extensive lesions occur: A large number of proximal convoluted tubule epithelial cells were necrotic and accumulated in the lumen, and renal tubular cells were exfoliated and necrotic and interstitial fibrosis occurred. The cells were destroyed and the cell membrane boundaries were blurred. Figure 1D1, D2, 1B1, B2 can be seen, the Cd+ Nar-treated group, the structure of the kidney was basically intact, and only a few cellular structures were damaged. The structure of the glomerulus and glomerulus was normal, and no obvious lesions were found.

#### GSH and MDA contents of rat kidney

As can be seen from Figure 2A and B, the content of GSH and MDA in the Cd-treated group extremely significantly ( $P<0.01$  and  $P<0.05$ ) increased compared with that in the control group; compared with the Cd-treated group, the GSH and MDA content in the kidney tissue of the Cd+ Nar-treated group was significantly decreased ( $P<0.05$ ).

#### T-SOD and CAT activities in rat kidney

The Cd-treated group showed extremely significantly ( $P<0.01$ ) reduced activities of T-SOD and catalase compared with the control group; compared with the Cd-treated group (Fig. 2C, D). The T-SOD and catalase activities in the kidney tissue of the Cd+ Nar-treated group was extremely significantly increased.

#### Expression levels of autophagy proteins P62 and Beclin1 in rat kidney tissue

As can be seen from Figure 3, compared with the control group, the expression levels of P62 and Beclin1 proteins in the Cd-treated group were significantly or extremely significantly increased ( $P<0.05$  or  $P<0.01$ ). Compared with the Cd-treated group, the expression level of P62 protein in the Cd+ Nar-treated group was significantly decreased ( $P<0.05$ ), but the protein expression level of Beclin1 was significantly increased ( $P<0.05$ ).

## DISCUSSION

Cd enters the body in various ways, and the impact of Cd pollution on human and animal health is becoming more and more serious (Arab-Nozari *et al.*, 2020). As one of the important storage sites of Cd, the kidney is seriously damaged by Cd (Egger *et al.*, 2019). In addition, Cd causes

oxidative damage to tissue cells, and Nar is an antioxidant. Previous research has shown that Cd can cause kidney injury in rats and is associated with the development of oxidative stress (Mouro *et al.*, 2021).

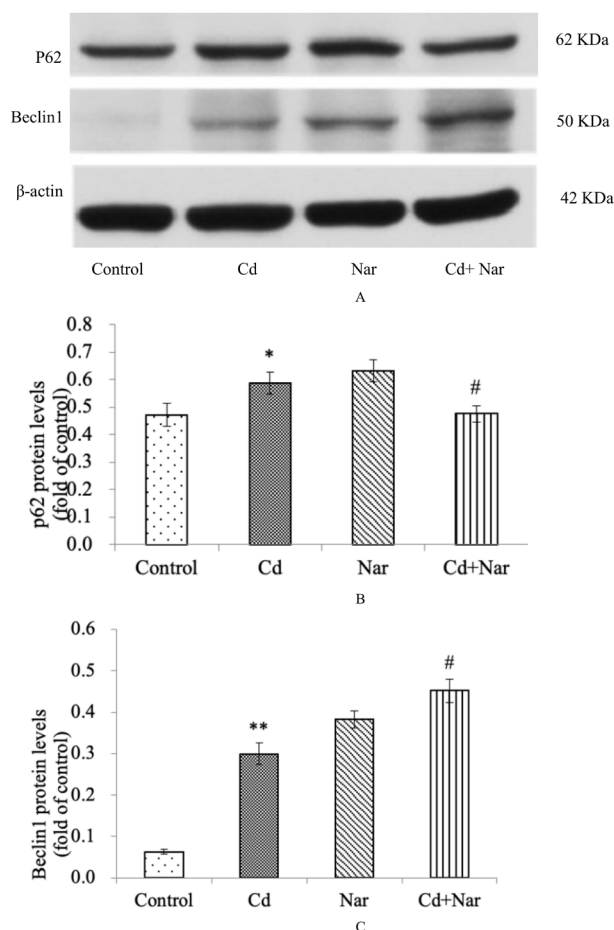


Fig. 3. Effect of naringenin on the expression of p62 and Baclin1 in kidney tissue induced by cadmium.

Rats were treated with Cd and/or Nar for 4 weeks. Then, the protein expression levels of P62 and Beclin1 in kidney tissue were analyzed by western bolt. A: Western blot image; B: Quantitative analysis of P62 protein expression; C: Quantitative analysis of Beclin1 protein expression. “\*” or “\*\*” means that the difference is significant ( $* P<0.05$ ) or extremely significant ( $** P<0.01$ ) compared with the control group; “#” or “##” means that the difference is significant ( $# P<0.05$ ) or extremely significant ( $## P<0.01$ ) compared with the Cd-treated group.

#### Histopathological effects of Cadmium and Naringenin on rat kidney

The rat kidney tissue sections were observed, and the renal tissue structure damage, renal tubular necrosis, renal tubular degeneration, and renal tubular swelling in the



Cd-treated group were observed. This may be due to the increase of lipid peroxidation in rat renal tissue caused by Cd, and the accumulation of free radicals eventually leads to extensive renal damage, resulting in extensive renal lesions (Koyu *et al.*, 2006; Skipper *et al.*, 2016); compared with the Cd-treated group, the renal structure of Cd in the Cd+ Nar-treated group was relatively complete, with few abnormal changes in renal tubules and glomeruli, and less pathological damage. It shows that Nar can effectively reduce the damage of rat kidney caused by Cd, and has a certain protective effect on Cd toxicity damage.

#### *Effects of Cadmium and Naringenin on oxidative stress in rat kidney*

GSH is a special glycine that can combine with free radicals and peroxides in the body to antagonize the damage to tissues and organs caused by free radicals. It has a variety of protective effects on the body, such as anti-oxidation, inhibition of free radical damage, free radical scavenging, etc., (Kamiyama *et al.*, 1995). Cd can interact with -SH in GSH, the main intracellular defense against reactive oxygen species generation, lipid peroxidation, and oxidative damage. Especially during oxidative phosphorylation and detoxification, -SH consumption is one of the important mechanisms of Cd-induced oxidative stress (Jahan *et al.*, 2014). These processes are ultimately responsible for the accumulation of reactive oxygen species (Wang *et al.*, 2020). Therefore, changes in GSH content can reflect the degree of cellular oxidative damage. MDA is an important indicator reflecting the degree of peroxidation in the body, and it is the product of tissue cells after peroxidation. Therefore, the degree of peroxidation in the body can be preliminarily determined by measuring the content of MDA. The results of this study suggested that compared with the control group, the contents of GSH and MDA in the kidney tissue of the Cd-treated group were significantly increased, indicating that Cd led to the production of a large number of free radicals in the kidneys, resulting in an increase in the level of oxidation in the tissue, and the peroxidation of tissue cells, causing damage to them. Compared with the Cd-treated group, the contents of GSH and MDA in the kidney tissue of the Cd+ Nar-treated group were significantly reduced, indicating that Nar can reduce the increase in tissue oxidation caused by Cd and inhibit the body's peroxidation caused by Cd. That is, Nar has a certain protective effect on kidney tissue damage caused by Cd.

T-SOD has many effects on the body, such as slowing down aging, inhibiting tumors, maintaining body balance, and scavenging superoxide anion free radicals. In animals, hydroxyl radicals are particularly destructive, and their chemical properties are more active than other free radicals

(Zhu *et al.*, 2016). The hydrogen and oxygen free radicals can be decomposed by CAT and lose their activity, so as to maintain the balance of the internal environment of the body. Therefore, in scavenging reactive oxygen species, the role of CAT is particularly prominent. The results of this study suggested that compared with the control group, the activities of T-SOD and CAT in the kidneys of the Cd-treated group were significantly decreased. This may be due to the substitution of T-SOD metal auxiliary group by Cd ion, resulting in an inhibitory effect; or a direct inhibitory effect on CAT activity. Compared with the Cd-treated group, the activities of T-SOD and CAT in the kidney tissue of the Cd+ Nar-treated group were significantly increased. This indicates that Nar can alleviate the peroxidative damage of Cd poisoning to the body's kidney tissue, and thus play a role in protecting the body.

#### *Effects of Cadmium on the expression levels of autophagy proteins P62 and Beclin1 in rat kidney tissue*

Autophagy is one of the important self-protection mechanisms of the body's cells (Arab *et al.*, 2022; Tong *et al.*, 2022). When the body is stimulated by oxidative stress caused by Cd, the autophagy pathway will be activated, causing cells to undergo autophagy to protect the body from damage. Studies have shown that with the increase of Cd exposure dose, Cd accumulates in rat tissues and damages cells, activates the autophagy mechanism, triggers autophagic death of cells, and increases the expression level of autophagy-related proteins in cells (Wang *et al.*, 2020; Zhao *et al.*, 2021). Some studies have also shown that autophagy only occurs in early Cd poisoning. When the body is exposed to Cd for a long time, inhibiting autophagy can aggravate cell apoptosis. Studies showed that Cd exposure significantly increased the Cd content in duck renal tubular epithelial cells, the number of autophagosomes and LC3 punctate bodies, and up-regulated the mRNA levels of LC3A, LC3B, Beclin-1, Atg5, Beclin-1 and LC3II /LC3I protein level, down-regulated p62 mRNA level and p62 protein level (Wang *et al.*, 2020). But the autophagy inhibitor 3-MA decreased Beclin-1, LC3II/LC3I protein levels, increased p62 protein levels, significantly increased Caspase-3, Cyt C, Bax and Bak-1 mRNA levels, Caspase-3 and cleaved Caspase-3 protein levels, apoptosis rate and cell damage. These results suggest that Cd exposure induces autophagy in duck renal tubular epithelial cells, and inhibition of autophagy may exacerbate Cd-induced apoptosis through mitochondria-mediated pathways.

The results of this study showed that compared with the control group, the expression levels of autophagy proteins Beclin1 and P62 in the Cd-treated group were

significantly increased, indicating that Cd exposure led to a significant enhancement of cell autophagy, which may be one of the mechanisms of Cd-induced kidney injury. Compared with the Cd-treated group, the expression level of autophagy protein P62 in the Cd+ Nar-treated group was significantly decreased, which indicated that Nar had a certain inhibitory effect on cell autophagy, but could not reduce the expression level of Beclin1 protein. The specific mechanism needs to be further studied.

## CONCLUSIONS

The Cd exposure causes pathological damage to the kidney, increases the level of lipid peroxides in the body tissue, weakens the activity and antioxidant capacity of antioxidant enzymes, and increases the content of autophagy protein in kidney tissue cells. This suggests that Cd causes kidney damage through oxidative stress and autophagy. Nar can reduce the oxidative damage and autophagy level of kidney tissue, and has a certain protective effect on the kidney damage caused by Cd.

## ACKNOWLEDGEMENT

This study was supported by grants from National Nature Science Foundation of China (No. 31972753), Henan science and technology research program (222102110340). Student Research Training Program of Henan University of science and technology (2022490).

### Statement of conflicts of interest

The authors have declared no conflict of interest.

## REFERENCES

- Arab, H.H., Ashour, A.M., Eid, A.H., Arafa, E.A., Al-Khabbaz, H.J., and Abd-El-Aal, S.A., 2022. Targeting oxidative stress, apoptosis, and autophagy by galangin mitigates cadmium-induced renal damage: Role of SIRT1/Nrf2 and AMPK/mTOR pathways. *Life Sci.*, **291**: 120300. <https://doi.org/10.1016/j.lfs.2021.120300>
- Arab-Nozari, M., Mohammadi, E., Shokrzadeh, M., Ahangar, N., Amiri, F.T., and Shaki, F., 2020. Co-exposure to non-toxic levels of cadmium and fluoride induces hepatotoxicity in rats via triggering mitochondrial oxidative damage, apoptosis, and NF- $\kappa$ B pathways. *Environ. Sci. Pollut. Res. Int.*, **27**: 24048-24058. <https://doi.org/10.1007/s11356-020-08791-4>
- Codogno, P., and Meijer, A., 2005. Autophagy and signaling: their role in cell survival and cell death. *Cell Death Differ.*, **12**: 1509-1518. <https://doi.org/10.1038/sj.cdd.4401751>
- Egger, A.E., Grabmann, G., Gollmann-Tepekoylu, C., Pechriggl, E.J., Artner, C., Turkcan, A., Hartinger, C.G., Fritsch, H., Keppler, B.K., Brenner, E., Grimm, M., Messner, B., and Bernhard, D., 2019. Chemical imaging and assessment of cadmium distribution in the human body. *Metallomics*, **11**: 2010-2019. <https://doi.org/10.1039/C9MT00178F>
- Gong, Z.G., Zhao, Y., Wang, Z.Y., Fan, R.F., Liu, Z.P., and Wang, L., 2022. Epigenetic regulator BRD4 is involved in cadmium-induced acute kidney injury via contributing to lysosomal dysfunction, autophagy blockade and oxidative stress. *J. Hazard. Mater.*, **423**: 127110. <https://doi.org/10.1016/j.jhazmat.2021.127110>
- Gurusamy, N., and Das, D., 2009. Is autophagy a double-edged sword for the heart? *Acta Physiol. Hung.*, **96**: 267-276. <https://doi.org/10.1556/APhysiol.96.2009.3.2>
- Jahan, S., Khan, M., Ahmed, S., and Ullah, H., 2014. Comparative analysis of antioxidants against cadmium induced reproductive toxicity in adult male rats. *Syst. Biol. Reprod. Med.*, **60**: 28-34. <https://doi.org/10.3109/19396368.2013.843039>
- Kamiyama, T., Miyakawa, H., Li, J.P., Akiba, T., and Sato, C., 1995. Effects of one-year cadmium exposure on livers and kidneys and their relation to glutathione levels. *Res. Commun. Mol. Pathol. Pharmacol.*, **88**: 177.
- Kasprowska-Liskiewicz, D., 2017. The cell on the edge of life and death: Crosstalk between autophagy and apoptosis. *Postepy Hig. Med. Dosw., (Online)*, **71**: 825-841. <https://doi.org/10.5604/01.3001.0010.4672>
- Koyu, A., Gokcimen, A., Ozguner, F., Bayram, D., and Kocak, A., 2006. Evaluation of the effects of cadmium on rat liver. *Mol. cell. Biochem.*, **284**: 81-85. <https://doi.org/10.1007/s11010-005-9017-2>
- Mouro, V.G.S., Ladeira, L.C.M., Lozi, A.A., de Medeiros, T.S., Silva, M.R., de Oliveira, E.L., de Melo, F., and da Matta, S.L.P. 2021. Different routes of administration lead to different oxidative damage and tissue disorganization levels on the subacute cadmium toxicity in the liver. *Biol. Trace Elem. Res.*, **199**: 285-297. <https://doi.org/10.1007/s12011-020-02570-5>
- Rauf, A., Shariati, M.A., Imran, M., Bashir, K., Khan, S.A., Mitra, S., Emran, T.B., Badalova, K., Uddin, M.S., Mubarak, M.S., Aljohani, A.S.M., Alhumaydhi, F.A., Derkho, M., Korpayev, S., and Zengin, G., 2022. Comprehensive review on

- naringenin and naringin polyphenols as a potent anticancer agent. *Environ. Sci. Pollut. Res. Int.*, **29**: 31025-31041. <https://doi.org/10.1007/s11356-022-18754-6>
- Renugadevi, J., and Prabu, S.M., 2010. Cadmium-induced hepatotoxicity in rats and the protective effect of naringenin. *Exp. Toxicol. Pathol. Off. J. Ges. Toxikol. Pathol.*, **62**: 171-181. <https://doi.org/10.1016/j.etp.2009.03.010>
- Skipper, A., Sims, J., Yedjou, C., and Tchounwou, P., 2016. Cadmium chloride induces DNA damage and apoptosis of human liver carcinoma cells via oxidative stress. *Int. J. Environ. Res. Publ. Hlth.*, **13**: 88. <https://doi.org/10.3390/ijerph13010088>
- Tong, X., Yu, G., Liu, Q., Zhang, X., Bian, J., Liu, Z., and Gu, J. 2022. Puerarin alleviates cadmium-induced oxidative damage to bone by reducing autophagy in rats. *Environ. Toxicol.*, **37**: 720-729. <https://doi.org/10.1002/tox.23437>
- Wang, C., Nie, G., Zhuang, Y., Hu, R., Wu, H., Xing, C., Li, G., Hu, G., Yang, F., and Zhang, C., 2020. Inhibition of autophagy enhances cadmium-induced apoptosis in duck renal tubular epithelial cells. *Ecotoxicol. Environ. Saf.*, **205**: 111188. <https://doi.org/10.1016/j.ecoenv.2020.111188>
- Wang, J., Zhu, H., Lin, S., Wang, K., Wang, H., and Liu, Z., 2021. Protective effect of naringenin against cadmium-induced testicular toxicity in male SD rats. *J. Inorg. Biochem.*, **214**: 111310. <https://doi.org/10.1016/j.jinorgbio.2020.111310>
- Wang, J., Zhu, H., Wang, K., Yang, Z., and Liu, Z., 2020. Protective effect of quercetin on rat testes against cadmium toxicity by alleviating oxidative stress and autophagy. *Environ. Sci. Pollut. Res. Int.*, **27**: 25278-25286. <https://doi.org/10.1007/s11356-020-08947-2>
- Wang, X., Wang, T., Pan, T., Huang, M., Ren, W., Xu, G., Amin, H.K., Kassab, R.B., and Abdel-Moneim, A.E. 2020. Senna alexandrina extract supplementation reverses hepatic oxidative, inflammatory, and apoptotic effects of cadmium chloride administration in rats. *Environ. Sci. Pollut. Res. Int.*, **27**: 5981-5992. <https://doi.org/10.1007/s11356-019-07117-3>
- Wang, X.Y., Yang, H., Wang, M.G., Yang, D.B., Wang, Z.Y., and Wang, L., 2017. Trehalose protects against cadmium-induced cytotoxicity in primary rat proximal tubular cells via inhibiting apoptosis and restoring autophagic flux. *Cell Death Dis.*, **8**: e3099. <https://doi.org/10.1038/cddis.2017.475>
- Zhao, Y., Li, Z.F., Zhang, D., Wang, Z.Y., and Wang, L., 2021. Quercetin alleviates Cadmium-induced autophagy inhibition via TFEB-dependent lysosomal restoration in primary proximal tubular cells. *Ecotoxicol. Environ. Saf.*, **208**: 111743. <https://doi.org/10.1016/j.ecoenv.2020.111743>
- Zhu, Y., Hu, C., Zheng, P., Miao, L., Yan, X., Li, H., Wang, Z., Gao, B., and Li, Y., 2016. Ginsenoside Rb1 alleviates aluminum chloride-induced rat osteoblasts dysfunction. *Toxicology*, **368-369**: 183-188. <https://doi.org/10.1016/j.tox.2016.07.014>