



Evaluation of Cardioprotective Potential of Hydroalcoholic Leaf Extract of *Citrullus colocynthis* against Doxorubicin Induced Oxidative Stress in Rats

Ashira Manzoor¹, Imran Ahmad Khan^{1,2*}, Muqadas Sadiq³, Muhammad Omer Iqbal⁴ and Shaukat Hussain Munawar⁵

¹Fatima-Tu-Zahra, Department of Life Sciences Muhammad Institute of Medical and Allied Sciences, Multan, Pakistan

²Department of Pharmacology, The Islamia University of Bahawalpur, Bahawalpur

³Ali-Ul-Murtaza, Department of Rehabilitation Sciences, Muhammad Institute of Medical and Allied Sciences, Multan, Pakistan

⁴Department of Shandong Provincial Key Laboratory of Glycoscience and Glycotechnology, Ocean University of China, China

⁵Department of Pharmacology and Toxicology, Cholistan University of Veterinary and Animal Sciences, Bahawalpur, Pakistan

ABSTRACT

To evaluate the cardioprotective potential of hydroalcoholic leaf extract of *Citrullus colocynthis* against doxorubicin-induced myocardial ischemia in rats. Animals were divided into 5-groups each group consisting eight rats. Group-1 was given saline for 2 weeks and on 11th day DOX 18mg/kg was given intraperitoneally. Group-2, Group-3, Group-4 rats pre-treated orally with the leaf extract of *C. colocynthis* 250mg/kg, 500mg/kg, 750mg/kg respectively for 14 successive days and on 11th-day DOX was inoculated, while group-5 was used as positive control and was given dexrazoxane 180mg/kg after 30 min DOX was given. The levels of CK-MB, LDH, troponin-I, AST, CRP, ALT, and ALP were estimated in all 5-groups and compared. Histopathology was conducted to examine the status of cardio myocytes. Pretreatment of rats with leaf extract had a cardio protective effect and significantly reduces the biochemical parameters against doxorubicin-induced myocardial damage in dose-dependent manner. The cardiac tissues showed marked improvement in extract treated groups as compared to doxorubicin treated group. This research indicates that the hydro alcoholic leaf extract of *C. colocynthis* have exceptional cardio protective potential as compared to toxicity induced by DOX. As a result, it could be used as an alternative medicine for the treatment of cardiovascular disorders.

Article Information

Received 15 July 2021

Revised 05 October 2021

Accepted 27 October 2021

Available online 21 February 2022
(early access)

Published 24 October 2022

Authors' Contribution

IAK study design and supervise the experiment. AM, MS data collection and acquisition of the experiment. MOI literature review, statistical evaluation and histopathology. SHM writing and final review and approval of article.

Key words

Doxorubicin, *C. colocynthis*, Cardio protective, CK-MB, AST, ALP

INTRODUCTION

Doxorubicin (DOX) was first isolated in 1960 from bacteria *Streptomyces peucetius* and it belongs to the family of anthracyclines. DOX is very useful for treating lymphoma, leukemia and solid cancer (Slingerland *et al.*, 2012). It is used as an anticancer drug and DOX (hydrochloride) liposomal injection became the first

liposomal-encapsulated anticancer agent that received clinical approval (Slingerland *et al.*, 2012). In 1967, it was identified that its precursor daunorubicin causes extreme cardiovascular toxicity that results genetic mutation in *Streptomyces*, leading to the production of Adriamycin, later renamed as "doxorubicin" (Rivankar, 2014). DOX produces dose-dependent and irreversible hepatotoxicity and cardiotoxicity (Ibrahim *et al.*, 2012). Although, it has a great therapeutic potential but its side effects, hepatotoxicity and cardiomyopathy still continue to limit its use (Ibrahim *et al.*, 2012). Phospholipids that are present in the membranes of mitochondria have high affinity for DOX and when DOX induces it accumulates in the cardio myocytes, causes several changes in function and structure of cardiac tissues (El-Sayed *et al.*, 2011). Dox causes hepatotoxicity and cardiotoxicity in three different phases (Xiong *et al.*, 2006). After induction, the

* Corresponding author: imranahmadkhandurrani@gmail.com
0030-9923/2023/0001-193 \$ 9.00/0



Copyright 2023 by the authors. Licensee Zoological Society of Pakistan.

This article is an open access article distributed under the terms and conditions of the Creative Commons Attribution (CC BY) license (<https://creativecommons.org/licenses/by/4.0/>).

acute phase occurs in less than one percent patients and it is reversible if the therapy stopped (Xiong *et al.*, 2006), while within one week, subacute form appears (Curigliano *et al.*, 2010). The chronic phase occurs within one year due to decreased activity of left ventricular portion of heart and leads to myocardial infarction (Gharib and Burnett, 2002). Several pathways have been linked to DOX-induced cardiomyopathy, such as stimulation and inactivation of enzymatic pathways, oxidative stress, exaggerated immune response and functional down regulation of proteins present in mitochondria and cardiac muscles. These multiple pathological events altered the signaling pathways and activates the apoptotic cascade that results in the reduction of nucleic acid, loss of myofibril, and disruption of sarcomere structure (Abushouk *et al.*, 2019). So, the enhanced mitochondria-to-myocyte ratio increased the susceptibility of cardio myocyte to oxidative stress and proposed a main factor in pathogenesis that can be compared with the aforementioned mechanisms. DOX-semiquinone is an unstable DOX metabolite which combines with Oxygen (O_2) molecule to produce H_2O_2 and O_2^- (superoxide) (Abdel-Daim *et al.*, 2017). DOX also increases the quantity of extra mitochondrial oxidative enzymes e.g., xanthine and NADPH oxidase. It also inhibits mitochondrial iron export, that results in the production of Reactive Oxygen Species (ROS). DOX also prevents the functions of endogenous non-enzymatic and enzymatic antioxidants. So, an imbalance occurs between the production of ROS and neutralization that causes oxidative stress and cause a great damage to heart compared with other organs including kidney and liver (Abushouk *et al.*, 2017).

Importance of herbal medicines in the cure of different diseases is accepted worldwide. Herbal medicines always provide essential therapeutic agents not only in traditional but also in modern medicines and also because they are less toxic than synthetic medicines (Vakiloddin *et al.*, 2015). *Citrullus colocynthis* is a medicinal plant belongs to the family *Cucurbitaceae*. It has a lot of environmental benefits, such as mosquito repellent and larvicidal potential (Rahuman *et al.*, 2008). Its oils are also used as botanical insecticides for the prevention of smoke-dried fish from *D. maculatus* larvae attack (Akpotu *et al.*, 2015). Its shoots are used as bio-indicators and soil pollution accumulator (Khattak *et al.*, 2015). In Arab, it was used to deal with the skin eruption in camels and for insect bites (Thangavel and Ramasamy, 2019). Traditionally, it was used to treat asthma, cough, edema, constipation (Delazar *et al.*, 2006). Its fruit is used as hepatoprotective (Vakiloddin *et al.*, 2015), and its pulp and seeds as an anti-inflammatory and diabetes (Nmila *et al.*, 2000; Marzouk *et al.*, 2010). Till now there is no recorded experimental foundation

for its utilization as a cardio protective agent. The current research was performed to evaluate the cardio protective potential of hydro alcoholic leaf extract of *C. colocynthis* against DOX-induced oxidative stress.

MATERIALS AND METHODS

Authentication and preparation of plant extract

C. colocynthis leaves were taken from the botanical garden of Muhammad Institute of Medical and Allied Sciences, Multan. It was authenticated by an expert taxonomist at the Department of Botany, Bahauddin Zakariya University, Multan. The voucher specimen (R.R. Stewart F.W. Pak.702/20) had been placed. The fresh plant was subjected to shade dry. All the foreign adulterants and vegetative wastes were eliminated through manual picking before grinding the leaf part of the plant into a coarse powder with the assistance of a special herbal grinder. *C. colocynthis* 1kg leaf powder was soaked in a hydroalcoholic solvent (70:30 v/v) for 9 days in amber colored air-tight bottles. Then, it was filtered and the filtrate was evaporated at 37°C under reduced pressure on a rotatory evaporator (specification of rotatory) to obtain a thick paste-like consistency (Bashyal and Guha, 2018).

Animals

Male Wister albino rats, weighing 350-400g, obtained from animal house of Muhammad Institute of Medical and Allied Sciences, Multan. The rats were kept at Fatima-Tu-Zahra, Department of Life Sciences, Muhammad Institute of Medical and Allied Sciences, Multan under 12 h dark and light cycle. All the rats were given standard pallet diet and with water *ad libitum*. The standard temperature 25°C and humidity 50-60% conditions were maintained. The experiments were performed according to the guidelines issued by the National Institute of Health guide for the care and use of laboratory animals (NIH, 1985) and approved by the Ethical Review Committee of Muhammad Institute of Medical and Allied Science Multan, Pakistan (MIMAS/03/Biochem/315/20).

Chemicals

Doxorubicin, dexrazoxane, ethanol, distilled water was obtained from M/s. Sigma Chemical Company, St. Louis. MO USA. The rest of the chemicals employed in the research project were of analytical quality. AST, ALP, ALT, LDH, CRPK it's were obtained from GS Chemicals and diagnostics, Multan.

Acute oral toxicity dose test

The acute oral toxicity of the extract was evaluated in 15 albino rats weighing 350- 450g. They were divided into

3 groups and each group contained 5 albino rats and they were kept on fasting for 24 h and dosed in the following manner 2000mg/kg, 4000mg/kg, 6000mg/kg body weight. After the dosing, the rats were noticed for 14 days for lethargy, jerkiness and death (Thippeswamy *et al.*, 2011).

Preliminary phytochemical screening

The absence or presence of various phytochemical classes in *C. colocynthis* leaf extract was determined using standard phytochemical screening procedures (Thippeswamy *et al.*, 2011).

Determination of DPPH radical scavenging activity

The antioxidant activity of hydro alcoholic leaf extract of *C. colocynthis* was performed on the base of scavenging activity of stable DPPH (1, 1-diphenyl-1-picrylhydrazyl) radical. 0.5ml plant extract was taken in a sample cavity that contained 3.5ml of methanol solution of DPPH (0.004g/100ml⁻¹). The mixture was incubated for 30 min in the darkness and room temperature and absorbance was measured at 517 nm. The percent inhibition DPPH (I%) was measured by decline in absorbance using the following formula. Low absorbance value represents higher free radical scavenging activity (Ahmed *et al.*, 2019).

$$I\% = \frac{A_{\text{blank}} - A_{\text{sample}}}{A_{\text{blank}}} \times 100$$

A_{blank} = Absorbance of control

A_{sample} = Absorbance of sample

Determination of reactive oxygen species

The reactive oxygen species (NO and H₂O₂) were detected by standard methods described by Garrat (1964).

Assay of nitric oxide radical scavenging

Nitric oxide produced from aqueous sodium nitroprusside (SNP) reacts with oxygen at physiological pH to create nitrite ions measured by the Illosvoy Griess reaction. 10 mM SNP, buffered saline (pH 7.4) and varied amounts of test solution were all mixed in a 3-mL reaction mixture. Sulfanilamide (0.33% in 20% glacial acetic acid) was added to 0.5mL of the incubated solution, which was allowed to stand for 5 min before 0.5mL of 0.1M triethanolamine was added and the mixture incubated for a further 75 min at 25°C. 0.1% w/v of NED solution was added and the mixture was incubated for 30 min at 25 degrees Celsius.

Hydrogen peroxide scavenging assay

According to the approach of Ruch *et al.* (1989) the capability of the extract to scavenge hydrogen peroxide (H₂O₂) was examined. 0.1 microliters of each of the samples was put into a sterile Eppendorf tube, and the tube was

half-filled with 50 mM phosphate buffer (pH 7.4) to make the total volume up to 0.4 mL. This was followed by the addition of 0.6 microliters of H₂O₂ solution (2 mM). After 10 min of reaction time, the liquid was vortexed and the absorbance was measured at 532 nm. Ascorbic acid was selected as the positive control, since it has antiscorbutic properties. The results of the test and standard sample were compared to calculate percentage inhibition.

Experimental design

The animals had been divided into 5 major groups each group contained 8 rats. Group-1 rats were given saline for 2 weeks and on 11th day DOX 18mg/kg was injected intraperitoneally after 16h fast. Group-2 rats were pre-treated with 250mg/kg of extract for a time of 2 weeks, and besides administrated DOX 18mg/kg, on the 11th day after 16 h fast. The rats of Group-3 were pre-treated with 500mg/kg of extract for 2 weeks consecutively and on the 11th, day DOX 18mg/kg was administrated intraperitoneally after 16 h fast. In preliminary screening we found 500mg/kg dose significant so that's why we used upper and lower limit. Group-4 rats were pre-treated with extract in an amount of 750 mg/kg for 2 weeks orally and on the 11th, day DOX 18mg/kg was inoculated intraperitoneally after 16 h fast. Group-5 was the positive control and they were given 30 min before the inoculation of DOX 18mg/kg dexrazoxane (DZR) was administrated intraperitoneally 180 mg/kg after 16 h fast (Sandamali *et al.*, 2020).

Histopathology of heart

After the final dose of DOX, rats had been anesthetized by ketamine and the blood samples of rats had been taken from the retroorbital vein to assess the biochemical parameters including CK-MB, LDH, troponin-I, CRP, ALT, AST and ALP levels in serum were measured by commercially available Kits. Rats had been killed under intense anesthesia by Ketamine and the heart was isolated and for histological examination, then the heart swiftly transferred to a 10 % formalin solution. After that tissue had been submerged in the paraffin. A 5µm thick segment had been cut and stained with a hematoxylin-eosin dye then mounted in the diphenyl xyline. The histopathology of cardiac muscle had been determined beneath a compound microscope and micro-images had been taken (Sandamali *et al.*, 2020).

Statistical analysis

The experimental statistics had been demonstrated as mean ± SD. Statistical analysis had been accomplished through one-way ANOVA. The statistical value with $p < 0.05$ was taken as significant.

RESULTS

Acute oral toxicity

The acute oral toxicity test showed that any dose of hydro alcoholic leaf extract of *C. colocynthis* up to 6000 mg/kg did not yield any mortality.

Phytochemical analysis

Phytochemical analysis indicated presence of steroids, flavonoids, saponins, tannins, phenols, alkaloids and glycosides in extract while, terpenoids and flavones were absent in the extract.

DPPH activity

C. colocynthis showed outstanding antioxidant activity when compared with standard Ascorbic acid shown in Figure 1.

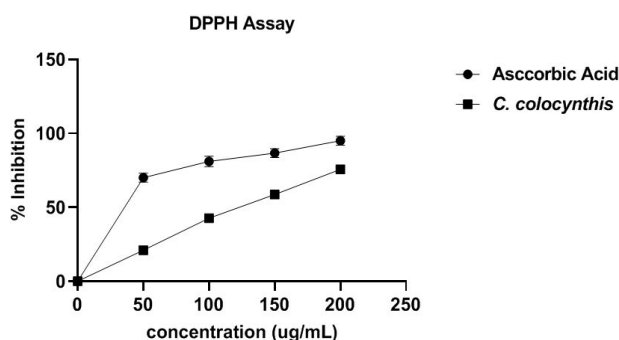


Fig. 1. Scavenging activity of leaf extract of *C. colocynthis* and Ascorbic acid on DPPH.

Estimation of biochemical parameters

Biochemical estimations showed a highly significant ($p < 0.001$) rise in the level of AST, ALP, ALT, CKMB, CRP, troponin-I, LDH in DOX treated group in comparison with extract-treated Group-2, Group-3, Group-4 and DZR treated Group-5. As shown in Figure 2. Group-2 rats pretreated with 250mg/kg for 14 successive days did not show any cardioprotective activity ($p > 0.05$) and there was a very mild decrease in the levels of biochemical parameters. Group-3 rats pretreated with the extract 500mg/kg for 14 successive days showed a significant decrease ($p < 0.05$) in the level of biochemical parameters. There was a mild to moderate reduction in the biochemical parameters. Group-4 rats pretreated with extract 750mg/kg for 14 successive days and Group-5 which was given DZR showed a highly significant ($p < 0.001$) reduction in diagnostic biomarkers and cardiac parameters of myocardial injury and maintained the biochemical parameters near to normal level. The positive control was

dexrazoxane, which is the only protective drug utilized in medical practice for the treatment of DOX-induced oxidative damage. Although there was a highly significant difference ($p < 0.001$) among the DOX-induced group and the positive control and the extract pre-treated groups at various doses.

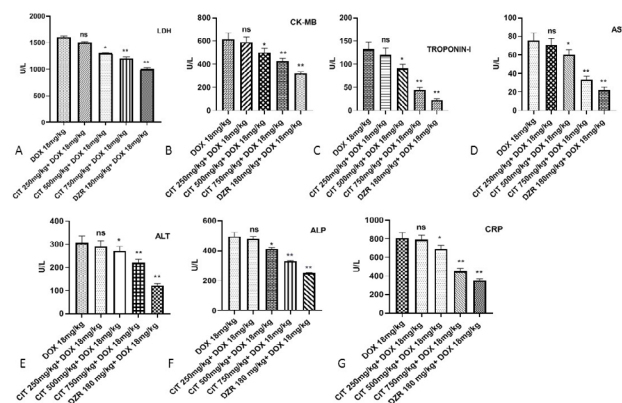


Fig. 2. Effect of hydroalcoholic leaf extract of *Citrullus colocynthis* on level of oxidative stress in different markers in heart tissues. A, LDH; B, CK-MB; C, troponin-I; D, AST; E, ALT; F, ALP; G, CRP. ^{ns} ($p > 0.05$) did not show any significant reduction. * ($p < 0.05$) showed significant reduction, ** ($p < 0.001$) showed highly significant reduction.

Determination of reactive oxygen species

The findings of the nitric oxide-enhancing properties of *C. colocynthis* revealed significant increases in the nitric oxide scavenging capability of the extract. Maximum activity was seen at 6000µg/ml of the plant extract. When the plant extract concentration increases, the activity of the hydrogen peroxide scavenging increases, the highest concentration at 6000µg/ml has been reported, while the lowest concentration at 2000µg/ml has been recorded as shown in Table I.

Table I. Results of Reactive oxygen species scavenging of *C. colocynthis* extract with standard.

Concentration (µg/ml)	Inhibition of the extract		Inhibition of the standard	
	Nitric oxide	H ₂ O ₂	Nitric oxide	H ₂ O ₂
2000	31	31	35.9	33
4000	41.6	39	48.6	42
6000	53.8	53	58.8	58.6

Histopathological observation of heart tissues

Microscopic observation of the heart tissues from different groups was used to evaluate the DOX injection effect on the cardiac cells structure as well as its variation by the drug test inoculation. Microscopic analysis of heart tissues in the DOX-induced group showed a remarkable change in cardiac cell structure. Such as mono-nucleate cellular infiltration, interstitial edema, disintegration tear of muscular fibers, vacuolar disintegration, distention of capillaries, mottled staining, hemorrhage, and obstruction of the myocardium were observed as shown in Figure 3A. Severe necrotic lesions were noticed in all the rats while, Plant extract treated groups observed decreased histopathological variations in dose dependent fashion as shown in Figure 3B, D. The DZR treated group also showed reduced histopathological variations as shown in Figure 3E (Thippeswamy *et al.*, 2011).

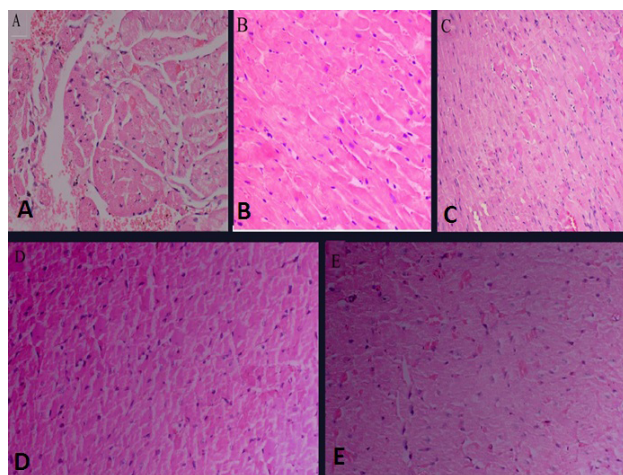


Fig. 3. (A) Effect of hydroalcoholic leaf extract on histological structure of rats. Heart section from DOX-induced group (B) shows images from heart sections of Extract 250mg/kg + DOX 18mg/kg (C) shows images from heart sections of extract 500 mg/kg + DOX 18mg/kg (D) Shows heart sections from Extract 750mg/kg + DOX 18mg/kg (E) shows images from heart sections of DZR 180mg/kg + DOX 18mg/kg.

DISCUSSION

Phospholipids that are present in the membranes of mitochondria have high affinity for DOX and when DOX induces it accumulates in the heart cells and causes several changes in function and structure of cardiac tissues (El-Sayed *et al.*, 2011). The enhanced mitochondria to myocyte ratio increased the susceptibility of cardiomyocytes to oxidative stress and proposed a main factor in pathogenesis

compared with the aforementioned mechanisms. DOX-semiquinone is an unstable DOX metabolite which combines with oxygen (O_2) molecule to produce H_2O_2 and $O_2^{\cdot-}$ (superoxide). DOX also increases the quantity of extra mitochondrial oxidative enzymes e.g., xanthine and NADPH oxidase. It also inhibits mitochondrial iron export that results in the production of Reactive Oxygen Species (ROS). DOX also prevents the functions of endogenous non-enzymatic and enzymatic antioxidants. So, an imbalance occurs between the production of ROS and neutralization that causes oxidative stress and cause a great damage to heart compared with other organs including kidney and liver (Abushouk *et al.*, 2017). Phytochemical screening and antioxidant activity of leaf extract of *C. colocynthis* showed that it contains glycosides, flavonoids, saponins, alkaloids, steroids, phenols and tannins. These phytochemicals might be responsible for reducing the oxidative stress caused by DOX which is a major contributor to change in cardiac tissue physiology.

The whole concentration of the marker enzyme LDH and CKMB of rats pre-treated with the DOX showed a highly significantly increase ($p < 0.001$). Groups pretreated with *C. colocynthis* leaf extract decreased the LDH and CKMB level in a dose-dependent fashion, parallel to group pretreated with DZR showed a highly significant reduction in the level of LDH and CKMB as compared to Group-1 (as shown in Fig. 2A, B). This indicates that *C. colocynthis* pretreated groups showed restriction against the myocardial damage due to oxidative stress caused by DOX which results in less leakage of CKMB and LDH from the myocardium similar to previous studies published against same topic.

The whole concentration of the marker enzyme troponin-I (as shown in Fig. 2C) that is considered as a specific biomarker in the dysfunction of left ventricular portion of heart (as shown in Fig. 2C) of rats were pretreated with the DOX showed a highly significant ($p < 0.001$) increased value, in contrast *C. colocynthis* extract pretreated groups decreases the troponin-I level in a dose-dependent way. Which confirms its cardioprotective potential by resisting the oxidative stress and tissue damage caused by DOX (Table I). Pretreatment with DZR showed a highly significant ($p < 0.001$) reduction in the troponin-I level as compared to Group-1. The mean concentration of the serum parameter AST (as shown in Fig. 2D) which is considered as a specific marker indicates the damage of cardiomyocytes cell membrane damage (as shown in Fig. 2D) of rats pretreated with the DOX showed a highly significant ($p < 0.001$) increased value in Group-1. While *C. colocynthis* extract pretreated groups showed marked resistance against the DOX toxicity which is evident through decreased AST level in dose-dependent

way. Pretreatment with DZR showed a highly significant ($p<0.001$) reduction in the AST level as compared to Group-1.

The mean concentration of the parameter ALT of rats pretreated with the DOX showed a highly significant ($p<0.001$) increase (as shown in Fig. 2E), in contrast, *C. colocynthis* extract decreased the level in dose-dependent way in all three treated groups parallel to DZR pretreated group which showed a highly significant ($p<0.001$) reduction in the ALT level.

The mean concentration of parameter ALP of rats pretreated with the DOX showed a highly significant increased value in contrast to this, *C. colocynthis* extract pretreated groups showed decreased ALP level in a dose-dependent fashion, similar to group pretreatment with DZR showed a highly significant ($p<0.001$) reduction in ALP level (Fig. 2F). So many previous studies showed that plant with antioxidant potential produced cardioprotection by decreasing the level of ALP, AST and ALT in DOX induced toxicity (Momin *et al.*, 2012).

The mean concentration of parameter CRP of rats pretreated with the DOX showed a highly significant increased value in contrast to this, *C. colocynthis* extract pretreated groups showed decreased CRP level in a dose-dependent fashion, similar to group pretreated with DZR showed a highly significant ($p<0.001$) reduction in CRP level (Fig. 2G). As the oxidative damage caused by DOX results in the inflammatory process in the myocardial tissue damage and cell necrosis. It is well documented in so many previous studies that the stressed area undergoes local necrosis, generation of free radicals which ends in apoptosis of cardio myocytes (Wang *et al.*, 2019). This is followed by infiltration of neutrophils and macrophages into the stressed area, initiating myocardial cell damage by releasing the cytokines and proteolytic enzymes. Pretreatment with *C. colocynthis* extract showed marked decrease in the serum levels of CRP which advocates its cardio protective potential. *C. colocynthis* leaf extract reported for good anti-inflammatory activity (Rahuman *et al.*, 2008), which further strengthen this claim.

Histological variation resembled the rise in serum enzyme level. Histopathology of the ventricular portion of the heart from DOX treated group showed mitochondrial swelling, dilation of the sarcotubular system, disruption of several sub-cellular elements including formation of lysosomal bodies, vacuolization of the cytoplasm, loss of myofibrils. In Group-4, treatment with the hydroalcoholic leaf extract of *C. colocynthis* showed less vacuolization of the cytoplasm and disruption of the myofibrils. This further confirms the membrane stabilizing effect of the extract. *C. colocynthis* offered cardio protection by decreasing oxidative stress-induced in experimental myocardial

infarction by preventing the free radical-mediated damage of DOX assault (Wang *et al.*, 2019).

CONCLUSIONS

Hydroalcoholic leaf extract of *Citrullus colocynthis* showed cardioprotective potential by decreasing the DOX induced oxidative stress in rats may be due to its strong antioxidant potential that is evident from the amelioration of histological variations as well as by the estimation of various cardiac biomarkers.

ACKNOWLEDGMENTS

The authors are extremely thankful to Dr. Noshaba Kanwal, Lecturer, Muhammad Institute of Medical and Allied Sciences for her valuable suggestions throughout the experiment.

Statement of conflict of interest

The authors have declared no conflict interest.

REFERENCES

- Abdel-Daim, M.M., Khalifa, H.A. and Ahmed, A.A., 2017. Allicin ameliorates doxorubicin-induced cardiotoxicity in rats via suppression of oxidative stress, inflammation and apoptosis. *Cancer Chemother. Pharmacol.*, **80**: 745-753. <https://doi.org/10.1007/s00280-017-3413-7>
- Abushouk, A.I., Ismail, A., Salem, A.M.A., Afifi, A.M. and Abdel-Daim, M.M., 2017. Cardioprotective mechanisms of phytochemicals against doxorubicin-induced cardiotoxicity. *Biomed. Pharmacother.*, **90**: 935-946. <https://doi.org/10.1016/j.biopha.2017.04.033>
- Abushouk, A.I., Salem, A.M.A., Saad, A., Afifi, A.M., Afify, A.Y., Afify, H., Salem, H.S., Ghanem, E. and Abdel-Daim, M.M., 2019. Mesenchymal stem cell therapy for doxorubicin-induced cardiomyopathy: Potential mechanisms, governing factors, and implications of the heart stem cell debate. *Front. Pharmacol.*, **10**: 635. <https://doi.org/10.3389/fphar.2019.00635>
- Ahmed, M., Ji, M., Qin, P., Gu, Z., Liu, Y., Sikandar, A., Iqbal, M. and Javeed, A., 2019. Phytochemical screening, total phenolic and flavonoids contents and antioxidant activities of *Citrullus colocynthis* L. and *Cannabis sativa* L. *Appl. Ecol. environ. Res.*, **17**: 6961-6979. https://doi.org/10.15666/aeer/1703_69616979

- Akpotu, O.J., Oniye, S.J., Abolude, D. and Yusuf, A., 2015. Comparative study of the toxicity of oils from seeds of *Citrullus colocynthis* and *Citrullus vulgaris* on larvae of dermestes maculatus. *Fish. Res.*, **3**: 6-12. <https://doi.org/10.3153/JAEFR17002>
- Bashyal, S. and Guha, A., 2018. Evaluation of *Trachyspermum ammi* seeds for antimicrobial activity and phytochemical analysis. *Evaluation*, **11**: 274-277. <https://doi.org/10.22159/ajpcr.2018.v11i5.24430>
- Curigliano, G., Mayer, E.L., Burstein, H.J., Winer, E.P. and Goldhirsch, A., 2010. Cardiac toxicity from systemic cancer therapy: A comprehensive review. *Prog. Cardiovasc. Dis.*, **53**: 94-104. <https://doi.org/10.1016/j.pcad.2010.05.006>
- Delazar, A., Gibbons, S., Kosari, A.R., Nazemiyeh, H., Modarresi, M., Nahar, L. and Sarker, S.D., 2006. Flavone C-glycosides and cucurbitacin glycosides from *Citrullus colocynthis*. *Daru*, **14**: 109-114.
- El-Sayed, E.M., Abd El-Azeem, A.S., Afify, A.A., Shabana, M.H. and Ahmed, H.H., 2011. Cardioprotective effects of *Curcuma longa* L. extracts against doxorubicin-induced cardiotoxicity in rats. *J. Med. Pl. Res.*, **5**: 4049-4058.
- Garrat, D.C., 1964. *The quantitative analysis of drugs*. Chapman and Hall, Tokyo, Japan. https://doi.org/10.1007/978-1-4613-3380-7_1
- Gharib, M. and Burnett, A.K., 2002. Chemotherapy-induced cardiotoxicity: Current practice and prospects of prophylaxis. *Eur. J. Heart Fail.*, **4**: 235-242. [https://doi.org/10.1016/S1388-9842\(01\)00201-X](https://doi.org/10.1016/S1388-9842(01)00201-X)
- Health, N., 1985. *Guide for the care and use of laboratory animals*. National Academies. publication No. 85-23 Bethesda, USA
- Ibrahim, M.A., Morsy, M.A., Hafez, H.M., Gomaa, W.M. and Abdelrahman, A.M., 2012. Effect of selective and non-selective cyclooxygenase inhibitors on doxorubicin-induced cardiotoxicity and nephrotoxicity in rats. *Toxicol. Mech. Methods*, **22**: 424-431. <https://doi.org/10.3109/15376516.2012.666658>
- Khattak, M.I., Jabeen, R., Hameed, M. and Arfat, Y., 2015. A study of some heavy metals found in medicinal plants (*Euphorbia cornigera*, *Rhazya stricta* and *Citrullus colocynthis*) in Turbat region of Balochistan with reference to prevention of environmental pollution. *Pak. J. Bot.*, **47**: 1511-1516.
- Marzouk, B., Marzouk, Z., Haloui, E., Fenina, N., Bouraoui, A. and Aouni, M., 2010. Screening of analgesic and anti-inflammatory activities of *Citrullus colocynthis* from southern Tunisia. *J. Ethnopharmacol.*, **128**: 15-19. <https://doi.org/10.1016/j.jep.2009.11.027>
- NIH (National Institute of Health), 1985. *Guide for the care and use of laboratory animals*. NIH publication no. 85-23, Bethesda, USA.
- Nmila, R., Gross, R., Rchid, H., Roye, M., Manteghetti, M., Petit, P., Tijane, M., Ribes, G. and Sauvaire, Y., 2000. Insulinotropic effect of *Citrullus colocynthis* fruit extracts. *Pl. Med.*, **66**: 418-423. <https://doi.org/10.1055/s-2000-8586>
- Rahuman, A.A., Venkatesan, P. and Gopalakrishnan, G., 2008. Mosquito larvicidal activity of oleic and linoleic acids isolated from *Citrullus colocynthis* (Linn.) Schrad. *Parasitol. Res.*, **103**: 1383-1390. <https://doi.org/10.1007/s00436-008-1146-6>
- Rivankar, S., 2014. An overview of doxorubicin formulations in cancer therapy. *J. Cancer Res. Ther.*, **10**: 853. <https://doi.org/10.4103/0973-1482.139267>
- Ruch, R.J., Cheng, S.J. and Klaunig, J.E., 1989. Prevention of cytotoxicity and inhibition of intracellular communication by antioxidant catechins isolated from Chinese green tea. *Carcinogenesis*, **10**: 1003-1009.
- Sandamali, J.A., Hewawasam, R.P., Jayatilaka, K.A. and Mudduwa, L.K., 2020. Cardioprotective potential of *Murraya koenigii* (L.) Spreng. leaf extract against doxorubicin-induced cardiotoxicity in rats. *Evid. Based Complement. Altern. Med.*, **2020**: 16. <https://doi.org/10.1155/2020/6023737>
- Slingerland, M., Guchelaar, H.J. and Gelderblom, H., 2012. Liposomal drugformulations in cancer therapy: 15 years along the road. *Drug Discov. Today*, **17**: 160-166. <https://doi.org/10.1016/j.drudis.2011.09.015>
- Thangavel, P. and Ramasamy, R.K., 2019. Phytochemical screening and antibacterial and antifungal activity of the stem, leaf and fruit extracts using different solvent of *Citrullus colocynthis* (L.) Schrad. *J. Pharmacogn. Phytochem.*, **8**: 352-355.
- Thippeswamy, A., Shirodkar, A., Koti, B., Sadiq, A.J., Praveen, D., Swamy, A.V. and Patil, M., 2011. Protective role of *Phyllanthus niruri* extract in doxorubicin-induced myocardial toxicity in rats. *Indian J. Pharmacol.*, **43**: 31. <https://doi.org/10.4103/0253-7613.75663>
- Vakiloddin, S., Fuloria, N., Fuloria, S., Dhanaraj, S.A., Balaji, K. and Karupiah, S., 2015. Evidences of hepatoprotective and antioxidant effect of *Citrullus colocynthis* fruits in paracetamol induced hepatotoxicity. *Pak. J. Pharm. Sci.*, **28**: 951-957.

Wang, Y., Chao, X., Shi, H., Mehboob, H. and Hassan, W., 2019. Phoenix dactylifera protects against doxorubicin-induced cardiotoxicity and nephrotoxicity. *Cardiol. Res. Pract.*, **2019**: 8. <https://doi.org/10.1155/2019/7395239>

Xiong, Y., Liu, X., Lee, C.P., Chua, B.H. and Ho,

Y.S., 2006. Attenuation of doxorubicin-induced contractile and mitochondrial dysfunction in mouse heart by cellular glutathione peroxidase. *Free Radic. Biol. Med.*, **41**: 46-55. <https://doi.org/10.1016/j.freeradbiomed.2006.02.024>