



Review Article

An Overview of Bovine Cystic Ovarian Disease

Abdullah Channo^{1*}, Asmatullah Kaka¹, Qudratullah Kalwar², Imdadullah Jamali³, Ghulam Jelani², Muhammad Bakhsh⁴, Ghulam Nabi Dahri⁵ and Jai Parkash Goil⁶

¹Department of Animal Reproduction, Faculty of Animal Husbandry and Veterinary Sciences, Sindh Agriculture University, Tandojam, 70060

²Shaheed Benazir Bhutto University of Veterinary and Animal Sciences, Sakrand, 67210

³Department of Veterinary Pathology, Faculty of Animal Husbandry and Veterinary Sciences, Sindh Agriculture University, Tandojam, 70060

⁴Faculty of Veterinary Sciences, College of Veterinary and Animal Sciences, Jhang, 35200, UVAS Lahore, Pakistan

⁵Directorate of Animal Husbandry, Livestock and Fisheries Department, Hyderabad, Government of Sindh.

⁶Department of Animal Breeding, Livestock and Fisheries Department, Hyderabad, Government of Sindh

ABSTRACT

Dairy animals are facing so many reproductive disorders and cystic ovarian disease (COD) is one of the important disease which cause major economic losses to farmers. COD affects fertility of animal which is important to reproduce young ones, that occurs due to negative impact factors on hypothalamus-pituitary stalk and normal function of the ovary which leads to alteration in follicular development, ovulation, reduced reproductive performance, unsuccessful ovulation, increased interval between parturition and conception, low conception rate, decrease in calving rate, increase in number of inseminations at each conception and finally culling. The incidence of COD is ranges from 5-30%, due to the improper management system, and the prevalence of COD is 10-13% which is associated with selection, heredity, age, environment, improper nutrition, herd size, housing, high milk production, body condition score, lactation period, seasons, retained placenta, stress, metabolic disorders and hormonal imbalance. COD is generally at highest from 30 to 60 days of postpartum. The exact pathogenesis of COD is still not confirmed, but the abnormal neuroendocrine reflex of hypothalamic pituitary dysfunction, molecular alteration in growing follicle are important components. COD has been diagnosed by animal behavioral changes, nymphomania, anestrus, repeat breeding, pelvic ligament relaxation, tails head elevation, determination of progesterone level in plasma and milk by using kits of progesterone assay, and to confirm the diagnosis of COD, mostly trans rectal palpation and trans rectal ultrasonography methods have been used. COD should be treated by using different treatment protocols such as hormonal, medicinal and homeopathic medicines.

Article Information

Received 05 September 2021

Revised 03 December 2021

Accepted 15 December 2021

Available online 16 March 2022

(early access)

Published 15 July 2022

Authors' Contribution

AC, IJ and GJ write manuscript. AK and QK guidelines and support. MB and IJ helped in the treatment write-up.

Key words

Cystic ovarian disease, Infertility, Hormonal imbalance, Endocrine reproductive disorder, Treatment

INTRODUCTION

The fertility of animals is necessary for reproduction and it depends on the neuroendocrine function. Many factors affect the hypothalamus, pituitary, and ovary function that causes decrease infertility outcomes (Kovács *et al.*, 2020). In good-yielding dairy animals,

alteration infertility occurs by the reproductive disorder (mainly normal ovarian activity) (Mimoun *et al.*, 2020; Szenci *et al.*, 2018). The reproductive disease of animals increases the calving interval, low conception rate, improper sexual behavior that causes high economic loss of industrial and non-industrial farms (Cattaneo *et al.*, 2014). In dairy animals, cystic ovarian disease (COD) is an influential reproductive dysfunction (Yimer *et al.*, 2018). It has been reported in several species of animal such as ruminants, humans, bitches and rodents (Francou *et al.*, 2008). COD is an exceeding reproductive disorder that causes a prolonged open period after parturition (Gobikrushanth *et al.*, 2016). In high producing animals, COD causes subfertility, increasing postpartum open periods, and reduced reproductive performance that causes huge economic loss in the dairy industry (Ortega *et al.*,

* Corresponding author: studentchanna@gmail.com
0030-9923/2022/0005-2437 \$ 9.00/0



Copyright 2022 by the authors. Licensee Zoological Society of Pakistan.

This article is an open access article distributed under the terms and conditions of the Creative Commons Attribution (CC BY) license (<https://creativecommons.org/licenses/by/4.0/>).

2015; Garverick, 1997; Stassi *et al.*, 2019; Sayad *et al.*, 2019; Kesler and Garverick, 1982; Xu *et al.*, 2021). The frequency of COD in cattle ranges from 5-30% in all reproductive diseases (Silvia *et al.*, 2005).

Reproductive disorder cystic ovarian degeneration has 10-13% prevalence that affects on the fertility level and causes high economic loss (Johnson and Coates, 2004). In 60% of cows follicular cyst develops before first ovulation and as parturition occurs (Peter, 2004; Mimoune *et al.*, 2019). Alteration in normal ovulation and follicular development occurs by cystic ovarian (Ortega *et al.*, 2016). Anovulation of dominant follicle occurred by cystic structure on ovary that interfere with normal ovarian function during estrous cycle (Peter, 2004; Ortega *et al.*, 2015; Stassi *et al.*, 2019). Ovarian cyst is a bladder-like watery-filled structure of about 25mm on ovary that remains for more than 10 days (Lüttgenau *et al.*, 2016; Mimoune *et al.*, 2020; Coleman, 2008; Polat *et al.*, 2015). On ovary, one or more ovarian cyst (follicular and luteal) with size greater than 20mm in diameter in lack of corpus luteum formation. The wall of follicular cyst is less than 3mm and greater than 3mm in luteal cyst (Lüttgenau *et al.*, 2016; Todoroki *et al.*, 2001; Vanholder *et al.*, 2006). The diagnosis of follicular and luteal cyst is very difficult in field condition (Probo *et al.*, 2011; Gaebler *et al.*, 2015). Heredity, body condition score, lactation period, seasonality effect, phytoestrogen, milk fever, metritis and retention of fetal membrane are included as the cause in the occurrence of COD (Cattaneo *et al.*, 2014). Vanholder *et al.* (2006) have reported the relationship in between the mechanism of postpartum COD and endometritis. Plasma progesterone concentration in follicular cyst is less than 1ng/ml, whereas in luteal cyst it is greater than 1ng/ml (Vanholder *et al.*, 2006). Recently it is reported that in case of follicular cyst in cows, serum progesterone and estradiol concentration is 0-1ng/ml and 0-5pg/ml while its range is 8-9ng/ml and 15-20pg/ml in luteal cyst (Brodzki *et al.*, 2019).

The basic purpose of this review is to reveal about COD incidence, economic loss, causes, manage mental techniques of the basic reproductive disorder that cause low production of animals in milk, meat etc.

INCIDENCE OF CYSTIC OVARIAN DISEASE

The COD incidence in milking animals has been reported from 5% to 30%, which are occurred due to improper management system, the prevalence of this disease occurred is mostly associated with heredity, age, high milk production, body condition score, lactation period, seasons, retained placenta, stress, metabolic disorders and hormonal imbalance (Cattaneo *et al.*,

2014). COD is generally at highest from 30 to 60 days of postpartum (Kim *et al.*, 2005). COD has occurred with increases of parity which may be associated with physiological and pathological conditions which leads to an increase in parity, such as parturient paresis or milk fever (Fleischer *et al.*, 2001). Another incidence is the selection, because most of farmers choose high milk yield animals which affects genetics and its surrounding environment may also lead to COD mostly in last lactation (Vanholder *et al.*, 2006). Herd size and housing may produce negative impact on the reproduction of animals and lead to COD because of limitations in their natural performance in herds such as in free stalls (Simensen *et al.*, 2010; Nelson *et al.*, 2010). Seasons such as in autumn and winter calving season, the occurrence of COD is higher as compared to spring and summer calving season (Peter, 2004; Cattaneo *et al.*, 2014). Nutritional management, stress, infectious diseases, decrease level of insulin in blood and increase level of blood cortisol which leads to COD (Jafari *et al.*, 2015; Silvia *et al.*, 2002). Decreased level or absence of luteinizing hormone (LH) may also lead to the occurrence of COD (Mimoune *et al.*, 2019).

PATHOGENESIS

Due to complex disorder and clinical signs, exact pathogenesis of COD is unknown (Vanholder *et al.*, 2006). In COD, pathogenesis depends on the abnormality in neuroendocrine reflex of the hypothalamic pituitary gonadal axis (Noakes *et al.*, 2001; Scully *et al.*, 2021). And also in COD pathogenesis, molecular alteration in growing follicle is key component (Çolakoğlu *et al.*, 2021; Stassi *et al.*, 2019). It is difficult to differentiate in follicular and luteal cyst diagnosis in field condition so GnRH over prostaglandin recommended for treatment (Bors *et al.*, 2018).

Hypothalamic-pituitary dysfunction

Hypothalamic-pituitary gonadal axis has a great role to maintain endocrine balance for normal follicular growth, rupture of the follicle and ovulation at a time (Marelli, 2014). For ovulations, a reproductive mother hormone gonadotropin-releasing hormone (GnRH) causes discharge of luteinizing hormone (LH). While, granulosa cells, inflammatory process and dysfunction of follicle cellular components have key role in cyst formation (Silvia *et al.*, 2002; Yoshioka *et al.*, 1996; Matiller *et al.*, 2014; Baravalle *et al.*, 2015). In COD hypothalamus show an unusual response by releasing of high estradiol by which concentration of progesterone in blood circulation is increased (Diaz *et al.*, 2015). By endogenous and exogenous factor hormonal imbalance of hypothalamic-pituitary gonadal axis occur

that formed the ovarian cyst (Silva *et al.*, 2002; Cook *et al.*, 1991; Xu *et al.*, 2021). Alteration of preovulatory LH surge from hypothalamus-pituitary dysfunction leads to the formation of cyst on dominant follicle (Yoshioka *et al.*, 1996; Vanholder *et al.*, 2005). During follicular growth follicle are not able to ovulate then an unusual response of estradiol feedback from hypothalamus occurs and that results in cyst formation (Giimen and Wiltbank, 2002; Vanholder *et al.*, 2006). Cystic follicle have less reactive oxygen species (ROS) comparison to normally ovulating follicles for inflammatory reactions during ovulation (Rizzo *et al.*, 2009).

Ovarian/ follicular dysfunction

In cyst formation, alteration in preovulatory LH surge and steroid hormone production have great role (Mimoun *et al.*, 2017). Lack of LH receptors in granulosa cells and theca cell of ovary and irregular response of follicular cells to the preovulatory LH surge is included in cyst formation (Shimizu *et al.*, 2018). In cyst formation leutinizinghormone have great role. By the absence of preovulatory LH surge, alteration in maturation of dominant follicle occurred that altered to cyst formation (Lima *et al.*, 2019; Yoshioka *et al.*, 1996). Intermediate progesterone concentration in blood circulation can cause cystic ovaries (Silva *et al.*, 2002; Hatler *et al.*, 2003; Dhara and Sharma, 2019). Hormonal receptors have a key role for the hormone to perform the function at proper cite (Robker *et al.*, 2000). Lack of steroid receptor (follicle-stimulating hormone receptor, estrogen receptor, leutinizing hormone receptor) is included in the molecular pathogenesis of bovine ovarian cyst (Marelli *et al.*, 2014; Salvetti *et al.*, 2010). Negative energy balance occurs by imbalance of energy intake and production that effects on ovarian function by hormonal and metabolic alteration can cause COD (Opsomer *et al.*, 2000). Low insulin-like growth factor-1 and insulin in early days after parturition results in an-ovulation and cystic ovarian follicular development (Zulu *et al.*, 2002; Vanholder *et al.*, 2005) (Fig. 1).

Losses due to COD

The main loss that occurred due to COD is a reduction in reproductive performance which affectsthe fertility of animals by disturbing the normal ovarian cycle, failure of successful ovulation, increased interval between parturition and conception (Isobe, 2007), low conception rate, decrease in calving rate, increase in number of inseminations at each conception and because of this condition animals have been eliminated by culling from the herd which leads to financial loss to farmers (Sayad *et al.*, 2019; Ismail *et al.*, 2017; Hooijer *et al.*, 2001).

DIAGNOSIS

The fertility of the dairy animals in the postpartum period is very important in terms of economics and dairy herd management. In this period, COD is very common without clear signs and symptoms. COD is one of the most important ovarian disorders, affecting the modern dairy cattle breeds. Most of the time, this disease is diagnosed without obvious signs, in recent times (Vanholder *et al.*, 2006).

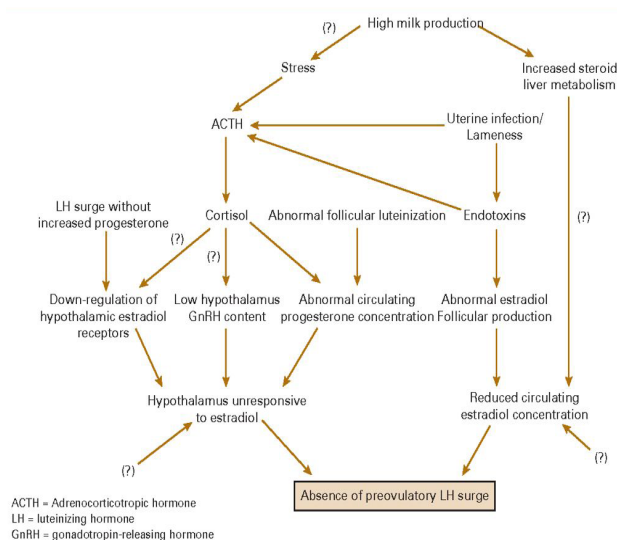


Fig. 1. The pathogenesis of cystic ovarian disease in cattle involves the deficiency of pre-ovulatory surge resulting from interruption in positive feedback outcome of estradiol on hypothalamus. This disturbance is caused by hypothalamic insensitivity or decreased circulating estradiol concentration (Brito and Palmer, 2004).

The diagnosis of COD at farm can be observed by animal behavioral changes, frequent, intermittent, extended or continuous signs of estrus called nymphomania and anestrus, repeat breeding, pelvic ligament relaxation, tails head elevation and in chronic condition masculine characteristics may be observed in bovines (Bartolome *et al.*, 2005; Brito and Palmer, 2004).

The cyst is a fluid-filled structure present on the ovary and can be detected by manual palpation through rectum of the animal. The follicular cysts are thin walled while the luteal cysts are thick. Ovaries can be examined ultrasonographically and a non-echogenic area of at least 25 mm diameter is present there. The follicular cyst has non-echogenic antrum and thin walled <3 mm while the luteal cysts has gray patches within antrum and a wall of <3 mm thick in diameter. An electronic caliper is used to

measure the internal diameters of the cysts (Douthwaite and Dobson, 2000).

For the confirmation and effective diagnosis of COD, Rectal palpation and the trans-rectal ultrasonography have been used and progesterone level in plasma and milk are analyzed by using kits of progesterone assay, mostly veterinarians rely on trans-rectal palpation and trans-rectal ultrasonography in the field with accuracy which ranges from 75-95%. (Borş *et al.*, 2018; Peter, 2004). There is about 74% of follicular cysts and 85% of luteal cysts that could have been interpreted with accuracy by using ultrasonography (Hanzen *et al.*, 2000). The cyst thickness is correlated in plasma progesterone concentration (Peter, 2004). The cyst wall thickness is analysed by using ultrasonography and the size of ovaries is diagnosed by rectal palpation, rectal palpation is the convenient technique which is mostly followed by veterinarians to diagnose COD in animal (Tebble *et al.*, 2001).

TREATMENT OF CYSTIC OVARIAN DISEASE

There are so many efforts that have been taken to treat COD effectively to control financial losses which have been faced by farmers as a result of this disease (Stassi *et al.*, 2019). Before the first postpartum ovulation, about 60 % of the cows recover at their own place (Peter, 1997, 2000; Woolums, 1994; Kesler and Garverick, 1982). Manual rupture, injection of ovarian extract, injection of CL extract, ovariectomy, antibiotics infusion, and injections of adrenaline chloride and pituitrin are some of the oldest forms of treating COD. Administration of GnRH alone usually results in the luteinizing the cyst and the animal shows estrous within 4 weeks. The epidural injection of leirelin (GnRH analog) is good for reproductive improvements (Jeengar *et al.*, 2018).

According to a research report, prostaglandin F2-alpha (PGF2 α) is the most effective treatment and used because of its luteolytic activity and the animal shows estrous signs within 2-3 days (Probo *et al.*, 2011; Brito and Palmer, 2004). In addition, to treat COD ultrasonography should be done to diagnose the type of cyst such as follicular cysts and luteal cysts, the luteal cysts should be better treated by using dinoprost (prostaglandin F2-alpha or PGF2 α) or gonadotrophin releasing hormone (GnRH) analogues, whereas follicular cysts should be better treated by using with buserelin acetate (GnRH) agonist or human chorionic gonadotropin (hCG). At the farm, if an ultrasonography facility would not be available to diagnose the type of ovarian cysts, then mostly gonadotrophin releasing hormone (GnRH) has been recommended to treat COD (Borş *et al.*, 2018; De Rensis *et al.*, 2010).

Furthermore, the COD is treated by giving GnRH followed by giving PGF2 α after 10 days of GnRH, highest recovery of COD has been observed which was about 87% and the pregnancy rate was recorded about 65.21% in treated animals. Mostly farmers culled their animals which are infected by COD, that's why to avoid culling, cases of COD should be treated by applying other treatment procedures such as ovsynch synchronization protocol, Ovsynch+CIDR synchronization protocol and CIDR-GnRH-PGF2 α or potassium iodide which have equal efficacy against COD (Khalil, 2019; Ismail *et al.*, 2017; Bartolome *et al.*, 2005).

Progesterone releasing intra-vaginal devices (PRID) with estradiol-benzoate combination for 12 days are also effective therapy against COD in postpartum animals, whereas instead of PGF2 α , progesterone is mostly used for the process of estrus synchronization after collection of embryo, resulting in the COD developing chances in animal decreased from ~25% to <3%. The suggested drugs dose and protocols are also described in Table I to treat COD (Brito and Palmer, 2004; Hatler *et al.*, 2003; Zulu *et al.*, 2003).

Table I. Drugs, their doses and route for treatment of COD (Teshome *et al.*, 2016).

Drug	Dose	Route
Gonadorelin (GnRH)	100 μ g	IM
Human chorionic gonadotropin (hCG)	10,000 IU	IM
Dinoprost (PGF2 α)	25 mg	IM
Cloprostenol (PGF2 α)	500 μ g	IM
Progesterone	1.9 g	Intravaginal implant

Treatment protocols

- (1) GnRH (or hCG) + PGF2 α (day 0); PGF2 α (day 9 if no estrus)
- (2) Ovsynch: GnRH (day 0); PGF2 α (day 7); GnRH (day 9); fixed-time AI, 16 h after last GnRH treatment
- (3) Progesterone implant for 12 days (not for dairy cows)

COD can be treated by using homeopathic drugs such as homeopathic Apis which is prepared from *Apis mellifica* that is common homeopathic medicine obtained and manufactured from female honeybee, it is used to treat the right side ovarian cyst while homeopathic Lachesis which is prepared from the fresh venom of south American snake called bushmaster, is used to treat left side ovarian cyst, this treatment have been used twice (BID: bis in die) in a day daily for 5 days. Another homeopathic drug homeopathic Natrum Mur which is prepared from sodium chloride, or table salt, which is used twice in a day for 3 days for

effective treatment of COD. In addition, botanical herb called heat seek made 10 tablets can be given orally every other day, twelve doses for 24 days to enhance the estrus signs, while manual rupture of cysts is not recommended because this procedure cause trauma and haemorrhage which leads to a reduction in fertility (Teshome *et al.*, 2016).

CONCLUSION

This review reveals the major reproductive disorder ovarian cyst (follicular and luteal cyst) in a high-yielding dairy animal. It involves the knowledge of molecular factors for the complex pathogenesis of COD. It also helps the clinician to diagnose, manage mental techniques and treatment for COD in cattle. While, strategies to reduce the incidence of postpartum disease mainly ovarian cyst by better management. The different definitions and diagnostic methods used for the pathology are accessible, with the value of each hormonal treatment. This leads the veterinary practitioner to the best therapeutic choices. It also helps to maintain animal body condition score that is the key factor to reduce the metabolic disorder and other reproduction disorders before and after parturition. Further elucidation of the complex pathogenesis of the disease will continue to improve our capacity to prevent, diagnose, and treat COD.

ACKNOWLEDGEMENT

The Author cordially acknowledges to Dr. Asmatullah Kaka (Assistant Professor, Department of Animal Reproduction, Faculty of Animal Husbandry and Veterinary Sciences, Sindh Agriculture University, Tandojam, 70060) and Dr. Qudratullah Kalwar (Assistant Professor, Shaheed Benazir Bhutto University of Veterinary and Animal Sciences Sakrand, 67210) for their kind support and inspiration.

Statement of conflict of interest

The authors have declared no conflict of interest.

REFERENCES

- Baravalle, M.E., Stassi, A.F., Velázquez, M.M.D.L., Belotti, E.M., Rodríguez, F.M., Ortega, H.H. and Salvetti, N.R., 2015. Altered expression of pro-inflammatory cytokines in ovarian follicles of cows with cystic ovarian disease. *J. comp. Pathol.*, **153**: 116-130. <https://doi.org/10.1016/j.jcpa.2015.04.007>
- Bartolome, J.A., Thatcher, W.W., Melendez, P., Risco, C.A. and Archbald, L.F., 2005. Strategies for the diagnosis and treatment of ovarian cysts in dairy cattle. *J. Am. Vet. med. Assoc.*, **227**: 1409-1414. <https://doi.org/10.2460/javma.2005.227.1409>
- Borş, S. I., Ibănescu, I., Creangă, Ş., and Borş, A., 2018. Reproductive performance in dairy cows with cystic ovarian disease after single treatment with buserelin acetate or dinoprost. *J. Vet. med. Sci.*, **80**: 1190-1194. <https://doi.org/10.1292/jvms.17-0690>
- Brito, L. and Palmer, W., 2004. Cystic ovarian disease in cattle. *Lar. Anim. Vet. Rounds*, **4**: 1-6.
- Brodzki, P., Brodzki, A., Krakowski, L., Dąbrowski, R., Szczubiał, M., and Bochniarz, M., 2019. Levels of selected cytokines and acute-phase proteins in the serum of dairy cows with cystic ovarian disease and those in follicular and luteal phases of normal ovarian cycle. *Res. Vet. Sci.*, **123**: 20–25. <https://doi.org/10.1016/j.rvsc.2018.12.007>
- Cattáneo, L., Signorini, M.L., Bertoli, J., Bartolomé, J.A., Gareis, N.C., Díaz, P.U., and Ortega, H.H., 2014. Epidemiological description of cystic ovarian disease in argentine dairy herds: Risk factors and effects on the reproductive performance of lactating cows. *Reprod. Domest. Anim.*, **49**: 1028-1033. <https://doi.org/10.1111/rda.12432>
- Colakoglu, H.E., Yazlik, M.O., Esen, A., and Tunc, A.S., 2021. Partial uterine prolapse and ovarian cysts in two Djungarian hamsters. *Vet. Med.*, **66**: 40-44. <https://doi.org/10.17221/144/2020-VETMED>
- Coleman, D.A., 2008. Cystic ovarian disease. Available on <http://www.wvu.edu/~agexten/forglvst/Dairy/dir25.pdf>.
- Cook, D.L., Parfet, J.R., Smith, C.A., Moss, G.E., Youngquist, R.S., and Garverick, H.A., 1991. Secretory patterns of LH and FSH during development and hypothalamic and hypophysial characteristics following development of steroid-induced ovarian follicular cysts in dairy cattle. *Reproduction*, **91**: 19-28. <https://doi.org/10.1530/jrf.0.0910019>
- De Rensis, F., López-Gatiús, F., García-Ispuerto, I. and Techakumpu, M., 2010. Clinical use of human chorionic gonadotropin in dairy cows: An update. *Theriogenology*, **73**: 1001-1008. <https://doi.org/10.1016/j.theriogenology.2009.11.027>
- Dhara, S., and Sharma, M., 2019. Cystic ovarian disease in dairy cow: Theriological insight. *Int. J. Reprod. Anim.*, **9**: 27-34. <https://doi.org/10.30954/2277-3371.01.2019.6>
- Díaz, P.U., Stangaferro, M.L., Gareis, N.C., Silvia, W.J., Matiller, V., Salvetti, N.R., and Ortega, H.H., 2015. Characterization of persistent follicles

- induced by prolonged treatment with progesterone in dairy cows: An experimental model for the study of ovarian follicular cysts. *Theriogenology*, **84**: 1149-1160. <https://doi.org/10.1016/j.theriogenology.2015.06.015>
- Douthwaite, R. and Dobson, H., 2000. Comparison of different methods of diagnosis of cystic ovarian disease in cattle and an assessment of its treatment with a progesterone releasing intravaginal device. *Vet. Rec.*, **13**: 355-359. <https://doi.org/10.1136/vr.147.13.355>
- Fleischer, P., Metzner, M., Beyerbach, M., Hoedemaker, M. and Klee, W., 2001. The relationship between milk yield and the incidence of some diseases in dairy cows. *Int. J. Dairy Sci.*, **84**: 2025-2035. [https://doi.org/10.3168/jds.S0022-0302\(01\)74646-2](https://doi.org/10.3168/jds.S0022-0302(01)74646-2)
- Francou, M., Durdos, M., Salvetti, N.R., Baravalle, C., Rey, F. and Ortega, H.H., 2008. Characterization of pituitary cell populations in rats with induced polycystic ovaries. *Cells Tissues Organs*, **188**: 310-319. <https://doi.org/10.1159/000123202>
- Gaebler, E., Eigenmann, U., Bruckmaier, R. and Bleul, U., 2015. Fate of follicular ovarian cysts in early postpartum dairy cows treated with PRID/PGF or PRID/PGF plus eCG. *Tierarztl. Prax. Ausg. G: Grossstie.*, **6**.
- Garverick, H.A., 1997. Ovarian follicular cysts in dairy cows. *Int. J. Dairy Sci.*, **80**: 995-1004. [https://doi.org/10.3168/jds.S0022-0302\(97\)76025-9](https://doi.org/10.3168/jds.S0022-0302(97)76025-9)
- Gobikrushanth, M., Salehi, R., Ambrose, D.J. and Colazo, M.G., 2016. Categorization of endometritis and its association with ovarian follicular growth and ovulation, reproductive performance, dry matter intake, and milk yield in dairy cattle. *Theriogenology*, **86**: 1842-1849. <https://doi.org/10.1016/j.theriogenology.2016.06.003>
- Gümen, A. and Wiltbank, M.C., 2002. An alteration in the hypothalamic action of estradiol due to lack of progesterone exposure can cause follicular cysts in cattle. *Biol. Reprod.*, **66**: 1689-1695. <https://doi.org/10.1095/biolreprod66.6.1689>
- Hanzen, C.H., Pieterse, M., Scenczi, O. and Drost, M., 2000. Relative accuracy of the identification of ovarian structures in the cow by ultrasonography and palpation per rectum. *Vet. J.*, **159**: 161-170. <https://doi.org/10.1053/tvj.1999.0398>
- Hatler, T.B., Hayes, S.H., Laranja da Fonseca, L.F. and Silvia, W.J., 2003. Relationship between endogenous progesterone and follicular dynamics in lactating dairy cows with ovarian follicular cysts. *Biol. Reprod.*, **69**: 218-223. <https://doi.org/10.1095/biolreprod.102.012179>
- Hooijer, G.A., Van Oijen, M.A.A.J., Frankena, K. and Valks, M.M.H., 2001. Fertility parameters of dairy cows with cystic ovarian disease after treatment with gonadotrophin releasing hormone. *Vet. Rec.*, **149**: 383-386. <https://doi.org/10.1136/vr.149.13.383>
- Ismail, I.M., Waheeb, R.S. and Hatab, S.A., 2017. Reproductive performance of Holstein-Friesian dairy cows subjected to different treatments for cystic ovarian follicles. *Alex. J. Vet. Sci.*, **53**: 16-23. <https://doi.org/10.5455/ajvs.256190>
- Isobe, N., 2007. Follicular cysts in dairy cows. *Anim. Sci. J.*, **78**: 1-6. <https://doi.org/10.1111/j.1740-0929.2006.00397.x>
- Jafari, D.A., Mirshokraei, P. and Dehghani, A., 2015. Metabolic profiles of high-yielding dairy cows with ovarian cysts formation. *Iran. J. Vet. Med.*, **9**: 241-248.
- Jeengar, K., Chaudhary, V., Kumar, A., Raiya, S., Gaur, M. and Purohit, G.N., 2018. Ovarian cysts in dairy cows: Old and new concepts for definition, diagnosis and therapy. *Anim. Reprod.*, **11**: 63-73.
- Johnson, W.H. and Coates, A.E., 2004. *An update on cystic ovarian disease*. Proceeding of 15th International Congress on Animal Reproduction, Porto Seguro, Brazil, pp. 60- 65.
- Kesler, D.J. and Garverick, H.A., 1982. Ovarian cysts in dairy cattle: A review. *J. Anim. Sci.*, **55**: 1147-1159. <https://doi.org/10.2527/jas1982.5551147x>
- Khalil, A.Y., 2019. Comparative efficacy of two synchronization of ovulation regimens in the treatment of cystic ovarian disease in dairy cows. *Alex. J. Vet. Sci.*, **62**: 61. <https://doi.org/10.5455/ajvs.47375>
- Kim, K.D., Ki, K.S., Kang, H.G. and Kim, I.H., 2005. Risk factors and the economic impact of ovarian cysts on reproductive performance of dairy cows in Korea. *J. Reprod. Dev.*, pp. 0506080020-0506080020.
- Kovács, L., Rózsa, L., Pálffy, M., Hejel, P., Baumgartner, W. and Szenci, O., 2020. Subacute ruminal acidosis in dairy cows, physiological background, risk factors and diagnostic methods. *Vet. Stanica.*, **51**: 5-17. <https://doi.org/10.46419/vs.51.1.1>
- Lima, F.S., Acosta, D.A., Egan, T.R., Skenandore, C., Sulzberger, S., French, D.D. and Cardoso, F.C., 2019. Steroidogenic, metabolic, and immunological markers in dairy cows diagnosed with cystic ovarian follicles at early and mid-late lactation. *Front. Vet. Sci.*, **6**: 324. <https://doi.org/10.3389/fvets.2019.00324>

- Lüttgenau, J., Kögel, T. and Bollwein, H., 2016. Effects of GnRH or PGF2 α in week 5 postpartum on the incidence of cystic ovarian follicles and persistent corpora lutea and on fertility parameters in dairy cows. *Theriogenology*, **85**: 904-913. <https://doi.org/10.1016/j.theriogenology.2015.10.040>
- Marelli, B.E., Diaz, P.U., Salvetti, N.R., Rey, F. and Ortega, H.H., 2014. mRNA expression pattern of gonadotropin receptors in bovine follicular cysts. *Reprod. Biol.*, **14**: 276-281. <https://doi.org/10.1016/j.repbio.2014.08.002>
- Matiller, V., Stangaferro, M.L., Díaz, P.U., Ortega, H.H., Rey, F., Huber, E. and Salvetti, N.R., 2014. Altered expression of transforming growth factor beta isoforms in bovine cystic ovarian disease. *Reprod. Domest.*, **49**: 813-823. <https://doi.org/10.1111/rda.12373>
- Mimoune, N., Baazizi, R., Azzouz, M.Y., Benaissa, M.H., and Kaidi, R., 2019. Basic and new concepts of ovarian cyst pathogenesis in cattle. *Veterinaria*, **68**: 73-80.
- Mimoune, N., Benaissa, M.H., Bai, R., Saidi, R., Azzouz, M.Y., Belarbi, A., and Kaidi, R., 2020. Histological and immune histochemical evaluation of ovarian cysts in cattle. *Rumin. Sci.*, **9**: 1-6.
- Mimoune, N., Kaidi, R., Azzouz, M.Y., Zenia, S., Benaissa, M.H. and England, G., 2017. Investigation on diagnosis and metabolic profile of ovarian cysts in dairy cows. *Kafkas Univ. Vet. Fak. Derg.*, **23**.
- Nelson, S.T., Martin, A.D. and Østerås, O., 2010. Risk factors associated with cystic ovarian disease in Norwegian dairy cattle. *Acta Vet. Scand.*, **52**: 1-10. <https://doi.org/10.1186/1751-0147-52-60>
- Noakes, D.E., Parkinson, T.J. and England, G.C.W., 2001. *Arthur's veterinary reproduction and obstetrics* (8th ed.). Elsevier
- Opsomer, G., Gröhn, Y.T., Hertl, J., Coryn, M., Deluyker, H. and de Kruif, A., 2000. Risk factors for post partum ovarian dysfunction in high producing dairy cows in Belgium: A field study. *Theriogenology*, **53**: 841-857. [https://doi.org/10.1016/S0093-691X\(00\)00234-X](https://doi.org/10.1016/S0093-691X(00)00234-X)
- Ortega, H., Díaz, P., Salvetti, R., Hein, J., Marelli, G.B., Rodríguez, U. and Rey, F., 2016. Follicular cysts: A single sign and different diseases. A view from comparative medicine. *Curr. Pharm. Dis.*, **22**: 5634-5645. <https://doi.org/10.2174/1381612822666160804100941>
- Ortega, H.H., Marelli, B.E., Rey, F., Amweg, A.N., Díaz, P.U., Stangaferro, M.L. and Salvetti, N.R., 2015. Molecular aspects of bovine cystic ovarian disease pathogenesis. *Reproduction*, **149**: R251–R264. <https://doi.org/10.1530/REP-14-0618>
- Peter, A.T., 2000. Managing postpartum health and cystic ovarian disease. In: *Proceedings of the eighteenth annual western Canadian dairy seminar: Advances in dairy technology*. Alberta, Canada, pp. 85-99.
- Peter, A.T., 2004. An update on cystic ovarian degeneration in cattle. *Reprod. Domest. Anim.*, **39**: 1-7. <https://doi.org/10.1046/j.0936-6768.2003.00466.x>
- Peter, T.A., 1997. Infertility due to abnormalities of the ovaries. *Curr. Ther. Large Anim. Theriogenol.*, pp. 349-354.
- Polat, I.M., Alçıgır, E., Pekcan, M., Vural, S.A., Özenç, E., Canatan, H.E. and Vural, M.R., 2015. Characterization of transforming growth factor beta superfamily, growth factors, transcriptional factors, and lipopolysaccharide in bovine cystic ovarian follicles. *Theriogenology*, **84**: 1043-1052. <https://doi.org/10.1016/j.theriogenology.2015.06.003>
- Probo, M., Comin, A., Mollo, A., Cairolì, F., Stradaìoli, G. and Veronesi, M.C., 2011. Reproductive performance of dairy cows with luteal or follicular ovarian cysts after treatment with buserelin. *Anim. Reprod. Sci.*, **127**: 135-139. <https://doi.org/10.1016/j.anireprosci.2011.07.019>
- Rizzo, A., Minoia, G., Trisolini, C., Mutinati, M., Spedicato, M., Jirillo, F. and Sciorsci, R.L., 2009. Reactive oxygen species (ROS): Involvement in bovine follicular cysts etiopathogenesis. *Immunopharmacol. Immunotoxicol.*, **31**: 631-635. <https://doi.org/10.3109/08923970902932962>
- Robker, R.L., Russell, D.L., Yoshioka, S., Sharma, S.C., Lydon, J.P., O'Malley, B.W. and Richards, J.S., 2000. Ovulation: A multi-gene, multi-step process. *Steroids*, **65**: 559-570. [https://doi.org/10.1016/S0039-128X\(00\)00114-8](https://doi.org/10.1016/S0039-128X(00)00114-8)
- Salvetti, N.R., Stangaferro, M.L., Palomar, M.M., Alfaro, N.S., Rey, F., Gimeno, E.J., and Ortega, H.H., 2010. Cell proliferation and survival mechanisms underlying the abnormal persistence of follicular cysts in bovines with cystic ovarian disease induced by ACTH. *Anim. Reprod. Sci.*, **122**: 98-110. <https://doi.org/10.1016/j.anireprosci.2010.08.003>
- Sayad, A., Koochi, M.K., Vodjgani, M., Abdi, K., Gharagozloo, F., Rezvanfar, M.A. and Abdollahi, M., 2019. An evaluation of the plasma levels of frequently used pesticides in dairy cattle and its possible correlation with the occurrence of follicular cystic ovarian disease: A case-control study. *Nanotechnol. Biol. Med.*, **7**: 55-63.
- Scully, D.M., Campion, D., McCartney, F., Dulohery,

- K., Reese, S. and Kölle, S., 2021. Cystic ovary disease impairs transport speed, smooth muscle contraction, and epithelial ion transport in the bovine oviduct. *Mol. Reprod. Dev.*, **88**: 558-570. <https://doi.org/10.1002/mrd.23521>
- Shimizu, T., Ishizawa, S., Magata, F., Kobayashi, M., Fricke, P.M. and Miyamoto, A., 2018. Involvement of lipopolysaccharide in ovarian cystic follicles in dairy cow: Expressions of LPS receptors and steroidogenesis-related genes in follicular cells of cystic follicles. *Anim. Reprod. Sci.*, **195**: 89-95. <https://doi.org/10.1016/j.anireprosci.2018.05.010>
- Silvia, W.J., Hatler, T.B., Nugent, A.M. and Da Fonseca, L.L., 2002. Ovarian follicular cysts in dairy cows: An abnormality in folliculogenesis. *Domest. Anim. Endocrinol.*, **23**: 167-177. [https://doi.org/10.1016/S0739-7240\(02\)00154-6](https://doi.org/10.1016/S0739-7240(02)00154-6)
- Silvia, W.J., McGinnis, A.S. and Hatler, T.B., 2005. A comparison of adrenal gland function in lactating dairy cows with or without ovarian follicular cysts. *Reprod. Biol.*, **5**: 19-29.
- Simensen, E., Østerås, O., Bøe, K.E., Kielland, C., Ruud, L.E. and Næss, G., 2010. Housing system and herd size interactions in Norwegian dairy herds; associations with performance and disease incidence. *Acta Vet. Scand.*, **52**: 1-9. <https://doi.org/10.1186/1751-0147-52-14>
- Stassi, A.F., Gareis, N.C., Marelli, B.E., Matiller, V., Leiva, C., Rey, F., Ortega, H.H., Salvetti, N.R. and Baravalle, M.E., 2019. Follicular structures of cows with cystic ovarian disease present altered expression of cytokines. *Zygote* (Cambridge, England). **27**: 285-298. <https://doi.org/10.1017/S0967199419000285>
- Szenci, O., Szelenyi, Z., Lenart, L., Bujak, D., Kovacs, L., Kezer, L.F., Han, B. and Horvath, A., 2018. Importance of monitoring the peripartal period to increase reproductive performance in dairy cattle. *Vet. Stat.*, **49**: 297-307.
- Tebble, J.E., O'Donnell, M.J. and Dobson, H., 2001. Ultrasound diagnosis and treatment outcome of cystic ovaries in cattle. *Vet. Rec.*, **148**: 411-413. <https://doi.org/10.1136/vr.148.13.411>
- Teshome, E., Kebede, A., Abdela, N. and Ahmed, W.M., 2016. Ovarian cyst and its economic impact in dairy farms: A review. *Glob. Vet.*, **16**: 461-471.
- Todoroki, J., Yamakuchi, H., Mizoshita, K., Kubota, N., Tabara, N., Noguchi, J. and Kaneko, H., 2001. Restoring ovulation in beef donor cows with ovarian cysts by progesterone-releasing intravaginal silastic devices. *Theriogenology*, **55**: 1919-1932. [https://doi.org/10.1016/S0093-691X\(01\)00533-7](https://doi.org/10.1016/S0093-691X(01)00533-7)
- Vanholder, T., Leroy, J.L.M.R., Dewulf, J., Duchateau, L., Coryn, M., de Kruif, A. and Opsomer, G., 2005. Hormonal and metabolic profiles of high yielding dairy cows prior to ovarian cyst formation or first ovulation post-partum. *Reprod. Domest. Anim.*, **40**: 460-467. <https://doi.org/10.1111/j.1439-0531.2005.00601.x>
- Vanholder, T., Opsomer, G.A. and Kruif, A., 2006. Aetiology and pathogenesis of cystic ovarian follicles in dairy cattle: A review. *Reprod. Nutr. Dev.*, **46**: 105-119. <https://doi.org/10.1051/rnd:2006003>
- Woolums, A.R., 1994. Cystic ovarian condition in cattle. Part II. Pathogenesis and treatment. *Compend. Contin. Educ. Pract. Vet.*, **16**: 1247-1252.
- Xu, X., Bai, J., Qin, Y., Feng, T., Xiao, L., Song, Y. and Liu, Y., 2021. Abnormal expression of the steroid hormone synthesis pathway associates with cattle ovarian cysts. *Res. Squire*, **1**: 17. <https://doi.org/10.21203/rs.3.rs-201894/v1>
- Yimer, N., Haron, A.W. and Yusoff, R., 2018. Determination of ovarian cysts in cattle with poor reproductive performance using ultrasound and plasma progesterone profile. *Vet. Med. Open J.*, **3**: 1-9. <https://doi.org/10.17140/VMOJ-3-126>
- Yoshioka, K., Iwamura, S. and Kamomae, H., 1996. Ultrasonic observations on the turnover of ovarian follicular cysts and associated changes of plasma LH, FSH, progesterone and oestradiol-17 β in cows. *Res. Vet. Sci.*, **61**: 240-244. [https://doi.org/10.1016/S0034-5288\(96\)90071-5](https://doi.org/10.1016/S0034-5288(96)90071-5)
- Zulu, V.C., Nakao, T. and Sawamukai, Y., 2002. Insulin-like growth factor-I as a possible hormonal mediator of nutritional regulation of reproduction in cattle. *J. Vet. med. Sci.*, **64**: 657-665. <https://doi.org/10.1292/jvms.64.657>
- Zulu, V.C., Nakao, T., Yamada, K., Moriyoshi, M., Nakada, K. and Sawamukai, Y., 2003. Clinical response of ovarian cysts in dairy cows after PRID treatment. *J. Vet. med. Sci.*, **65**: 57-62. <https://doi.org/10.1292/jvms.65.57>