



# Effects of Ibuprofen and Clopidol Alone and in Combination on Experimentally Induced Coccidiosis in Broiler Chickens

Mian Abdul Hafeez<sup>1\*</sup>, Adeel Sattar<sup>2</sup>, Faiza Aslam<sup>3</sup>, Muhammad Imran<sup>3</sup>, Kamran Ashraf<sup>1</sup>, Rashid Zia<sup>2</sup> and M. Muntazir Mehdi<sup>1</sup>

<sup>1</sup>Department of Parasitology, University of Veterinary and Animal Sciences, Lahore

<sup>2</sup>Department of Pharmacology and Toxicology, University of Veterinary and Animal Sciences, Lahore

<sup>3</sup>Livestock and Dairy Development Department, Punjab, Pakistan

## ABSTRACT

The objective of current exploration was to validate therapeutic efficacy of Ibuprofen, a nonsteroidal anti-inflammatory drug and coccidiostat (Clopidol) alone and in combination against coccidiosis in broiler birds. Chicks were randomly allocated to five treatment groups of 25 broilers in each pen on 5<sup>th</sup> day of age. Birds in groups A, B, C and D were challenged by 60,000-70,000 sporulated oocysts of mixed species local isolates at 21<sup>st</sup> day of age. Groups A and B were medicated with Ibuprofen (100mg/kg body weight) orally and Ibuprofen (100mg/kg B.W) orally plus Clopidol (0.5g/kg) of feed respectively, post infection for five days. The group C was medicated with Clopidol (0.5g/kg) of feed. The group D served as infected unmedicated (negative) control and birds in group E were kept as noninfected and nonmedicated (positive) control. Therapeutic effects were measured in terms of mortality, growth performance, oocysts count, coccidial lesion scoring and weight of lymphoid organs. Coccidial lesion scores and oocysts count was lower in group A, B and C than in group D. No mortality was observed in group E, while highest in group D as compared to A, B and C. Highest growth performance, a significant reduction in oocysts count and reduction in lymphoid organ body weight ratio was observed in groups B as compared to groups A and C. This study suggested protective, therapeutic as well as a synergistic effect of Ibuprofen with clopidol in chicken coccidiosis.

## Article Information

Received 25 June 2018

Revised 22 May 2019

Accepted 20 November 2020

Available online 12 August 2021

(early access)

Published 28 February 2022

## Authors' Contribution

MAH and AS conceived and designed the experiments. AS, MAH, FA and MA performed the experiments. KA, RZ and MMM analyzed the data. MAH, AS and KA contributed reagents/materials/analysis tools. MAH, AS and RZ wrote the paper.

## Key words

Coccidiosis, Ibuprofen, Clopidol, Broiler chickens

## INTRODUCTION

Poultry farming is one of the rapidly growing and income generating industries, which plays a pivotal role in the economy of Pakistan. The world of poultry industry has to contend with the threat of many diseases of bacterial, viral and parasitic origin. Among parasitic problems, coccidiosis a protozoan disease causes substantial economic losses in the form of morbidity, mortality, and poor growth performance with significant economic outcome (Allen and Fetterer, 2002; Bera *et al.*, 2010; Pop *et al.*, 2019). In addition to mortality and reduced growth, coccidiosis also affects meat yield and quality and increases susceptibility to ancillary infections (Noack *et al.*, 2019). Avian coccidiosis is mainly caused by seven species of genus *Eimeria*. These species are *E. acervulina*, *E. brunetti*, *E. tenella*, *E. maxima*, *E. mitis*, *E. necatrix* and *E. mivati* (Costa *et al.*, 2001; Idris *et al.*, 2017). All these species except *E. tenella* are associated with intestinal coccidiosis leading to decreased nutrient absorption,

haemorrhages and death (Soulsby, 1982; Macdonald *et al.*, 2017). Currently, control of coccidiosis in poultry is dependent upon regular administration of coccidiostats through feed or drinking water (Bhatti, 1989). The emergence of complete and partial resistance against most anticoccidial drugs in poultry is a major concern. Extensive use of anticoccidials has led to the development of anticoccidial drug resistance (Sundar *et al.*, 2017; Peek and Landman, 2003; Alnassan *et al.*, 2015). To prevent the outbreak of coccidiosis, coccidiostats were added to the chicken feed. The long-term use of the drugs has made the *Eimeria* spp. develop resistance to them in many geographic regions (Wang *et al.*, 2020; Gangadoo *et al.*, 2016) Moreover, some of the side effects of these coccidiostats including disturbed growth rates, depressed feed conversion ratio (FCR) and immunomodulatory changes create many doubts in the mind of farming community about their regular use (Krautwald-Junghanns *et al.*, 2009; Yang *et al.*, 2015). Other preventive measures like vaccination are not up to the mark because of the expensive cost of vaccines (precocious strains are used in slow-growing chickens with higher economic value than fast growing chickens) and unknown adverse effects on chick growth, as well as fears of insufficiently developed

\* Corresponding author: [Abdul.hafeez@uvas.edu.pk](mailto:Abdul.hafeez@uvas.edu.pk)  
0030-9923/2022/0003-1369 \$ 9.00/0  
Copyright 2022 Zoological Society of Pakistan

immunity and nutritional means (Williams, 2002; Cervantes, 2015).

Clopidol, a coccidiostat stops the development of sporozoites or trophozoites by acting against the electron transport system within the parasitic mitochondria. It has a broad spectrum efficacy, but development of resistance is its major concern (Fry and Williams, 1984; Asadi *et al.*, 2015). Due to limits of the means used at present to fight against this important disease, alternatives must be proposed such as nonsteroidal anti-inflammatory drugs (NSAIDs) like Ibuprofen (Brufen™) for possible treatment option against coccidiosis in broilers. NSAIDs inhibit the biosynthesis of prostaglandins (PGs) having pro-inflammatory and immunosuppressive properties which are produced during coccidial infection (Hornok *et al.*, 1999). Their potential role in prostaglandin inhibition presents them (Ibuprofen) as a candidate molecule to reduce severity of coccidiosis (by decreasing the coccidial lesion score and oocysts shedding) in broiler chicken (Vermeulen *et al.*, 2004; Hafeez *et al.*, 2020).

The immune responses of the host beside the coccidial infections are complex. The specific function of T lymphocytes in cellular immunity is well documented (Lillehoj, 1998; Lillehoj and Lillehoj, 2000; Yun *et al.*, 2000; Vermeulen *et al.*, 2004; Clark *et al.*, 2017). They are implicated in the production of cytokines (interferon (INF)- $\gamma$ , tumor necrosis factor, interleukin (IL)-2, IL-5 and transforming growth factors (Lillehoj and Lillehoj, 2000; Yun *et al.*, 2000). The production of nitric oxide (NO) from arginine by interfer and tumor necrosis factor (Ovington *et al.*, 1995; Lillehoj and Lillehoj, 2000; Vermeulen *et al.*, 2004) plays an imperative protective role against different apicomplexa (*Eimeria* spp.) parasites (Adams *et al.*, 1990; Mellouk *et al.*, 1991; Yazdanabadi *et al.*, 2020). The production of PGs with the pro-inflammatory and immunosuppressive properties is directly proportional to the production of NO, which activates inducible cyclooxygenase (iCOX). NSAIDs-inhibit the cyclooxygenase (COX) which in turn breaks down the biosynthesis of these PGs, hence might prove effective in coccidial infections (Rainsford, 2009).

The contemporary investigation was planned to explore the therapeutic efficacy of a NSAID *viz.*, Ibuprofen (Brufen™) and clopidol alone as well as in combination. The synergistic effects of these drugs on mortality, oocysts shedding, lesion scoring and weight of lymphoid organs in experimentally induced coccidiosis in broilers were probed.

## MATERIALS AND METHODS

### *Collection, purification and oocysts sporulation*

Chicken guts anticipated to be infected with coccidia

were collected from different poultry shops of Faisalabad city. The contents thus obtained from the guts were examined by direct microscopy (Soulsby, 1982; Gadelhaq and Habelaty, 2019). The positive samples under microscopic examination were subjected to concentration of oocysts using salt floatation technique (Ryley *et al.*, 1976). Oocysts collected from saturated salt solution were poured into an excessive volume of distilled water (at least five times) to bring the specific gravity below 1.03. The refining of oocysts was performed by centrifugation at 1500 rpm for 5 min and transferred into 2.5% potassium dichromate solution in Petri dishes for sporulation at 30-32°C and 80% humidity for 48-72 h (Ryley *et al.*, 1976; Hafeez *et al.*, 2006; Abbas *et al.*, 2019). Sporulated oocysts were stored at 4°C until use. Number of sporocysts and sporozoites present in the sporulated oocysts were counted with the help of modified McMaster egg counting technique (Razzaq *et al.*, 2012; Muller *et al.*, 2019) to estimate proportion of different *Eimeria* species present in mixture and infective dose was estimated as in previous studies by (Hafeez *et al.*, 2006; Craig *et al.*, 2020).

### *Experimental design*

Day-old broiler chicks (125, number-Hubbard®) were purchased from local market of Faisalabad (commercial hatchery Al-Noor Chicks Jaranwala Road Faisalabad, Pakistan). These birds were kept in pens under standard managerial conditions (for forty days). Chicks were randomly divided into five equal groups A, B, C, D and E (25 chicks in each) on 5<sup>th</sup> day of age. The birds in first four groups (A, B, C and D) were challenged with 60,000-70,000 (Average 65,000  $\times$  6.5  $\times$  10<sup>4</sup>) sporulated oocysts of mixed virulent species of the genus *Eimeria*, *E. tenella*, *E. maxima*, *E. acervulina* and *E. necatrix* at 21<sup>st</sup> day of age by crop tubing (1mL/bird). The species were identified on the basis of their shape, size, predilection site (Soulsby 1982; Debbou *et al.*, 2018) and treated as follows:

Group A (infected and medicated) treated with Ibuprofen (Brufen suspension™ Abbot Lab. Pakistan Ltd.) @100mg per kg body weight orally, post infection for 5 days.

Group B (infected and medicated) treated with Ibuprofen @100mg per kg body weight orally, post infection for 5 days and Clopidol coccidiostat (clopidol™ Noa Hemis Pharma. Pakistan) @ 0.5g per kg of feed, started two days before infection for 7 days.

Group C (infected and medicated) treated with coccidiostat @ 0.5g per kg of feed, started two days before infection for 7 days.

Group D negative control (infected and non-medicated).

Group E positive control (non infected and non-medicated).

### Evaluation parameters

Therapeutic efficacy of treatment regimens were evaluated on the basis of oocysts shedding (from day of infection till 13<sup>th</sup> day) which was determined daily by collecting the whole faeces (Hafeez *et al.*, 2006; Chand *et al.*, 2016), lesion scoring was performed for seven days post challenge (5 birds each on 5<sup>th</sup> and 7<sup>th</sup> day by euthanizing and on remaining five days dead birds (due to infection) by post mortem examination of dead and by slaughtering of survived chicks (Tanweer *et al.*, 2014), mortality, growth performance (from day of infection) and effect on weight of lymphoid organs by post-mortem of dead birds and by slaughtering live birds at the end of experiment.

### Histopathological studies

The intestinal tissues were fixed in 10% neutral buffered formalin, dehydrated in ethyl alcohol, cleared in xylene and embedded in paraffin. Histological sections (4-5 µm) were stained with hematoxylin and eosin for pathological studies (Macdonald *et al.*, 2017).

### Statistical analysis

Analysis of variance (ANOVA) using Duncan's multiple range test for variables was calculated for body weight gain, lesion score and oocyst index. When momentous differences were observed, means were separated by Fisher's protected least significant difference. Differences between group mean were considered

significant at  $P < 0.05$ . General linear models procedure SAS® (SAS Institute, 1994) Software, USA was used to analyze the data.

## RESULTS

Table I shows lesion score in experimental group. No mortality was observed in group E (positive control). Highest mortality (22/25) was observed in group D (negative control). Group A (9/25) showed higher mortality than group B (4/25). Group C showed mortality (12/25) higher than group A and group B. The total number of survived birds after the oocyst challenge was 16/25, 21/25, 13/25 and 3/25 in group A, B, C and D respectively. In group E, negligible lesions were observed after slaughtering the birds. Statistical analysis showed that there was substantial difference among mean lesion scores of infected groups.

Table II shows changes in body weight post challenge. In group E maximum gain in weights was observed, Group D gained lowest weight as it was infected control, while group A and C show comparatively less increase in weight compared to group B. The difference between the weight gains of test groups as compared to infected control and un-infected control was significant ( $P < 0.05$ ). Table III shows number of OPG in experimental group post challenge. Number of excreted oocysts were lower in B than in groups A and C. The maximum number of oocysts was observed in group D.

**Table I. Effects of ibuprofen (brufen™) and clopidol alone and in combination on Lesion score in broiler growth performance in experimentally induced coccidiosis in broiler birds. Lesion score in experimental groups post challenge (n = 25 at 21<sup>st</sup> 399 day of age).**

Lesion score on days (n=5 each)	Positive control (E)	Negative control (D)	Ibuprofen treatment (A)	Clopidol treatment (C)	Ibuprofen + Clopidol treatment (B)
1. Et, Ea, Em	0	0	0	0	0
2. Et, Ea, Em	0	0	0	0	0
3. Et, Ea, Em	0	0	0	0	0
4. Et	0.2±0.1 <sup>d</sup>	1.2±0.5 <sup>a</sup>	0.9±0.2 <sup>c</sup>	0.9±0.2 <sup>c</sup>	0.4±0.1 <sup>b</sup>
Ea	0	1.0±0.4 <sup>a</sup>	0.5±0.1 <sup>c</sup>	0.4±0.1 <sup>c</sup>	0.2±0.1 <sup>b</sup>
Em	0.1±0 <sup>d</sup>	1.0±0.4 <sup>a</sup>	0.5±0.1 <sup>c</sup>	0.4±0.1 <sup>c</sup>	0.2±0.1 <sup>b</sup>
5. Et	0.1±0.1 <sup>d</sup>	2.8±0.8 <sup>a</sup>	1.9±0.6 <sup>c</sup>	1.6±0.5 <sup>c</sup>	1.2±0.5 <sup>b</sup>
Ea	0.2±0.1 <sup>d</sup>	2.5±0.7 <sup>a</sup>	1.5±0.5 <sup>c</sup>	1.4±0.4 <sup>c</sup>	1±0.5 <sup>b</sup>
Em	0	2.5±0.5 <sup>a</sup>	1.4±0.5 <sup>c</sup>	1.2±0.5 <sup>c</sup>	1.0±0.5 <sup>b</sup>
6. Et	0	2.9±0.8 <sup>a</sup>	1.5±0.5 <sup>c</sup>	1.4±0.5 <sup>c</sup>	1±0.5 <sup>b</sup>
Ea	0	2.5±0.7 <sup>a</sup>	1.2±0.4 <sup>c</sup>	1.0±0.2 <sup>c</sup>	0.9±0.2 <sup>b</sup>
Em	0	2.5±0.7 <sup>a</sup>	1.2±0.4 <sup>c</sup>	1.2±0.4 <sup>c</sup>	0.9±0.2 <sup>b</sup>
7. Et	0	3.5±1.0 <sup>a</sup>	2±0.6 <sup>c</sup>	1.8±0.6 <sup>c</sup>	1.2±0.5 <sup>b</sup>
Ea	0	3±0.9 <sup>a</sup>	1.8±0.5 <sup>c</sup>	1.4±0.4 <sup>c</sup>	1±0.5 <sup>b</sup>
Em	0	3±0.9 <sup>a</sup>	1.8±0.5 <sup>c</sup>	1.6±0.4 <sup>c</sup>	1±0.5 <sup>b</sup>

Et, *Eimeria tenella*; Ea, *Eimeria acervulina*; Em, *Eimeria maxima*. Mild, 0 – 0.99; Moderate, 1.0 -1.99; Severe, 2 -2.99; V. Severe, 3 and above. Values are mean value ± SD, within column after infection at 21st day of age, values having different superscripts are significantly ( $p \leq 0.05$ ) different. Columns without superscripts are not significantly different. Values having different superscripts are significantly different ( $p \leq 0.05$ ), while values having same superscripts are having non-significant differences.

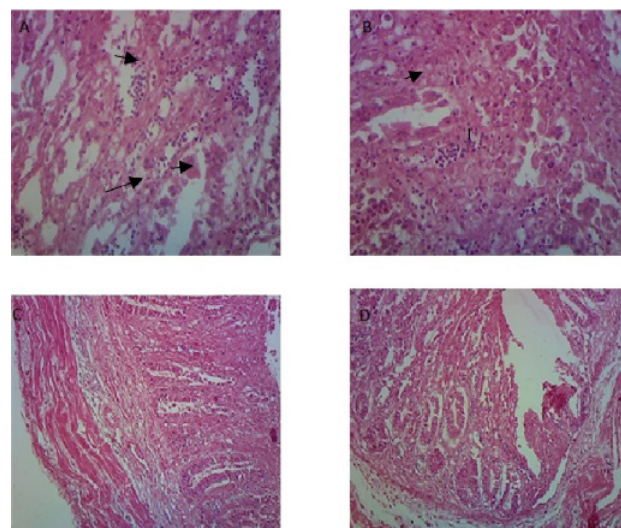
**Table II. Effects of ibuprofen (brufen™) and clopidol alone and in combination on body weight gain in broiler growth performance in experimentally induced coccidiosis in broiler birds post challenge.**

Groups	3 <sup>rd</sup> week	4 <sup>th</sup> week	5 <sup>th</sup> week
A	375.75± 12.5 <sup>b</sup>	450.25±22.50 <sup>b</sup>	525.45±24.45 <sup>b</sup>
B	395.80±13.6 <sup>c</sup>	495.65±25.25 <sup>c</sup>	590.40±26.65 <sup>c</sup>
C	380.70± 12.2 <sup>b</sup>	445.20±20.24 <sup>b</sup>	510.35±24.55 <sup>b</sup>
D	280.20±8.40 <sup>a</sup>	320.40±9.25 <sup>a</sup>	370.50±9.50 <sup>a</sup>
E	425.50±22.5 <sup>d</sup>	565.50±25.50 <sup>d</sup>	675.55±28.65 <sup>d</sup>

Values are mean value ± SD, values having different superscripts are significantly different ( $p \leq 0.05$ ). Columns without superscripts or with same are not significantly different.

The birds of group E (positive control) had the lowest splenic, bursal, thymus and caecal tonsil body weight ratio while highest were observed in group D (negative control) (Table IV). Statistical analysis showed that there was a significant difference ( $P < 0.05$ ) among organ body weight ratio of groups A, B, C as compared with D and E. Group D was having more organ body weight ratio as compared with medicated groups A, B and C. Similarly, group B showed lower organ body weight ratio as compared to group A and C. Group E showed lowest organ body weight ratio among all the groups. Histopathology revealed severe congestion, cytoplasmic vacuolation in some areas, mild to moderate necrosis and hyperplasia of reticular cells in infected group

(D) as compared to treated and control groups (A, B, C and E). Severe congestion, disorganization of white pulp, degeneration, vacuolation and depletion of lymphocytes was noticed in challenged group (Fig. 1).



**Fig. 1.** Selected micro-photomicrographs of intestine of broiler infected with virulent *Eimeria* species. Severe congestion, cytoplasmic vacuolation in some areas, mild to moderate necrosis and hyperplasia of reticular cells in infected group (A) as compared to treated and control groups (B, C, D).

**Table III. Effects of ibuprofen (brufen™) and clopidol alone and in combination on oocyst per gram (OPG) in experimentally induced coccidiosis in broiler birds post challenge (n = 25 at 21<sup>st</sup> 414 day of age).**

Groups	Positive control (E)	Negative control (D)	Ibuprofen treatment (A)	Clopidol treatment (C)	Ibuprofen + Clopidol treatment (B)
Age (Days)					
21-24	-----	-----	-----	-----	-----
25	-----	156.80±7.90 <sup>a</sup>	94.60±4.50 <sup>b</sup>	108.40±5.50 <sup>b</sup>	46.00±2.88 <sup>c</sup>
26	-----	289.00±18.6 <sup>a</sup>	184.0±8.87 <sup>b</sup>	148.0±6.40 <sup>b</sup>	98.00±4.95 <sup>c</sup>
27	1.40±0.8 <sup>d</sup>	240.60±10.50 <sup>b</sup>	298.00±18.8 <sup>b</sup>	240.60±10.50 <sup>b</sup>	548.00±28.9 <sup>a</sup>
28	1.80±0.8 <sup>d</sup>	982.00±88.9 <sup>a</sup>	428.00±34.8 <sup>b</sup>	530.10±38.8 <sup>b</sup>	306.00±23.8 <sup>c</sup>
29	2.98±1.0 <sup>d</sup>	1480.650±98.9 <sup>a</sup>	726.00±70.48 <sup>b</sup>	840.00±74.58 <sup>b</sup>	423.00±32.8 <sup>c</sup>
30	2.00±0.9 <sup>d</sup>	1966.00±125.1 <sup>a</sup>	984.00±89.7 <sup>b</sup>	900.00±92.6 <sup>b</sup>	584.00±46.94 <sup>c</sup>
31	1.00±0.9 <sup>d</sup>	1287.00±95.09 <sup>a</sup>	480.60±38.7 <sup>b</sup>	580.00±44.8 <sup>b</sup>	204.30±12.94 <sup>c</sup>
32	-----	587.60±41.9 <sup>a</sup>	224.06±12.7 <sup>b</sup>	240.00±14.8 <sup>b</sup>	78.30±4.4 <sup>c</sup>
33	-----	287.00±16.4 <sup>a</sup>	108.63±4.34 <sup>b</sup>	120.80±6.8 <sup>b</sup>	35.80±2.24 <sup>c</sup>

Values are mean values ± SD. Within column, values having different superscripts are significantly different ( $p \leq 0.05$ ). Values having different superscripts are significantly ( $p \leq 0.05$ ) different while values having same superscripts are having non-significant difference.



**Table IV. Effects of ibuprofen (brufen™) and clopidol alone and in combination on body weight gain in lymphoid organ ratios in experimentally induced coccidiosis in broiler birds.**

Groups	Spleen	Ceecal tonsil	Bursa fabricius	Thymus
A	0.160±0.01 <sup>b</sup>	0.868±0.01 <sup>b</sup>	0.228±0.02 <sup>b</sup>	0.232±0.04 <sup>b</sup>
B	0.142±0.02 <sup>c</sup>	0.084±0.01 <sup>c</sup>	0.208±0.02 <sup>c</sup>	0.206±0.04 <sup>c</sup>
C	0.164±0.01 <sup>b</sup>	0.882±0.01 <sup>b</sup>	0.224±0.04 <sup>b</sup>	0.228±0.04 <sup>b</sup>
D	0.188±0.04 <sup>a</sup>	0.168±0.02 <sup>a</sup>	0.284±0.06 <sup>a</sup>	0.288±0.06 <sup>a</sup>
E	0.120±0.01 <sup>d</sup>	0.044±0.01 <sup>d</sup>	0.124±0.02 <sup>d</sup>	0.144±0.02 <sup>d</sup>

Values are mean value ± SD, values having different superscripts are significantly different ( $p \leq 0.05$ ). Columns without or with same superscripts are not significantly different.

## DISCUSSION

NSAIDs were suggested to be advantageous remedy for parasitic infections of gastrointestinal system in broilers (Allen, 2000; Cristofol et al., 2000; Vermeulen and Remon, 2001; Palocz et al., 2016). The approach of attainment of this drug on coccidiosis was hypothesized to be a PG dependent mechanism, since an increased PG biosynthesis might be in coccidial infections, mediated by NO induced increased activity of COX2 (Vane et al., 1994; Vermeulen et al., 2004; Kiran et al., 2018). In inflammation and cancer COX-2 is a leading performer. It is one of two COXs that translate arachidonic acid to a common intermediate in the production of PG and thromboxane. COX-2 is inhibited by nonselective COX inhibitors such as aspirin, ibuprofen and sulindac as well as by the COX-2-selective inhibitors celecoxib and rofecoxib.

Inflammation is an imperative promoter to cancer development, and COX inhibitors, whether selective for COX-2 or not, exhibit chemopreventive activity in animal models and patients. Celecoxib, rofecoxib, and sulindac exhibited remarkable reductions in polyp recurrence but also caused cardiovascular side effects in colorectal clinical prevention trials (Baron et al., 2006; Bertagnolli et al., 2006; Rainsford, 2009; Grabosch et al., 2018).

NSAIDs have been reported effective against other parasitic infection of mammals as they can renew the IL-2 levels during protozoan infections. Furthermore, PGs are commonly connected with parasite-induced immunosuppression via inhibition of IL-2 secretion (Hornok et al., 1999). The present research was undertaken to evaluate the upshot of NSAIDs and coccidiostat alone and in combination during experimentally induced coccidiosis in chicken in local environment. The maximum mortality was found in infected group (D=22/25) as reported earlier

by (Migaki and Babcock 1983; Odden et al., 2018) and minimum in treated group (B=4/25).

The gain in body weight was minimum in infected group D and highest in noninfected group which is similar to findings of Migaki and Babcock (1983), who observed reduction in body weight gain in infected birds than in uninfected birds. Among all the treated groups maximum lesion scores were observed in infected groups. These findings are similar to those of Vermeulen et al. (2004) and Amerah et al. (2015) who found that lesion scores were reduced in medicated groups as compared to the infected non-medicated group.

A substantial difference in ratio of lymphoid organ to body weight was observed in infected groups as compared with no infected groups. The increase in this ratio of lymphoid organs to body weight in the infected birds was due to the disease (Venkataratnam et al., 1985; Khaliq et al., 2017) as it has been reported that during coccidiosis there is a hypertrophy and cellular infiltration of the lymphoid organs (Latshaw, 1991; Al-ani, 2016). The peak oocysts count was observed on 10<sup>th</sup> day post infection. In group D the oocysts shedding was maximum and persisted till the end of experiment. In group E there was no /negligible oocysts shedding. The reduction in oocysts shedding and intestinal lesions after medication with IBU @ 100mg/kg in combination with and Clopidol 0.5gm/kg body weight was most probably due to the inhibition of iCOX in group B than A and C, as many anticoccidial have proved to reduce the rate of oocysts production and infectivity of sporulated oocysts (Joyner and Norton, 1977; Arakawa et al., 1991). Oocysts shedding and intestinal lesions reduced in medicated birds than in nonmedicated birds but not the sporulation (Vermeulen et al., 2004).

In this study, increased interfollicular connective tissue, lymphoid cells depletion were recorded. Moreover, pyknosis, fragmentation of nuclei and hyperplasia of columnar epithelium was also observed, while in challenged group (D), increased fibrosis and interfollicular connective tissue proliferation was observed. Moreover, severe congestion, cytoplasmic vacuolation in some areas, mild to moderate necrosis and hyperplasia of reticular cells was observed. These changes might be due to stress caused by the exposure of infection. These results are in accordance with the other finding in different avian species (Helmboldt and Bryant, 1971; Long and Barnum, 1974; Macdonald et al., 2017). Clopidol, a coccidiostat stops the development of sporozoites or trophozoites by acting against the electron transport system within the parasitic mitochondria (Fry and Williams, 1984).

Ibuprofen (Brufen) nonsteroidal anti-inflammatory drugs (NSAIDs) inhibit the biosynthesis of PG having pro-inflammatory properties produced during coccidial

infection, and is therefore proposed as a candidate molecule to reduce severity of coccidiosis in broiler chicken (Vermeulen *et al.*, 2004; Hafeez *et al.* 2020). Both of the drugs having different mode of actions they can be used in combination to have an additive effect. The ibuprofen (Brufen) subsides the inflammation produced by the parasites so it can be presumed that both drugs in combination act effect synergistically and might be used as a novel combination against coccidiosis in local environment coccidiosis.

## CONCLUSION

In conclusion, this study describes the protective effect of ibuprofen in chicken coccidiosis. Furthermore, ibuprofen can be successfully used in combination with clopidol to control the coccidiosis. The combination being used for the first time will also be helpful to avoid the resistance.

## ACKNOWLEDGEMENTS

We thank Mr. Waqas Ahmed for assisting with histopathology. Funding for this study was generated through contribution of all authors.

### *Compliance with ethics standards*

All experimental protocols regarding the handling of birds were in agreement with the requirements of the Institutional Animal Care and Use Committee at University of Agriculture Faisalabad.

### *Statement of conflict of interest*

The authors have affirmed no conflict of interest.

## REFERENCES

- Abbas, R.Z., Abbas, A., Raza, M.A., Khan, M.K., Saleemi, M.K. and Saeed, Z., 2019. *In vitro* anticoccidial activity of Trachyspermum ammi (Ajwain) extract on oocysts of Eimeria species of Chicken. *Adv. Life Sci.*, **7**: 44-47.
- Adams, L.B., Hibbs, J., Taintor, R.R. and Krahenbuhl, J.L., 1990. Microbiostatic effect of murine-activated macrophages for *Toxoplasma gondii*. Role for synthesis of inorganic nitrogen oxides from L-arginine. *J. Immunol.*, **144**: 2725-2729.
- Al-ani, D.A.A.M., 2016. Histopathological patterns in experimentally avian coccidiosis after treatment with *Urtica dioica* L.(Urticaceae). *Al-Mustansiriyah J. Sci.*, **27**: 18-26.
- Allen, P.C. and Fetterer, R., 2002. Recent advances in biology and immunobiology of *Eimeria* species and in diagnosis and control of infection with these coccidian parasites of poultry. *Clin. Microbiol. Rev.*, **15**: 58-65. <https://doi.org/10.1128/CMR.15.1.58-65.2002>
- Allen, P.C., 2000. Effects of treatments with cyclooxygenase inhibitors on chickens infected with *Eimeria acervulina*. *Poult. Sci.*, **79**: 1251-1258. <https://doi.org/10.1093/ps/79.9.1251>
- Alnassan, A.A., Thabet, A., Dauschies, A. and Bangoura, B., 2015. *In vitro* efficacy of allicin on chicken *Eimeria tenella* sporozoites. *Parasitol. Res.*, **114**: 3913-3915. <https://doi.org/10.1007/s00436-015-4637-2>
- Amerah, A.M. and Ravindran, V., 2015. Effect of coccidia challenge and natural betaine supplementation on performance, nutrient utilization, and intestinal lesion scores of broiler chickens fed suboptimal level of dietary methionine. *Poult. Sci.*, **94**: 673-680. <https://doi.org/10.3382/ps/pev022>
- Arakawa, A., Tanaka, Y., Baba, E. and Fukata, T., 1991. Effects of clopidol on sporulation and 304 infectivity of *Eimeria tenella* oocysts. *Vet. Parasitol.*, **38**: 55-60. [https://doi.org/10.1016/0304-4017\(91\)90008-J](https://doi.org/10.1016/0304-4017(91)90008-J)
- Asadi Iraee, H., Asadi, I.M., Youssefi, M.R. and Abouhosseini, T.M., 2015. Growth performance parameters in chicken experimental coccidiosis treated with Diclazuril and Clopidol: The need for assessing new anticoccidial resources. *Iran. J. vet. Med.*, **9**: 189-194.
- Bahadoran, S., Hassanpour, H., Kheirabadi, K.P. and Shekarchian, S., 2014. Effect of clopidol and amprolium/ethopabate on performance and intestinal morphology of chickens with experimental coccidiosis. *Kafkas Üniv. Vet. Fak. Derg.*, **20**: 571-576.
- Baron, J.A., Sandler, R.S., Bresalier, R.S., Quan, H., Riddell, R., Lanas, A., Bolognese, J.A., Oxenius, B., Horgan, K. and Loftus, S., 2006. A randomized trial of rofecoxib for the chemoprevention of colorectal adenomas. *Gastroenterology*, **131**: 1674-1682. <https://doi.org/10.1053/j.gastro.2006.08.079>
- Bera, A.K., Bhattacharya, D., Pan, D., Dhara, A., Kumar, S. and Das, S., 2010. Evaluation of economic losses due to coccidiosis in poultry industry in India. *Agric. Econ. Res. Rev.*, **314**: 91-96.
- Bertagnolli, M.M., Eagle, C.J., Zauber, A.G., Redston, M., Solomon, S.D., Kim, K., Tang, J., Rosenstein, R.B., Wittes, J. and Corle, D., 2006. Celecoxib for the prevention of sporadic colorectal adenomas. *N. Engl. J. Med.*, **355**: 873-884. <https://doi.org/10.1056/NEJMoa061355>

- Bhatti, B., 1989. Incidence of poultry diseases and their importance in poultry production in Pakistan. *Pak. Vet. J.*, **9**: 194-197.
- Cervantes, H.M., 2015. Antibiotic-free poultry production: is it sustainable? *J. appl. Poult. Res.*, **24**: 91-97. <https://doi.org/10.3382/japr/pfv006>
- Chand, N., Faheem, H., Khan, R.U., Qureshi, M.S., Alhidary, I.A. and Abudabos, A.M., 2016. Anticoccidial effect of mananoligosaccharide against experimentally induced coccidiosis in broiler. *Environ. Sci. Pollut. Res.*, **23**: 14414-14421. <https://doi.org/10.1007/s11356-016-6600-x>
- Clark, E.L., Tomley, F.M. and Blake, D.P., 2017. Are *Eimeria* genetically diverse, and does it matter? *Trends Parasitol.*, **33**: 231-241. <https://doi.org/10.1016/j.pt.2016.08.007>
- Costa, C., Gomes, R., Melo, M. and Ribeiro, M., 2001. *Eimeria* parasites of domestic fowl: genetic relationships of different isolates estimated from random amplified polymorphic DNA. *Parasitol. Res.*, **87**: 459-466. <https://doi.org/10.1007/s004360000369>
- Craig, A.D., Khattak, F., Hastie, P., Bedford, M.R. and Olukosi, O.A., 2020. The similarity of the effect of carbohydrase or prebiotic supplementation in broilers aged 21 days, fed mixed cereal diets and challenged with coccidiosis infection. *PLoS One*, **15**: e0229281. <https://doi.org/10.1371/journal.pone.0229281>
- Cristofol, C., Valladares, J., Marti, G. and Arboix, M., 2000. Pharmacokinetics of indomethacin in poultry. *Avian Dis.*, **44**: 210-214. <https://doi.org/10.2307/1592528>
- Debbou-Ioukneane, N., Benbarek, H. and Ayad, A., 2018. Prevalence and aetiology of coccidiosis in broiler chickens in Bejaia province, Algeria. *Onderstepoort J. Vet. Res.*, **85**: 1-6. <https://doi.org/10.4102/ojvr.v85i1.1590>
- For Peer Review Only Veterinarni Barta, J.R., Martin, D.S., Liberator, P.A., Dashkevich, M., Anderson, J.W., Feighner, S.D., Elbrecht, A., Perkins-Barrow, A., Jenkins, M.C. and Danforth, H.D., 1997. Phylogenetic relationships among eight *Eimeria* species infecting domestic fowl inferred using complete small subunit ribosomal DNA sequences. *J. Parasitol.*, **83**: 262-271. <https://doi.org/10.2307/3284453>
- Fry, M. and Williams, R.B., 1984. Effects of decoquinat and clopidol on electron transport in mitochondria of *Eimeria tenella* (Apicomplexa: Coccidia). *Biochem. Pharmacol.*, **329**: 229-240. [https://doi.org/10.1016/0006-2952\(84\)90480-5](https://doi.org/10.1016/0006-2952(84)90480-5)
- Gadelhaq, M.S. and HAbdelaty, A., 2019. The occurrence and distribution pattern of *Eimeria* species among domestic pigeons in Minia, Egypt. *J. vet. med. Res.*, **26**: 164-173. <https://doi.org/10.21608/jvmr.2019.66098>
- Gangadoo, S., Stanley, D., Hughes, R.J., Moore, R.J. and Chapman, J., 2016. Nanoparticles in feed: Progress and prospects in poultry research. *Trends Fd. Sci. Technol.*, **58**: 115-126. <https://doi.org/10.1016/j.tifs.2016.10.013>
- Grabosch, S.M., Shariff, O.M. and Helm, C.W., 2018. Non-steroidal anti-inflammatory agents to induce regression and prevent the progression of cervical intraepithelial neoplasia. *Cochrane Database Syst. Rev.*, <https://doi.org/10.1002/14651858.CD004121.pub4>
- Hafeez, M.A., Akhtar, M. and Hussain, I., 2006. Protective effect of egg-propagated *Eimeria tenella* (local isolates) gametocytes as vaccine (s) against mixed species of coccidia in chickens. *Parasitol. Res.*, **98**: 539-544. <https://doi.org/10.1007/s00436-005-0113-8>
- Hafeez, M.A., Sattar, A., Ashraf, K., Mehdi, M., Rafique, A., Mahmood, M.S. and Zia, M.R., 2020. Effect of ibuprofen alone and in conjugation with vitamin e and selenium on experimentally induced coccidiosis in broiler's. *J. Anim. Pl. Sci.*, **30**: 627-633. <https://doi.org/10.36899/JAPS.2020.3.0074>
- Helmboldt, C.F. and Bryant, E.S., 1971. The pathology of necrotic enteritis in domestic fowl. *Avian Dis.*, **15**: 775-780. <https://doi.org/10.2307/1588866>
- Hornok, S., Szell, Z., Shibalova, T.A. and Varga, I., 1999. Study on the course of *Cryptosporidium baileyi* infection in chickens treated with interleukin-1 or indomethacin. *Acta Vet. Hung.*, **47**: 207-216. <https://doi.org/10.1556/004.47.1999.2.6>
- Idris, M., Abbas, R.Z., Masood, S., Rehman, T., Farooq, U., Babar, W., Hussain, R., Raza, A. and Riaz, U., 2017. The potential of antioxidant rich essential oils against avian coccidiosis. *World Poult. Sci. J.*, **73**: 89-104. <https://doi.org/10.1017/S0043933916000787>
- Joyner, L. and Norton, C., 1977. The anticoccidial effects of amprolium, dinitolmide and monensin against *Eimeria maxima*, *E. brunetti* and *E. acervulina* with particular reference to oocyst sporulation. *Parasitology*, **75**: 155-164. <https://doi.org/10.1017/S0031182000062296>
- Khalique, K., Akhtar, M., Awais, M.M. and Anwar, M.I., 2017. Evaluation of immunotherapeutic effects of Aloe vera polysaccharides against coccidiosis in chicken. *Kafkas Üniv. Vet. Fak. Derg.*, **23**: 895-901.

- <https://doi.org/10.29261/pakvetj/2018.063>
- Kiran, K., Saleem, F., Awan, S., Ahmad, S., Ahmad, S., Arshad Malik, M. A. and Sharif, A., 2018. Anti-inflammatory and anticancer activity of pteris cretica whole plant extracts. *Pak. Vet. J.*, **38**: 225-230.
- Krautwald-Junghanns, M.E., Zebisch, R. and Schmidt, V., 2009. Relevance and treatment of coccidiosis in domestic pigeons (*Columba livia forma domestica*) with particular emphasis on toltrazuril. *J. Avian med. Surg.*, **23**: 1-5. <https://doi.org/10.1647/2007-049R.1>
- Latshaw, J.D., 1991. Nutrition mechanisms of immunosuppression. *Vet. Immunol. Immunopathol.*, **30**: 111-120. [https://doi.org/10.1016/0165-2427\(91\)90012-2](https://doi.org/10.1016/0165-2427(91)90012-2)
- Lillehoj, H.S. and Lillehoj, E.P., 2000. Avian coccidiosis. A review of acquired intestinal immunity and vaccination strategies. *Avian Dis.*, **44**: 408-425. <https://doi.org/10.2307/1592556>
- Lillehoj, H.S., 1998. Role of T lymphocytes and cytokines in coccidiosis. *Int. J. Parasitol.*, **28**: 1071-1081. [https://doi.org/10.1016/S0020-7519\(98\)00075-7](https://doi.org/10.1016/S0020-7519(98)00075-7)
- Long, J.R. and Barnum, D.A., 1974. Necrotic enteritis in broiler chickens II. Pathology and proposed pathogenesis. *Can. J. comp. Med.*, **38**: 467-474.
- Macdonald, S.E., Nolan, M.J., Harman, K., Boulton, K., Hume, D.A., Tomley, F.M., Stabler, R.A. and Blake, D.P., 2017. Effects of *Eimeria tenella* infection on chicken caecal microbiome diversity, exploring variation associated with severity of pathology. *PLoS One*, **12**: 9-12. e0184890. <https://doi.org/10.1371/journal.pone.0184890>
- Mellouk, S., Green, S.J., Nacy, C.A. and Hoffman, S.L., 1991. IFN-gamma inhibits 363 development of Plasmodium berghei exoerythrocytic stages in hepatocytes by an L364 arginine-dependent effector mechanism. *J. Immunol.*, **146**: 3971-3976.
- Migaki, T.T. and Babcock, W.E., 1983. Evaluation of an improved floor pen model for severe coccidiosis. *Avian Dis.*, **27**: 1-6. <https://doi.org/10.2307/1590366>
- Muller, A., Wiedmer, S. and Kurth, M., 2019. Risk evaluation of passive transmission of animal parasites by feeding of black soldier fly (*Hermetia illucens*) larvae and prepupae. *J. Fd. Prot.*, **82**: 948-954. <https://doi.org/10.4315/0362-028X.JFP-18-484>
- Noack, S., Chapman, H.D. and Selzer, P.M., 2019. 6 Chapter anticoccidial drugs of livestock and poultry industries. *Coccidiosis Livest. Poult. Comp. Anim. Hum.*, pp. 65. <https://doi.org/10.1201/9780429294105-6>
- Odden, A., Enemark, H.L., Ruiz, A., Robertson, L.J., Ersdal, C., Nes, S.K. and Stuenkel, S., 2018. Controlled efficacy trial confirming toltrazuril resistance in a field isolate of ovine *Eimeria* spp. *Parasit. Vectors*, **11**: 394. <https://doi.org/10.1186/s13071-018-2976-4>
- Ovington, K., Alleva, L. and Kerr, E., 1995. Cytokines and immunological control of *Eimeria* spp. *Int. J. Parasitol.*, **25**: 1331-1351. [https://doi.org/10.1016/0020-7519\(95\)00069-E](https://doi.org/10.1016/0020-7519(95)00069-E)
- Palocz, O., Gal, J. and Csiko, G., 2016. Differences in NSAID toxicity in four avian species. *J. vet. Sci. med. Diagn.*, **5**: 2.
- Peek, H. and Landman, W., 2003. Resistance to anticoccidial drugs of Dutch avian *Eimeria* 370 spp. field isolates originating from 1996, 1999 and 2001. *Avian Pathol.*, **32**: 391-401. <https://doi.org/10.1080/0307945031000121149>
- Pop, L.M., Varga, E., Coroian, M., Nedişan, M.E., Mircean, V., Dumitrache, M.O. and Györke, A., 2019. Efficacy of a commercial herbal formula in chicken experimental coccidiosis. *Parasit. Vectors*, **12**: 343. <https://doi.org/10.1186/s13071-019-3595-4>
- Rainsford, K.D., 2009. Ibuprofen: Pharmacology, efficacy and safety. *Inflammopharmacology*, **17**: 275-342. <https://doi.org/10.1007/s10787-009-0016-x>
- Razzaq, A., Islam, M., Ahmad, S., Shideed, K., Shomo, F. and Athar, M., 2012. Prevalence of internal parasites in sheep/goats and effective economic de-worming plan at upland Balochistan, Pakistan. *Afr. J. Biotechnol.*, **11**: 12600-12605. <https://doi.org/10.5897/AJB10.1303>
- Ryley, J.F., Meade, R., Hazelhurst, J. and Robinson, T.E., 1976. Methods in coccidiosis research: Separation of oocysts from faeces. *Parasitology*, **73**: 311-326. <https://doi.org/10.1017/S0031182000046990>
- Shirley, M.W., Smith, A.L. and Blake, D.P., 2007. Challenges in the successful control of the avian coccidia. *Vaccine*, **25**: 5540-5547. <https://doi.org/10.1016/j.vaccine.2006.12.030>
- Soulsby, E.J.L., 1982. *Helminths, arthropods and protozoa of domesticated animals*. (7<sup>th</sup> edition) Baillière Tindall, London. pp. 809.
- Steel, R.G.D., Torrie, J.H. and Dickey, D.A., 1997. *Principles and procedures of statistics a biometrical approach 3<sup>rd</sup> ed.* New York, NY the McGraw-Hill Companies, Inc.
- Sundar, S.B., Harikrishnan, T.J., Latha, B.R., Chandra,



- G.S. and Kumar, T.M.S.A., 2017. Anticoccidial drug resistance in chicken coccidiosis and promising solutions: A review. *J. Ent. Zool. Stud.*, **5**: 1526-1529.
- Tanweer, A.J., Saddique, U., Bailey, C.A. and Khan, R.U., 2014. Antiparasitic effect of wild rue (*Peganum harmala* L.) against experimentally induced coccidiosis in broiler chicks. *Parasitol. Res.*, **113**: 2951-2960. <https://doi.org/10.1007/s00436-014-3957-y>
- Vane, J.R., Mitchell, J.A., Appleton, I., Tomlinson, A., Bishop-Bailey, D., Croxtall, J. and Willoughby, D.A., 1994. Inducible isoforms of cyclooxygenase and nitric-oxide synthase in inflammation. *Proc. natl. Acad. Sci.*, **91**: 2046-2050. <https://doi.org/10.1073/pnas.91.6.2046>
- Venkataratnam, A., Reddy, K., Reddy, P. and Hafeez, M., 1985. Caecal coccidiosis experimental transmission through cloaca and pathogenesis, Cheiron-Tamil Nadu. *J. Vet. Sci. Anim. Husb.*, **14**: 95-97.
- Vermeulen, B. and Remon, J.P., 2001. The oral bioavailability of ibuprofen enantiomers in broiler chickens. *J. Vet. Pharmacol. Therap.*, **24**: 105-109. <https://doi.org/10.1046/j.1365-2885.2001.00311.x>
- Vermeulen, B., Peek, H., Remon, J.P. and Landman, W.J.M., 2004. Effect of ibuprofen on coccidiosis in broiler chickens. *Avian Dis.*, **48**: 68-76. <https://doi.org/10.1637/7059>
- Wang, C., Liu, Y., Zheng, H., Li, Y., He, J., Wang, X. and Zhang, K., 2020. Safety pharmacology assessment of Ethanamizuril, a novel triazines coccidiostat. *Res. Vet. Sci.*, **132**: 271-278. <https://doi.org/10.1016/j.rvsc.2020.07.003>
- Williams, R.B., 2002. Anticoccidial vaccines for broiler chickens: Pathways to success. *Avian Pathol.*, **31**: 317-353. <https://doi.org/10.1080/03079450220148988>
- Yang, W.C., Tien, Y.J., Chung, C.Y., Chen, Y.C., Chiou, W.H., Hsu, S.Y. and Chang, C.L.T., 2015. Effect of *Bidens pilosa* on infection and drug resistance of *Eimeria* in chickens. *Res. Vet. Sci.*, **98**: 74-81. <https://doi.org/10.1016/j.rvsc.2014.11.002>
- Yazdanabadi, F.I., Moghaddam, G.H., Nematollahi, A., Daghighkia, H. and Sarir, H., 2020. Effect of arginine supplementation on growth performance, lipid profile, and inflammatory responses of broiler chicks challenged with coccidiosis. *Prev. Vet. Med.*, **180**: 105031. <https://doi.org/10.1016/j.prevetmed.2020.105031>
- Yun, C.H., Lillehoj, H.S. and Lillehoj, E.P., 2000. Intestinal immune responses to coccidiosis. *Dev. comp. Immunol.*, **24**: 303-324. [https://doi.org/10.1016/S0145-305X\(99\)00080-4](https://doi.org/10.1016/S0145-305X(99)00080-4)