



Seasonal Variation in Ecdysis Process and Parasitic Prevalence in Indian Rock Python (*Python molurus*)

Sumaira¹, Syed Mohsin Bukhari¹, Maqsood Iram², Arshad Javid¹, Ali Hussain¹, Waqas Ali¹, Khalil Ur Rehman³, Shahla Andleeb³, Irfan Baboo⁴ and Nimra Khalid¹

¹Department of Wildlife and Ecology, University of Veterinary and Animal Sciences, Lahore 54000, Pakistan

²Department of Zoology, Shaheed Benazir Bhutto Women University, Peshawar, 25000

³Department of Environmental Sciences, GC Women University, Sialkot, Pakistan

⁴Cholistan University of Veterinary and Animal Sciences, Bahawalpur, Pakistan

ABSTRACT

The effects of feed and environmental factors have been studied in ecdysis process in Indian rock python. Ten experimental animals were observed in captivity and it was noted that ecdysis was more rapid during summer compared to winter. Furthermore, ticks and mites were recorded during both the seasons while internal parasite species belong to genus *Pseudomonas*, *Staphylococcus* and *Streptococcus* were recorded from *Python molurus*. Higher temperature and humidity accelerated the ecdysis process.

Article Information

Received 17 April 2019

Revised 27 July 2019

Accepted 11 September 2019

Available online 17 September 2020

Authors' Contribution

SA presented the concept, organized, analyzed and interpreted the collected data. SMB, IM, WA, NK provided support in experiments and analyzed the data. AH and KR helped during the experiment. AJ helped in data arrangement. SA analyzed the data.

Key words

Ecdysis, Parasites, Environmental factors, Indian python, Seasonal changes

INTRODUCTION

Two species of pythons are reported from India i.e. Indian Rock Python and Burmese Python. Indian Python is considered as an imperiled species in tropical and subtropical zones of Southern and Southeast Asia with a spread going all through the Indian subcontinent. The species has been found to occupy an extensive variety of territories including prairies, swamps, bogs, rough lower regions, forests, scour woodland and waterway valleys (Singh *et al.*, 2018). The snake skin stratified in three layers just like those of others. The deepest layer is delicate and sinewy, the inward layer dermis has color cells and keratin containing layer is called ectoderm/epidermis. New epidermis develops underneath the old, and after it is full-fledged, the snake removes the old skin. This procedure is known as ecdysis or sloughing or shedding (Vyas, 1999). Status of Indian rock python is near threatened. Improper moisture is the typical reason of improper ecdysis in confined snakes. Moisture content of air during molting is essential to avoid desiccation and probably enhanced degree of epidermal water loss (Carlson *et al.*, 2014).

Infestation by ticks is easy to diagnose because they

cause external infections. Both mites and ticks cause anemia leaving the snake weak because they feed on blood of snakes. The symptoms of infections are dysecdysis and the scales having parasites look spotted and they cause soreness and blood clotting on infected areas. The sluggish appearance of snakes is caused by mite infections. Ecdysis could also be initiated by ectoparasites, mites. Ticks are ectoparasites which feed on python's blood (Bartlett and Wagner, 1997). *Ophidascaris* and *Polydelphus* are common parasites in snakes (Rajesh *et al.*, 2015). The python deid in Zoo of Sistan, Iran because of nematode, *Ophidascaris* sp., present in its body. *Ophidascaris filarial* (an Ascarid nematod) infected the Indian python (Ganjali *et al.*, 2015). The bad conditions of keeping python lead to blood poisoning and other infections (Martinez *et al.*, 2006). Captive snakes are most susceptible to endoparasites and if the keeping conditions are bad the infections may lead to death (Vimalraj *et al.*, 2015). Snakes are considered fearsome creatures and there is paucity of information regarding ecdysis process and parasitic prevalence. Present study was therefore planned to study ecdysis process and parasitic prevalence in Indian rock python, *Python molurus*.

MATERIALS AND METHODS

Study area

The study was conducted from December 2017 to

* Corresponding author: sumaairamaan@gmail.com
0030-9923/2020/0006-2341 \$ 9.00/0
Copyright 2020 Zoological Society of Pakistan

January 2018 at University of Veterinary and Animal Sciences Wildlife Breeding Farm, Pattoki and Zoological Garden of Lahore.

Maintenance of snakes

The snakes were kept in a small narrow room having muddy walls and floor. So that they can move easily inside the room without any harm. The snakes were fed with goat stomach and egg every fortnightly in winters and weekly in summers. The temperature of room was kept optimum during winters with the help of heater. The behavior during ecdysis period was also observed routinely from 9:00 AM to 4:00 PM. Length and weight were also taken.

Observation on ecdysis

Snakes were kept in separate transparent glass boxes containing paper floor, pot of water, masking box and soft cuttings of wood to help ecdysis process (Chiszar *et al.*, 1992; Tusler *et al.*, 2015). The temperature and humidity were main factors to regulate ecdysis in Indian python. Temperature was recorded on daily basis from December 2017 to January 2018 by thermometer. When temperature exceeded to suitable range, was maintained by making rooms' walls wet in summer and by gas heaters in the enclosures in winters. The humidity was recorded by hygrometer hanged at walls of enclosures on daily basis during the study duration. Low humidity was also maintained by making walls wet and by putting water pots. The ecdysis was observed on regular basis during winter and summer. For their help to shed wood shavings were provided on the floor and a thick stem having rough bark was also dug in their cages.

Observation on ectoparasites

The pythons were examined physically on an examination table with the help of magnifying glass for the detection of presence of acari. Acari were found in spectacle and under the scales. Present ectoparasites were removed by gloves wearing hands or with the help of forceps. Ticks were removed physically with the help of tweezers. Ticks were grabbed near their mouthparts so that they also removed otherwise could cause diseases. Preserved ticks in 70% ethanol for identification. Lactophenol was used to clear the mites before mounting. Small drop of Glycerin jelly (mounting medium) was spread on slide. Positioned the mite on slide to fix it in medium and dried at 40°C for 5-10 min. Microorganism observed under microscope by a drop of glycerin jelly on the specimen and place cover slip.

Treatment of snakes infested with ectoparasites and bacteria infections

Flea spray was used to cure mites by wetting a soft towel and wiping infested Indian pythons. This treatment

done for 10 days after diagnosis and floor was covered with newspaper so the mites would have no hiding places. Warm water and 10-15% formalin solution were used to disinfect the room of Indian python. During the month of treatment, no water pot was kept inside the room. Examination for re infestation was done on regular basis to keep pythons healthy and fit.

Henderson (2001) was followed for preparing mounts of mites. Causative agents of infectious stomatitis are fungi, bacteria and viruses. Main agent of infectious stomatitis is *Aeromonas*. *Mycobacterium*, *Salmonella* and *Pseudomonas* are also causing agents of stomatitis in snakes. Oral cultures of gram negative and gram-positive bacterial cultures showed *Pseudomonas* and *Aeromonas* cultures also. This disease treated with antiseptics, antibiotics and surgery. Vitamin A and C are used as supplement for primary identification of stomatitis for antibiotic treatment. Antibiotics could be applied directly on infected areas or via injection in muscles. Methylene blue could also be used to cure the stomatitis (Singh *et al.*, 2018).

A python infected with *Ophidoascaris* spp. was observed with fatigue, poor locomotion and dysecdysis. Pyrantel pamoate was used to cure at the dosage of 25 mg per body weight. Gaps of two weeks were taken after every dose and fecal samples were collected every week for observation. After cure, python showed very low number of eggs and started to grow well with better activity and movement.

Micro-biological observations of snake fecal matter

Ten pythons under the study and two samples from each specimen were collected with the help of sterile spatula and stored at 4°C for further processing. Fecal samples were dried for 2 h in Series Thermal-Electric Thermostatic Drying Oven and ground. 0.4 g of sample in Eppendorf tube with 1 ml distilled water by using pipette. Centrifuged the sample at 5000 rpm for 5 min. and used 1 ml from supernatant for serial dilution preparation. All samples serially diluted up to 10 folds 10:1 to 10:8 and subjected to nutrient agar plates. 28 g of nutrient agar was used for 1 liter distilled water and prepared agar solution. Required petri plates, glass tubes and gel solution were sterilized by autoclaving for 45 minutes at 121°C. In biosafety cabinet 20 ml agar was poured in each petri dish and 0.1 ml solution from each dilution was spread with the help of sterilized spreader on solidified gel. Petri plates were incubated at 37°C for 24-48 h in DNP-9052A Laboratory Incubator. Colonies of *Pseudomonas* and *Staphylococcus* were appeared.

Oral swabs were collected from the oral cavity of Indian Pythons for the detection of microbiota. Sterile

swab sticks were used for the collection. The swabs were incubated on petri plates at 37° Celsius for 24-28 hours. The cultures were of different bacteria i.e., *Pseudomonas* spp., *Staphylococcus sciuri*, *Streptococcus* spp.

Observations on blood parasites

Blood samples were collected from the lower sides of the tails 5 cm rear to vent, in this way amount of blood withdrawn was enough for the examination of blood parasites. In this process withdrawal of blood was slow, and no anesthesia used.

The classification and identification of parasites was done by using identification key (Rataj *et al.*, 2011). And in this way the snakes were treated according to the infection.

Statistical analysis

SAS 9.1 software was used to analyze the correlations among humidity, temperature and ecdysis. Microsoft Excel 2010 was used to calculate averages of temperature, humidity and ecdysis.

RESULTS

Treatment of infections

Causative agent of infectious stomatitis are fungi, bacteria and viruses. Main agent of infectious stomatitis are *Aeromonas*, *Mycobacterium*, *Salmonella* and *Pseudomonas*. Oral culture of Gram negative and positive bacterial cultures showed *Pseudomonas* and *Aeromonas*. This disease treated with antiseptic, antibiotics, surgery and vitamin A and C are used for primary identification of stomatitis. Antibiotics could be applied directly on infected areas or via injection in muscles. Methylene blue could also be used to cure the stomatitis (Singh *et al.*, 2018). It is well documented that molting in snakes is dependent on humidity and temperature rather than feeding (Ramesh and Bhupathy, 2013).

Microbiota and endoparasites in fecal matter

Results were found with *Pseudomonas* spp. and *Staphylococcus sciuri*. *Pseudomonas* spp. were showed 60% while *Staphylococcus sciuri* was most abundant bacteria found on petri plates showed 85% growth. *Streptococcus* spp. was also found.

As the fecal samples of all pythons were observed but one python's feces showed eggs of *Ophidascaris* spp. The python infected with *Ophidascaris* spp. was observed with fatigue, poor locomotion and dysecdysis. 430 eggs per gram were counted and cured with 25mg per body weight with pyrantel pamoate. Fecal samples showed very low number of eggs and python started to grow well with better activity and movement after treatment.

Observations on ecdysis and ectoparasites

Proper temperature and humidity management resulted in normal ecdysis. Dysecdysis was only occurred when the ectoparasites attacked the pythons and improper conditions. 10 *Rhipicephalus sanguineus* ticks and 50 mite females *Ophionyssus natricic* were found and also removed by hand and using pesticide sprays. Generalized Linear Model revealed that snakes shed their skin in months with suitable humidity and temperature rather rich feeding. During summer season they leave their tunnels during the period of molting but not in winters. Molting in Indian rock python occurs in whole year except for September; most pythons shed their skin in January and December (Ramesh and Bhupathy, 2013).

Ten *Rhipicephalus sanguineus* ticks were found from ventral and dorsal scales from 3 Indian pythons among which 3 males and 2 females and 5 were larval stages. 4 other Indian pythons were infested with 50 mite females *Ophionyssus natricic*. This mite infection was caused due to unhygienic conditions as workers cleaned the cages after many days and the removed skin and faeces were left in the cage for many days. Due to these mite infections a python showed mouth rot (infectious stomatitis). Open mouth breathing, losing weight, unnecessary salivation and anorexia were the diagnostic signs of infectious stomatitis. Buccal cavity was better and color changed to yellowish grey. Septicaemia was blocked by proper management and cure. As shown in Table I Indian pythons showed more ecdysis in warm months of year; April-October and less rate of ecdysis was observed in cold months; November-March.

The complete round of ecdysis is completed in about two weeks started from diminishing of body color. Day by day the body color continued to become dull and Indian pythons got blackish appearance as shown in Supplementary Figure 1. The spectacle of eyes also became cloudy blue and these all changes took 3-4 days to happen. In these days pythons behaved confused and refused to take feed. In this stage the skin got too fragile to any hard touch as that might damage the underlying new skin which was not fully formed. This was the first stage of ecdysis. At the start of second stage the eyes of pythons got clear and they got their vision back, so they started to search rough surfaces for scratching as shown in Supplementary Figure 2. For their help to shed wood shavings were provided on the floor and also a thick stem having rough bark was dug in their cages which they used to scratch their snouts to initiate the skin removal. Supplementary Figure 3 showing the removal of Indian Pythons skins at UVAS Ravi campus. After this they started to move around the cage and upending their old skin in single piece. Supplementary Figure 4 showing that

proper management of optimum temperature and humidity resulted in normal ecdysis.

Dysecdysis was observed during June 2018 in an Indian Python due to dehydration. The snake rubbed its body with walls of the room and was in discomfort. The skin was removed in the form of patches and not in whole. On some points the old skin remained attached to the new one and removed by hand. Two more Indian pythons showed dysecdysis due to the impact of ticks and mites as these ectoparasites caused skin infections to these Indian pythons.

Figure 1 shows the rate of ecdysis throughout year changing with that of months. In January 2018 no Python underwent ecdysis. From May to September 100% ecdysis was recorded and in April and October 80% ecdysis was recorded. 40% ecdysis was recorded in December 2018 as compared to December 2017 which was 3%.

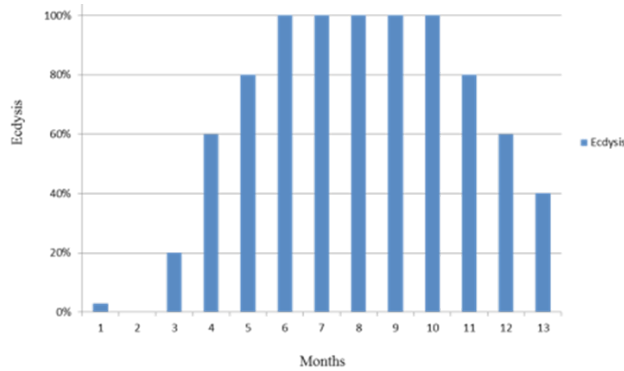


Fig. 1. Ecdysis rate 2018.

The relationship between temperature and ecdysis is positively significant at 1% level of significance with the correlation coefficient of 0.952 while the relationship between humidity and ecdysis is insignificant.

According to Figure 2 temperature has influence on rate of ecdysis of Indian python. The relationship of temperature and ecdysis is directly proportional and positively significant at 1% level of significance with the correlation coefficient of 0.952 as shown in Table II. As with the increase in temperature of the year the rate of ecdysis of Indian python also increases and vice versa. In hot months from April to September 60% to 100% ecdysis was recorded. This showed that high temperature facilitates ecdysis and in this way also helps in the growth of Indian python. Figure 3 shows the relationship of humidity with ecdysis. The humidity and ecdysis showed statistically non-significant correlation as shown in Table II. However, from June to November when the level of humidity was good Indian pythons showed 60% to 85% ecdysis.

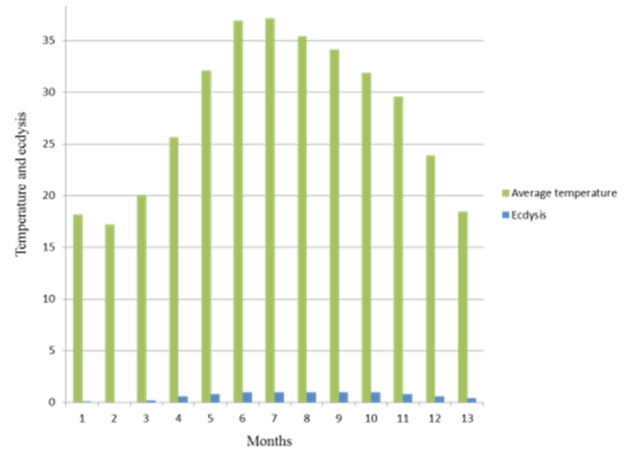


Fig. 2. Ecdysis with respect to temperature.

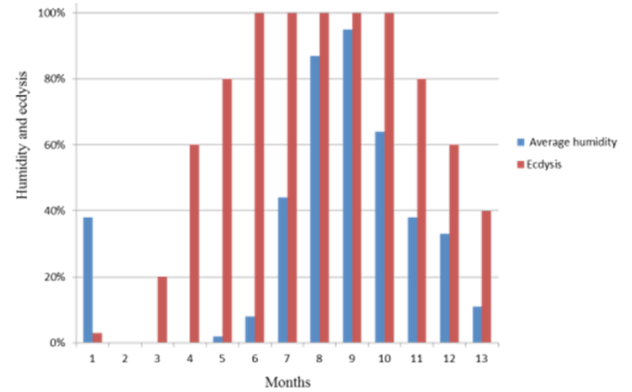


Fig. 3. Ecdysis with respect to humidity 2018.

Table I. Percentage of ecdysis with respect to average temperature and humidity.

Months	Average temperature °C	Average humidity %	Ecdysis %
December 2017	18.16129032	38%	3%
January 2018	17.19354839	0%	0%
February 2018	20.07142857	0%	20%
March 2018	25.64516129	0%	60%
April 2018	32.06666667	2%	80%
May 2018	36.90322581	8%	100%
June 2018	37.16666667	44%	100%
July 2018	35.41935484	87%	100%
August 2018	34.12903220	95%	100%
September 2018	31.86666667	64%	100%
October 2018	29.5483871	38%	80%
November 2018	23.86666667	33%	60%
December 2018	18.4516129	11%	40%

Table II. correlations among humidity, temperature and ecdysis.

Correlations			
	Temperature	Humidity	Ecdysis
Temperature	1	0.50 (0.078)	.952** (0.000)
Humidity		1	0.55 (0.053)
Ecdysis			1

The relationship between temperature and ecdysis is positively significant at 1% level of significance with the correlation coefficient of 0.952 while the relationship between humidity and ecdysis is insignificant.

DISCUSSION

Medications of oral fibroma with anti-toxins and with other chemotherapeutic operators and hyaluronidase for a while were without impact, and no irresistible specialist was segregated from the development. Nevertheless, interminable disturbance was an in all probability inclining 18 factors in the beginning of the mass. The development was ineffectively vascularized and the few veins present come up short on any precise course of action as would be the situation in granulation tissue. Infection and ulceration were watched (Idowu *et al.*, 1975). No oral fibroma was found because of proper management and hygienic conditions. Ulcerative or irresistible stomatitis is an all-around archived infection in snakes. The gram-negative microscopic organisms *Pseudomonas* spp., *Aeromonas* spp., *Proteus* spp., *Providencia* spp., also, *Morganella* spp. are most of the time secluded pathogens. Although the oral sore did not change in size, various subcutaneous knobs developed on the dorsal and sidelong zones of the snake's body (Singh *et al.*, 2018). In my culture *Pseudomonas* spp. and *Staphylococcus* were found. One instance of mycobacterial ulcerative stomatitis joined by subcutaneous granulomas was portrayed in *Boa constrictor*. Diagnosis can for the most part be made on light infinitesimal examination of biopsy example and utilization of special stains. Control of bacterial and parasitic granulomas is accomplished with careful extraction of the sores and proper foundational hostile to microbial treatment. Culture and antibacterial affectability testing are likewise suggested (Abou-Madi *et al.*, 1994). Infectious stomatitis was found in one python showed lesions in buccal cavity and yellowing of inner mouth. Cultures were taken with oral swabs. Snake was found open mouth breathing, poor growth and confusions and cured by applying antibiotics and methylene blue. Be that as it may, the extent of winds in ecdysis was high amid hotter months (April– September). Higher recurrence of sloughing in Indian pythons amid hotter months (June– July) in the Sayaji Baugh Zoo 19 (Vadodara, Gujarat) was

recorded. On the other hand, at Chennai Snake Park, a top five office, ecdysis in *Python reticulatus* was more regular amid colder months. But according to this research the shedding occurs more frequently in hotter months of years from March to October and the rate of ecdysis decreased to considerable amount in colder months from November to February. Coccidian of the genus *Choleoeimeria* was recorded in the gall bladder mucosa of one ball python (Okulewicz *et al.*, 2014) while no coccidian found in my study.

Highly nutritional feed significantly helps in the growth rate of Indian python that directly involves in ecdysis. In addition, high temperature and humidity impact on the growth performance of Indian python and also helps in rate of ecdysis. As this species is very sensitive to parasitic infections, proper management of optimum temperature, humidity and feed is helpful for good health and growth as these parameters regulate the rate of ecdysis. Further research needed for enhance the growth rate and ecdysis against the pathogens by administrative hygienic conditions.

CONCLUSION

It is concluded from this study that proper temperature and humidity combination is necessary for the proper ecdysis process. During this period Indian python is most vulnerable for ectoparasites and endoparasites that can lead to the dysecdysis. Variations in humidity and temperature can influence this process either negatively or positively. Proper control of environmental condition along with the proper control of parasites can enhance the ecdysis process and vulnerability of the species for parasitic attack can be reduced. These findings are beneficial for the ex-situ conservation of the Indian python.

Supplementary material

There is supplementary material associated with this article. Access the material online at: <https://dx.doi.org/10.17582/journal.pjz/20190417060401>

Statement of conflict of interest

The authors declared that they have no competing interests.

REFERENCE

- Abou-Madi, N., Jacobson, E.R. and Buergelt, C.D., 1994. Disseminated undifferentiated sarcoma in an Indian Rock Python (*Python molurus molurus*). *J. Zoo. Wildl. Med.*, **25**: 143-149.
- Bartlett, P. and Wagner, E., 1997. *Pythons, everything about selection, care, nutrition, diseases, breeding and behaviour*. Barrons Educational Series Inc.

- ISBN-10: 812093658.
- Carlson, B.E., Williams, J. and Langshaw, J., 2014. Is synchronized ecdysis in wild ratsnakes (*Pantherophis alleghaniensis*) linked to humidity? *Herpetol. Notes*, **7**: 471-473.
- Chiszar, D. and Smith, H.M., 1992. Cover-seeking behavior and ecdysis in red-spitting cobras (*Naja pallida*). *Bull. Psychon. Soc.*, **30**: 215-216. <https://doi.org/10.3758/BF03330446>
- Drs. Foster and Smith educational staff. Snake shedding: Ecdysis and dysecdysis. pp. 1-2.
- Ganjali, M., Keighobadi, M. and Khedri, J., 2015. First report of *Ophidascaris filarial* (Nematode: Ascarididae) from the Indian python in Sistan, Iran. *Comp. clin. Pathol.*, **24**: 1285-1288. <https://doi.org/10.1007/s00580-015-2146-4>
- Henderson, R.C., 2001. Technique for positional slide-mounting of acari. *Syst. appl. Acarol. P.*, **7**: 1-4. <https://doi.org/10.11158/saasp.7.1.1>
- Idowu, A.L., Golding, R.R., Ikede, B.O., Hill, H., Cunningham, J.H. and Akerele, S.B., 1975. Oral fibroma in a captive python-201. *J. Wildl. Dis.*, **11**: 201-204. <https://doi.org/10.7589/0090-3558-11.2.201>
- Martinez, J., Segura, P., Garcia, D., Aduriz, G., Jose, C., Peris, I.B. and Corpa, J.M., 2006. Septicaemia secondary to infection by *Corynebacterium macginleyi* in an Indian python (*Python molurus*). *Vet. J.*, **172**: 382-385. <https://doi.org/10.1016/j.tvjl.2005.04.027>
- Okulewicz, A., Kazmierczak, M. and Zdrzalik, K., 2014. Endoparasites of exotic snakes (*Ophidia*). *Helminthologia*, **51**: 31-36. <https://doi.org/10.2478/s11687-014-0205-z>
- Rajesh, N.V., Rajesh, K.D., Jayathangaraj, M.G., Raman, M. and Sridhar, R., 2015. Parasitic fauna of captive snakes in Tamilnadu, India. *Asian Pac. J. trop. Dis.*, **5**: 930-934. [https://doi.org/10.1016/S2222-1808\(15\)60834-9](https://doi.org/10.1016/S2222-1808(15)60834-9)
- Ramesh, C., Bhupathy, S. and Ali, S., 2013. Ecdysis in free-ranging Indian rock pythons: a case study. *Hamadryad*, **36**: 130-136.
- Rataj, A.V., Knific, R.L., Vlahovic, K., Mavri, U. and Dovc, A., 2011. Parasites in pet reptiles. *Acta Vet. Scand.* **33**: 1-10. <https://doi.org/10.1186/1751-0147-53-33>
- Singh, J., Mallik, S., Nath, I., Acharya, A., Das, S.P., Sethi, S. and Sahoo, M., 2018. Infectious stomatitis in an Indian rock python (*Python molurus*) and its therapeutic management. *J. Ent. Zool. Stud.*, **6**: 392-394.
- Tusler, C.A., Maggs, D.J., Kass, P.H., Paul-Murphy, J.R., Schwab, I.R. and Murphy, C.J., 2015. Spectral domain optical coherence tomography imaging of spectacular ecdysis in the royal python (*Python regius*). *Vet. Ophthalmol.*, **18**: 1-7. <https://doi.org/10.1111/vop.12176>
- Vyas, R., 1999. Skin molting of Indian rock python *molurus* in captivity. Sayaji Baug Zoo, Vadodara, Gujarat India. *Zoos Print J.*, **1**: 120-125. <https://doi.org/10.11609/JoTT.ZPJ.14.10.120-5>
- Vimalraj, P.G., Latchumikanthan, A. and Abdulsalam, D., 2015. Heavy mixed infection of *Ophiotaenia* Sp. and *Ophidascaris* Sp. in a captive reticulated python (*Python reticulatus*). *Int. J. Agro Vet. med. Sci.*, **9**: 192-194.