OPEN ACCESS
Advances in Animal and Veterinary Sciences

Research Article

Immunopathological and Comparative Study of Concanavalin- A and *Streptococcus lyophilized* Antigen in Immunized Rats

Sura Ayed Radam*, Inam Badr Falih

Department of Pathology and Poultry Disease, University of Baghdad, Collage of Veterinary Medicine, Baghdad, Iraq.

Abstract | Background Concanavalin-A is *a plant lectin* neither antibodies, nor enzymes which has four binding sites for glucose and act as an antigen-independent mitogen, frequently used to stimulate proliferation of T-cells and activate the *immune* response. Aims The present study conducted for showing effect of Concanavalin-A, whole killed lyophilized *Streptococcus pyogenes* antigen(WKLA) on immune response of rat. Methods To achieve this purpose, 20 Albino male rats were divided equally into four groups and immunized subcutaneously(s/c), 1st group was immunized with (100 mg/ml) of *S. pyogenes* antigen with added equal volume of Freund's adjuvant, 2 doses, 14 days intervals, 2nd group was immunized s/c with Concanavalin-A Con-A (1.5 mg/ml), 3rd group was immunized with mixed *S. pyogenes* Ag. and Con-A, 2 doses, 14 days intervals, and 4th group was given Phosphate buffer saline (PBS) as negative control group. Results Analysis of cellular and humeral immunity recorded higher concentration of Immunoglobulin G IgG, Tumer Necrosis Factor alpha TNF-a and Interleukin 10 IL-10 were revealed in 3rd immunized group (40.91 ±0.26, 953.03 ±4.82 and 1223.96 ±10.44) then decline in 2nd and 1st groups as (32.65 ±1.07, 858.42±9.26 and 1223.96±10.44) (21.07 ±0.36, 769.38 ±3.64 and 986.73 ±13.48) respectively. Histopathological findings revealed marked lymphoid hyperplasia with obvious perivascular Mono Nuclear Cells MNCs aggregation composed of lymphocyte and macrophage mainly in hepatic tissue of 3rd group with evidence of reactive lymphoid hyperplasia in splenic tissue of 2nd group and periarteriolar, pericortical lymphoid hyperplasia were reported in spleen of 1st group immunized with *Streptococcus pyogenes* lyophilized antigen. Conclusion This study provide we can conclude that jointly of concanavalin-A and *S.pyogenes* antigen capable to enhance potential immune response butter than antigen alone.

Keywords | Comparative study, *Streptococcus pyogenes*, Concanavalin-A, Lyophilized antigen, Immunized rats, Histopathological

Received | March 17, 2024; **Accepted** | April 07, 2024; **Published** | May 27, 2024
***Correspondence** | Sura Ayed Radam, Department of Pathology and Poultry Disease, University of Baghdad, Collage of Veterinary Medicine, Baghdad, Iraq; **Email:** Sura.radam@covm.uobaghdad.edu.iq
Citation | Radam SA, Falih IB (2024). Immunopathological and comparative study of concanavalin- a and *Streptococcus lyophilized* antigen in immunized rats. Adv. Anim. Vet. Sci., 12(7):1317-1324.
DOI | https://dx.doi.org/10.17582/journal.aavs/2024/12.7.1317.1324
ISSN (Online) | 2307-8316

Copyright: 2024 by the authors. Licensee ResearchersLinks Ltd, England, UK.
This article is an open access article distributed under the terms and conditions of the Creative Commons Attribution (CC BY) license (https://creativecommons.org/licenses/by/4.0/).

INTRODUCTION

Streptococcus pyogenes is a gram-positive, Beta B-hemolytic and catalase-negative bacteria (Sadam *et al.*, 2014) produced biofilm formation on mucosal membranes facilitating their prolonged survival (Cinthia *et al.*, 2020) like other gram positive bacteria (Mohammed and Zaid, 2024) as *staphylococcus aureus* (Ali and Alaa, 2022), Group A streptococcus possessed wide variety of virulence factors on their surface such as hyaluronic capsule, M protein, streptolysin O and S, streptococcal pyrogenic exotoxins A and B (Syed *et al.*, 2020; Nikolai and Rudolf, 2021). Some exotoxin act as superantigens and trigger T-lymphocytes excessive stimulation by attaching to class II major

histocompatibility complex molecules, show the way to release of massive mediators of T cell (Akshay, 2019; Anthony *et al*., 2021), depending on virulence and sequalae of bacteria post infection can categorized into two classes: Class I strains cause suppurative inflammation such as meningitis and abscess in both brain and liver while class II strains cause non suppurative inflammation like acute glomerulonephritis and rheumatic fever (Niluni *et al*., 2021; Patience *et al*., 2023).

Concanavalin-A, is defense glycoprotein from Jack bean have mitogenic activity, binding with carbohydrate without modified their biochemical activity (Evandro *et al*., 2017; Abtar *et al*., 2019) and induce the growth, divided of quiescent lymphocytes then activate innate and adaptive immune response by enhancing phagocytic mechanism(Blaise *et al*., 2019), releasing chemical mediators and several cytokines such as Tumer Necrosis Factor alpha TNF-α, Interferon gamma IFN-γ, granulocyte macrophage-colony stimulating factor, and interleukins, that maintain inflammatory and immuno-stimulatory reaction (Sabrin *et al*., 2021) thus improvement the defenses against microbial infection (Batista *et al*., 2017; Jannyson *et al*., 2017; Emadeldin *et al*., 2022) but these phenomena not occur in non-mitogenic lectins (Evandro *et al*., 2017). The present study aimed to investigate the immunomodulator effect of Concanavalin-A Con-A as compare with whole killed lyophilized *Streptococcus pyogenes* antigen in activation of both immune arms including cell mediated and humoral immunity.

MATERIALS AND METHODS

Sample collection and bacterial identification

About 50 throat swabs were collected from sheep showing obvious respiratory signs during the duration from January to May 2022, and these isolates identified by routine culturing, gram stain and confirmatory by biochemical indole test (vitek-2 system) to recognize the isolated bacteria to the genus and species level according to (Alaa *et al*., 2022).

Preparation of *Streptococcus pyogenes* antigen

The *S.pyogenes* antigen was prepared according to (Nguyen *et al*., 2022), then lyophilized and measured the protein concentration by Biuret method (Randox Lab). It was kept under 4 °C in a refrigerator until use as antigen in experimental rats, when used re-suspended by adding 2 ml of Phosphate buffer saline PBS to 2 gm of dry lyophilized antigen to make stock solution according to (Rafeek *et al*., 2021).

Preparation of con-A

Each vial contained 100 mg of lyophilized Concanavalin-A Con-A powder was dissolve in 66.7 ml of sterile phosphate buffer saline then kept as stock solution of (1.5) mg/ml at 4°C in dark vial and each animal received two doses, 14 days intervals(1.5mg/kg B.W.) with dose volume was (0.1) ml per (100)gm of rat weight by intraperitoneal rout, which is representing the ideal therapeutic dose according to (Xu *et al*., 2006; Anroop and Shery, 2016; Kathem *et al*., 2022).

Animal immunization

Twenty male rat were distributed randomly into four groups and immunized subcutaneously, 1st group was immunized with (100) µl of *S. pyogenes* antigen (100 mg/ml) mixed with equal volume of Freund's adjuvant, 2nd group was immunized with (1.5) ml of Concanavalin-A Con-A(20 mg/ml), 2 doses and 3rd group was immunized with mixed *S. pyogenes* Antigen Ag. and Concanavalin-A Con-A, 4th group was inoculated with Phosphate buffer saline PBS as negative control group, each 1st and 3rd groups administrated booster dose after 14 days with equal volume of Freund's adjuvant (First immunization in Freund's complete adjuvant at 0 day and followed with booster immunization in Freund's incomplete adjuvant after 14 day of immunization) according to (Yang *et al*., 2011).

At 28 day post immunization, blood samples were obtained for check cellular and humoral immune response by cytokines and Immunoglobulin G IgG measurement, with taken tissue sampling involving spleen and liver for histopathological examination.

Histopathological examination

Experimental rats were euthanized and a full necropsy was performed to detect any abnormalities and gross changes in liver and spleen that dissected after that 1c.m^3 from organs were taken then fixed in 10% neutral buffered formalin for (2-3) days, then routinely processed in histokinette (ATP-1000\HESTION), tissue sections were embedded in paraffin (Eman *et al*., 2016) after that paraffin blocks with implanted tissue slices were sectioned at 5 µm thickness by microtome) (Yidi) (Ahmed and Bushra, 2013), and staining by routine hematoxylin and eosin stain then examined under light microscope(Olympus) according to (Steven and Bancroft, 1997).

Statistical analysis

SAS program was used to analyze the data and find the influence of various factors on the study's parameters. The Least Significant Difference (LSD) test was used for analysis of variance by using Analysis of variance ANOVA. Two ways to identify the results' significant differences for the result were determined at ($P \leq 0.05$) according to (SAS, 2018).

Table 1: Mean and standard error of (IgG, TNF-a and IL-10) titers of the 1st , 2nd and 3rd immunized groups and 4th control negative groups at 28 day post immunization.

Groups	Mean ± SE of IgG, TNF-a and IL-10 (nm)		
	IgG	TNF-a	IL-10
1st group immunized with WKLAg	21.07 ±0.36 C	769.38 ±3.64 C	986.73 ±13.48 B
2nd group immunized with Con-A	32.65 ±1.07 B	858.42 ±9.26 B	1223.96 ±10.44 A
3rd group immunized with Mixed Antigene	40.91 ±0.26 A	953.03 ±4.82 A	1275.35 ±7.26 A
4th group non- immunized Control negative	12.22 ±0.23 D	364.79 ±4.91 D	372.83 ±14.96 C

Capital different letters denoted that significant difference between groups (P≤0.05).

RESULTS AND DISCUSSION

Biochemical identification of bacteria

The isolate was identified by using Gram stain based on colony morphology under the light microscope with evidence of gram-positive cocci, arranged in single or pairs, long or short chains as Figure 1.

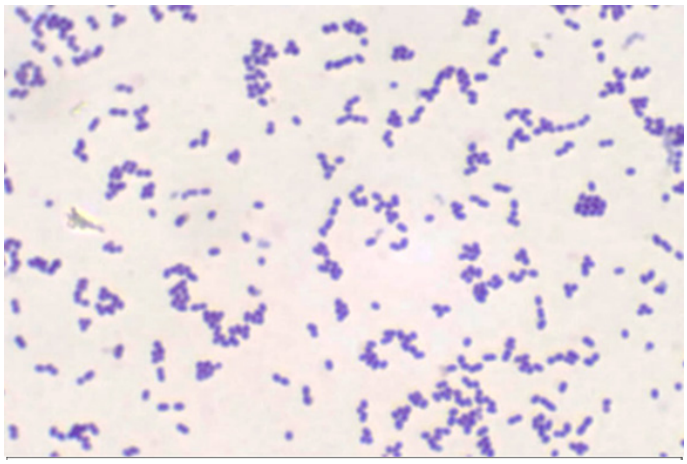

Figure 1: Gram positive *S. pyogenes* cocci (X100).

Another biochemical analysis used Vitek-2 system as speed and accuracy test for proof identification of Group A *streptococcus pyogenes* GAS bacteria with a probability ratio (97%) depended on the results of 64 biochemical tests as shown in microbiological chart report Figure 2.

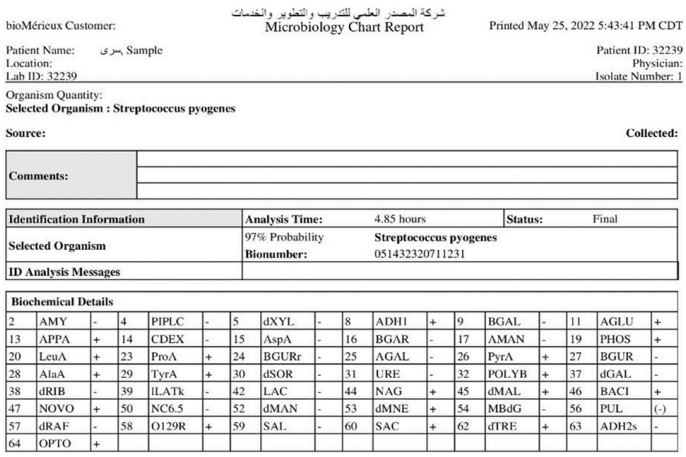

شركة المصدر العلمي للتدريب والتطوير والخدمات
bioMérieux Customer: Microbiology Chart Report Printed May 25, 2022 5:43:41 PM CDT

Patient Name: مرى Sample Patient ID: 32239
Location: Physician:
Lab ID: 32239 Isolate Number: 1

Organism Quantity:
Selected Organism : Streptococcus pyogenes

Source: **Collected:**

Comments:	

Identification Information	**Analysis Time:** 4.85 hours	**Status:** Final
Selected Organism	97% Probability **Streptococcus pyogenes** **Bionumber:** 051432320711231	
ID Analysis Messages		

Biochemical Details

2	AMY	-	4	PIPLC	-	5	dXYL	-	8	ADH1	+	9	BGAL	-	11	AGLU	+
13	APPA	+	14	CDEX	-	15	AspA	-	16	BGAR	-	17	AMAN	-	19	PHOS	+
20	LeuA	+	23	ProA	+	24	BGURr	-	25	AGAL	-	26	PyrA	+	27	BGUR	-
28	AlaA	+	29	TyrA	+	30	dSOR	-	31	URE	-	32	POLYB	+	37	dGAL	-
38	dRIB	-	39	ILATk	-	42	LAC	-	44	NAG	+	45	dMAL	+	46	BACI	+
47	NOVO	+	50	NC6.5	-	52	dMAN	-	53	dMNE	+	54	MBdG	-	56	PUL	(-)
57	dRAF	-	58	O129R	+	59	SAL	-	60	SAC	+	62	dTRE	+	63	ADH2s	-
64	OPTO	+															

Figure 2: Microbiological chart report of vitek-2 test.

Humoral and cellular response in immunized rat (ELISA technique)

The serological finding of 3rd immunized group recorded significantly elevator in Abs titer (40.91±0.26) and both Tumer Necrosis Factor TNF and Interleukin 10 IL10 (953.03±4.82, 1275.35±7.26), respectively when performed at 28 day post immunization, with noticeable decreased in 2nd and 1st groups for Immunoglobulin G IgG concentration (32.65±1.07 and 21.07±0.36) consecutive and for mention's cytokines as (858.42±9.26, 769.38±3.64 and 1223.96±10.44, 986.73±13.48), respectively compared with negative control group as above (12.22±0.23, 364.79± 4.91 and 372.83±14.96), with significant difference P≤0.05 as in Table 1 and Figure 3.

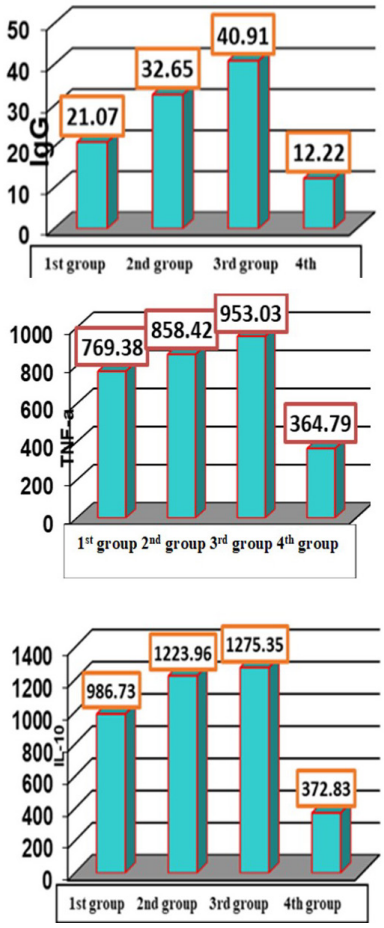

Figure 3: Mean and standard error of (IgG, TNF-a and IL-10) titers of the 1st, 2nd and 3rd immunized groups and 4th control negative groups at 28 day postimmunization.

Links Researchers

Postmortem examination

Estimation of any gross and histopathological lesions associated with immunization was carried out. No gross changes associated with immunization in any organ, except various degree of hepato- splenomegaly were recorded mainly in 3rd mixed immunized group and 2nd group immunized with concanavalin-A in comparison with other groups as Figure 4A and B.

Microscopical examination

Histopathological changes in liver tissue of 1st group immunized with whole killed lyophilized antigen of *S.pyogenic* exhibited focal Mono Nuclear Cells MNCs infiltration with obvious binucleated hepatocyte Figure 5A, another section show hepatic edema with hepatocyte anisonucleosis Figure 5B, while splenic observation showed reactive lymphoid hyperplasia with slight red pulp congestion Figure 5C, together with marked paracortical lymphoid hyperplasia as Figure 5D.

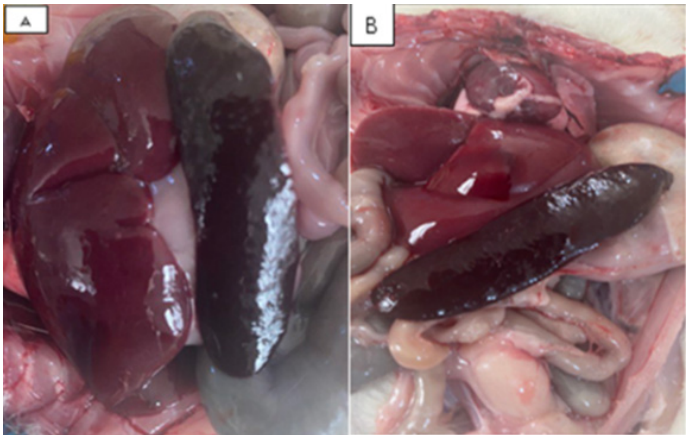

Figure 4: Gross appearance of hepatosplenomegaly in 3rd group (A) and 2nd group (B).

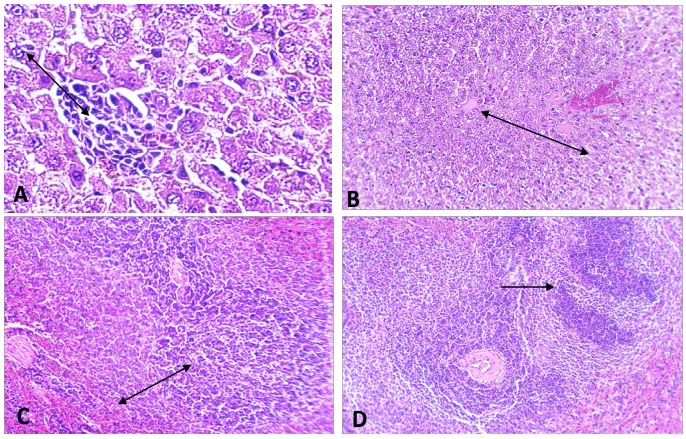

Figure 5: A histopathological slices in rat immunized with WKL Ags. at 28 day post immunization. (A) Liver showed focal MNCs infiltration in liver tissue with obvious binucleated hepatocyte. (B) Liver showed edema in hepatic tissue with anisonucleosis. (C) Spleen showed reactive lymphoid hyperplasia with slight red pulp congestion. (D) Spleen showed obvious paracortical lymphoid hyperplasia.

The pathological picture of liver in 2nd group immunized with Concanavalin-A Con-A perceive perivenular Mono Nuclear Cells MNCs infiltration with hepatic vasodilation Figure 6A, another section represents slight portal MNCs infiltration with ductal dilation Figure 6B, while the splenic tissue appeared with reactive lymphoid hyperplasia with slight splenic vessels congestion Figure 6C, another section clarified lymphoid hyperplasia with vascular fibromuscular hypertrophy Figure 6D.

The liver tissue manifestation of 3rd mixed immunized group referred perivascular and periductal Mono Nuclear Cells MNCs infiltration with nuclear pyknosis and the cytoplasm of hepatocyte appear hyper eosinophilic Figure 7A, while another section showed mild periductal Mono Nuclear Cells MNCs infiltration with obvious ductal dilation Figure 7B, as well as evidence of periarteriolar lymphoid hyperplasia were recorded in splenic tissue Figure 7C, accompanied with great lymphoid hyperplasia and red pulp congestion Figure 7D.

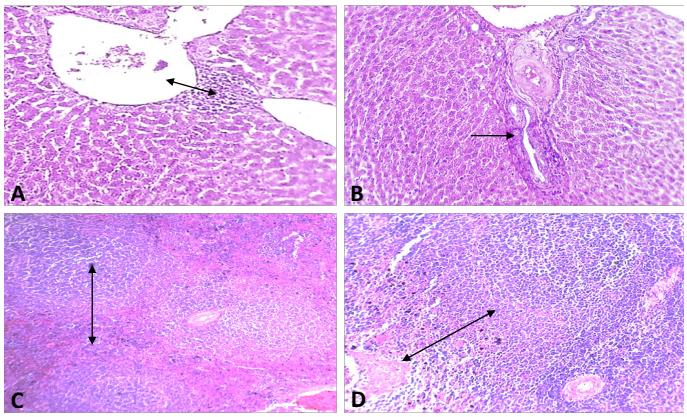

Figure 6: A histopathological slices in rat immunized with Con-A at 28 day post immunization. (A) Liver showed perivenular MNCs infiltration with ductal dilation. (B) Liver showed slight portal MNCs infiltration with ductal dilation. (C) Spleen showed reactive lymphoid hyperplasia with slight splenic vessels congestion. (D) Spleen showed lymphoid hyperplasia with vascular fibromuscular hypertrophy.

Streptococci are pathogenic bacteria affect humans and animals cause invasive infection and produced many virulence factors and toxins help escaping the host immune response (Simone *et al*., 2022) such as M related surface protein as primary antigenic factor have critical role in phagocytic survival and providing antiphagocytic functions also given continuous ability for *Streptococcus pyogenes* to diversity and variable for that no safe and effective vaccine only slight known about anti- Group A *streptococcus pyogenes* GAS protective immunity (Douglas *et al*., 2022).

As the first step toward biochemical identification of Beta

Links Researchers

B-hemolytic Group A *streptococcus pyogenes* GAS bacteria used gram stain as analysis method to detect the presence of single or pair gram positive streptococci (Abdur Rehman *et al*., 2021) when culture in blood agar under (5-10%) Co_2 condition at 37°C for 24 hours show the B-hemolytic (Mais *et al*., 2018; Minas *et al*., 2022), these cocci stained dark purple color because their peptidoglycan cell wall that absorbed crystal violet while (Amity *et al*., 2012; Al-Ogaidi *et al*., 2020) indicated staining of microcolonies by blue -violet color revealed investigative of biofilms in specimens that give positive result for present of *streptococcus pyogenes*, However in current study a specific selective media for *S. pyogenes* were used and the bacterial colonies appeared as small white colonies.

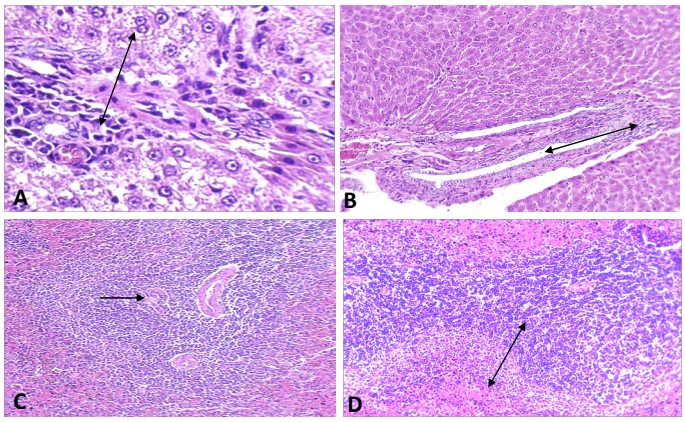

Figure 7: A histopathological slices in rat immunized with mixed Ag. at 28 day post immunization. (A) Liver showed perivascular and periductiolar MNCs infiltration with nuclear pyknosis and hyper eosinophilic of hepatocyte cytoplasm. (B) Liver showed mild periductal MNCs infiltration with obvious ductal dilation. (C) Spleen showed periarteriolar lymphoid hyperplasia. (D) Spleen showed great lymphoid hyperplasia with red pulp congestion.

The result of vitek-2 test agent with 10 samples encountered with present isolates that obtained from sheep suffering from respiratory symptoms and explain by (Kadhum and Hussain, 2020; Abbas *et al*., 2022) who referred that vitek-2 anew automated and exactness technique used for rapid identification of *S. pyogenes*. In order to activate immune system some mitogenic substance was used in current study like Concanavalin-A con-A can recruit lymphocyte and elicit cytokine production together with increased Antibody Ab titers in immunized groups compared with control group, these observation supported by study of (Huldani *et al*., 2022) whose revealed that administration of non-toxic dose of Concanavalin-A con-A has essential role in activation of immune cells including neutrophils, kupffer and B cells distinguished in liver and production massive amount of lymphokines as result from their mitogenic activity in murine, Also study by (Beilei *et al*., 2022) explain the Concanavalin-A Con-A ability to binding with several receptors like Membrane Type Matrix Metallo Proteinase-1 (MT1-MMP) in normal and cancer cells which accountable for lectin's modulations, oscillating from triggering immune cells to kill of tumor cell moreover to study consequence of Concanavalin-A Con-A on signaling ability to induce autophagy and apoptosis together with modulate related signaling cascades these finding mainly recognized in hepatic tissue of 3rd immunized group.

The analysis of Immunoglobulin IgG, Tumor Necrosis Factor TNF-a and Interleukin 10 IL-10 in the present work revealed a significant elevator in all immunized groups at 28 day post immunization specially in 3rd group and this result accorded with (Roua and Ikram, 2021) who showed substantial increasing in antibody concentration with significant difference between groups ($P<0.05$) at 28 days post immunization compared with the negative control group, for record these elevate in cytokines used Enzyme-Linked Immunosorbent Assay ELISA technique according to (Agharid *et al*., 2022).

According to above histopathological evidence, perivenular and periductular Mono Nuclear Cells MNCs infiltration mainly in hepatic tissue of mixed immunized group because the liver is an chief fence between us and openair world and have ability to mount a rapid and robust immune response under appropriate conditions, also has capability to screen and immunological filtrate the blood and designer to reveal, catch, and visible bacteria, virus, macromolecules and great gathering of phagocytic cells in body however immune suppression can occur due to absenteeism of costimulatory molecules, to the relative low expression of *Major Histocompatibility Complex* MHC, and expressing of anti-inflammatory cytokines such as IL-10 (Paul and Craig, 2018).

Various forms of lymphoid hyperplasia were main finding in 2nd and 3rd groups related with elevated of bacterial load and proliferated of B and T-lymphocyte, This phenomena has been associated with many bacterial types including *Staphylococcus aureus*, *Haemophilus influenzae, S. pneumoniae* and Group A *streptococcus pyogenes* GAS (Amity *et al*., 2012). *In vitro*, streptococcal pyrogenic exotoxin A (SPEA) stimulate murine T-lymphocyte result by serial of varied seen in lymphoid tissues after streptococcal sepsis were consistent with an *in vivo* superantigen response as well as proinflammatory streptococcal pyrogenic exotoxin A (SPEA) induced responses can provide for protecting innate responses through aggressive sepsis (Donlan, 2001), our result concluded that display to bacterial superantigen in sepsis performed directly to infiltrate lymphoblastic tissues mainly in splenic immunized group and confirmed best correlation between immunological and pathological finding.

Links Researchers

Subcutaneous immunization with streptococcus antigen accompanied with adjuvant enhancement potential effect of immune response as compared with negative control group and this observation consistence with several authors idea who mentioned that subcutaneous (Edilberto *et al*., 2013) intramuscular (Tan *et al*., 2021) and intranasal (Aniela *et al*., 2018) vaccination with effective adjuvanted protein prevent even fatal invasion infections in mice, but great improvement in immune response reported in mixed immunized group and that may indicate passive transfer of immunity used antisera and collective human immunoglobulin when it's highly concentration successful to induce immunity in animal models (Reglinski *et al*., 2015). Obvious reduction in the Immunoglobulin G IgG levels were recorded in the streptococcus antigen immunized group as compared with other immunized groups this evidence may be due to regulation activity of streptococcal cysteine protease, Streptococcal pyrogenic exotoxin B Spe B, by cleaving bacterial and host protein also may be explained that Strep A strategic for inhibiting antibody function include specific proteases of Immunoglobulin G IgG, Ides and EndoS, that split antibodies at Fc region (Ulrich *et al*., 2002). There are many theories explained the ability of Strep A antibodies confer protection one of them Strep A innate immunity is type-specific and focused against M-protein, builds specific responses accountable for safeguard and another theory mention that immune responses accumulate with recurrent exposure to conserved Strep A antigens resulted in elevation threshold of protection against following infection (Pandey *et al*., 2012). Streptococcus pyogenes has developed numerous mechanisms to alter the structure and function of Immunoglobulin G IgG to avid Antibody Ab mediated immune response (Toledo *et al*., 2023).

CONCLUSIONS AND RECOMMENDATION

The result concluded that Concanavalin-A Con-A have immunological effect by enhancing both pro and anti-inflammatory cytokine when given in non-toxic dose, also Concanavalin-A have the best immunomodulatory effect against *S. pyogenes* infection when mixed with bacterial antigen. The current study recommended for used of farther technique like immunohistochemistry and immunocytochemistry by using several markers together with study the effect of Concanavalin-A on the expression of genes related with virulence and biofilm formation of *S. pyogenes*.

ACKNOWLEDGEMENTS

Many thanks go to the Veterinary Medicine College, University of Baghdad, for providing resources to accomplish this study.

NOVELTY STATEMENT

This report provide A novel mechanism in which Concanavalin-A used as immunomodulator and give supporting for *S. pyogenes* antigens which act as anti-microbial agent.

AUTHOR'S CONTRIBUTION

Sura Ayed Radam and Inam Bader Falih: Designed and Performed the experiments, analyzed the data, contributed reagents, materials, analysis tools and wrote the paper.

Ethical approval

All procedures used in this study were approved by the local Scientific Research Committee of veterinary medicine College, Baghdad University consent with the ethical principles guidelines on the care and use of animals in research of animal welfare (Approval number P.G 380 in 19-2-2024).

Data availability

Data are available upon reasonable request.

Conflict of interest

The authors have declared no conflict of interest.

REFERENCES

Abbas HM, Al-Mathkhury HJ (2020). Isolation and identification of bacteria from Iraqi women with recurrent urinary tract infection. Plant Arch., 20(2): 1838-1842.

Abdur R, Xiukang W, Sajjad A, Farah S, Sidra A, Usman A, Faris A, Muhammad Q, Abeer H, Amal A, Elsayed F (2021). *In silico* core proteomics and molecular docking approaches for the identification of novel inhibitors against *Streptococcus pyogenes*. Int. J. Environ. Res. Publ. Health, 18(21): 11355. https://doi.org/10.3390/ijerph182111355

Abtar M, Assirbad B, Shradha M, Ashish K, Lincoln N, Subhashree SM, Debraj M, Puja D, Amit M, Samir K, Patra, Rohan D (2019). Structure-function and application of plant lectins in disease biology and immunity. Food Chem. Toxicol., 134: 110827. https://doi.org/10.1016/j.fct.2019.110827

Agharid AA, Sana'a SA, Karim AA, Bashiru G (2022). Immunopathological responses to the bovine mastitis associated with *Staphylococcus* species infection. Iraqi J. Vet. Med., 46(2): 7-11. https://doi.org/10.30539/ijvm.v46i2.1398

Ahmed SJ, Bushra IA (2013). Effect of L-Arginine on Some Biochemical and pathological parameter in diabetes mellitus induced by Alloxan-monohydrate in Rats. Al-Anbar J. Vet. Sci., 6(1): 89-100.

Akshay S (2019). Role of the fibronectin-binding, collagen-binding, T-antigen region during nasopharyngeal infection

by *Streptococcuscoccus pyogenes*. Dictoral dissertation. The University of Western Ontario (Canada), pp. 6542.

Alaa QR, Amer AH, Abo A (2022). Molecular diagnosis of *Streptococcus pyogens* by detection virulence factors genes from clinical isolates. HIV Nurs., 22(2): 2557-2561.

Ali HA, Alaa KM (2022). Evaluation of antibacterial and antibiofilm activity of biogenic silver nanoparticles and gentamicin against *Staphylococcus aureus* isolated from caprine mastitis. Iraqi J. Vet. Med., 46(1): 10-16. https://doi.org/10.30539/ijvm.v46i1.1309

Al-Ogaidi M, Al-Ogaidi I (2020). Investigation of the antibacterial activity of gram positive and gram negative bacteria by 405 nm laser and nanoparticles. Plant Arch., 20(1): 1136-1140.

Amity LR, Kristie LC, Daniel JK, Adele KE, Katherine AP, Timothy RP, Sean DR (2012). Detection of group A *Streptococcus* in tonsils from pediatric patients reveals high rate of asymptomatic streptococcal carriage. BMC Pediatrics, 12(1): 1-9. https://doi.org/10.1186/1471-2431-12-3

Aniela W, Natalia S, Patricia CG, James BD, Braulio AP, Paulette L, Francisco JSE, Susan MB, Alexis MK (2018). Protective immunity induced by an intranasal multivalent vaccine comprising 10 Lactococcus lactis strains expressing highly prevalent M-protein antigens derived from group A streptococcus. Med. *Microbiol. Immunol.*, 62(6): 395-404. https://doi.org/10.1111/1348-0421.12595

Anroop BN, Shery J (2016). A simple practice guide for dose conversion between animals and human. J. Basic Clin. Pharm., 7(2): 27–31. https://doi.org/10.4103/0976-0105.177703

Anthony MD, Samuel K-EG, Jeremy PD (2021). Superantigen recognition and interactions: Functions, mechanisms and applications. Front. Immunol., 731845.

Batista J, Ralph MT, Vaz RV, Souza P, Silva AB, Nascimento D (2017). Plant lectins ConBr and CFL modulate expression toll-like receptors, pro-inflammatory cytokines and reduce the bacterial burden in macrophages infected with *Salmonella enterica serovar* Typhimurium. Phytomedicine, 25: 52–60. https://doi.org/10.1016/j.phymed.2016.12.005

Beilei M, Tengkai W, Juan L, Qian W (2022). Extracellular matrix derived from Wharton's Jelly-derived mesenchymal stem cells promotes angiogenesis via integrin αVβ3/c-Myc/P300/VEGF. Stem Cell Res. Therapy, 13(1): 327. https://doi.org/10.1186/s13287-022-03009-5

Blaise D, Léa P, Pascal M, Cattiaux, Jacques F, Jean (2019). Mannose-coated fluorescent lipid microparticles for specific cellular targeting and internalization via glycoreceptor-induced phagocytosis. ACS Appl. Biomatter. 2(11): 5118–5126. https://doi.org/10.1021/acsabm.9b00793

Cinthia A, João P, Teresa S, Alexandra R (2020). Singularities of pyogenic streptococcal biofilms – from formation to health implication. Front. Microbiol., 11: 584947. https://doi.org/10.3389/fmicb.2020.584947

Donlan RM (2001). Biofilm formation: A clinically relevant microbiological process. Clin. Infect. Dis., 33(8): 1387–1392. https://doi.org/10.1086/322972

Douglas C, Hodgins, Raveendra RK, Patricia ES (2022). Subversion of the immune response by bacterial pathogens. Pathogen. Bacter. Infect. Anim., pp. 79-98. https://doi.org/10.1002/9781119754862.ch5

Edilberto P, Raquel A, Fabio TH, Samar FB, Lea MFD, Jorge K, Luiza G (2013). Strep. In Cor: A candidate vaccine epitope against *S. pyogenes* infections induces protection in outbred mice. PLoS One, 8(4): e60969. https://doi.org/10.1371/journal.pone.0060969

Emadeldin HEK, Makarim MO, Amina ID, George GK (2022). Plant lectins: A new antimicrobial frontier. Biomed. Pharmacother., 155: 113735. https://doi.org/10.1016/j.biopha.2022.113735

Eman HA, Omar HK, Fawziaa SK, Rajiha AA (2016). Histological morphology and pathological changes in liver of rats naturally infected with larval stage *Cysticercus fasciolaris* of Taeniae taeniaeformis. Iraqi J. Vet. Med., 40(2): 26-30. https://doi.org/10.30539/iraqijvm.v40i2.107

Evandro, Coelho LC, Silva PM, Lima VL, Pontual EV, Paiva PM, Napoleao TH (2017). Lectins, interconnecting proteins with biotechnological/pharmacological and therapeutic applications. Evid. Based Complement. Altern. Med., 10. https://doi.org/10.1155/2017/1594074

Huldani H, Ahmed IR, Khikmatulla NT, Maria JCO, Walid KA, Dmitry OB, Yasser FM, Moaed EA, Ali TH, Mustafa MK, Seyed HA (2022).Concanavalin A as a promising lectin-based anti-cancer agent: The molecular mechanisms and therapeutic potential. Cell Commun. Signal., 20(1): 167. https://doi.org/10.1186/s12964-022-00972-7

Jannyson JB, Jandú RN, Moraes N, Adrielle Z, Eduardo M, Maria CA, Brelaz C, Maria TSC, Luís CN (2017). Targeting the immune system with plant lectins to combat microbial infections. Front. Pharmacol., 8: 285566. https://doi.org/10.3389/fphar.2017.00671

Kadhum MM, Hussein NN (2020). Detection of the antimicrobial activity of silver nanoparticules biosynthesized by streptococcus pyogenes bacteria. Iraqi J. Agric. Sci., 51(2). https://doi.org/10.36103/ijas.v51i2.976

Kathem SH, Abdulsahib WK, Zalzala MH (2022). Berbamine and thymoquinone exert protective effects against immune-mediated liver injury via NF-κB dependent pathway. Front. Vet. Sci., 9: 960981. https://doi.org/10.3389/fvets.2022.960981

Mais EA, Zainab ZK, Jenan AG, Ahmed QA (2018). Effects of silver nanoparticles on biofilms of *Streptococcus* spp. Indian J. Publ. Health Res. Dev., 9: 1216. https://doi.org/10.5958/0976-5506.2018.02016.8

Minas MB, Adil M, Mohamed M, Adam DA (2022). Molecular Identification of *Streptococcus pyogenes* in Isolates from Children with Pharyngitis, Gezira State, Sudan. Adv. Microbiol., 12(8): 500-510. https://doi.org/10.4236/aim.2022.128034

Mohammed AK, Zaid NW (2024). Isolation and identification of pathogenic *Streptococcus pyogenes* from vaginal and cervical cavity of Arabian Mares in Al-Zawraa Animals Park. Egypt. J. Vet. Sci., 55(6): 1493-1498. https://doi.org/10.21608/ejvs.2024.259262.1754

Nguyen VL, Le TD, Nuttapon K, Seyed HH, Mohamed SM, Mahmoud SM, Mahmoud AOD, Hien VD (2022). Efficacy of different routes of formalin-killed vaccine administration on immunity and disease resistance of Nile Tilapia (*Oreochromis niloticus*) challenged with *Streptococcus agalactiae*. Fishes, 7(6): 398. https://doi.org/10.3390/fishes7060398

Nikolai S, Rudolf L (2021). *Streptococcus pyogenes* (Group A streptococcus), a highly adapted human pathogen potential implications of its virulence regulation for epidemiology and disease management. Pathogens, 10(6): 776. https://doi.org/10.3390/pathogens10060776

Niluni MW, Song FL, Zhenyu C, Ross D, Rupasinghe HPV

(2021). Carvacrol exhibits rapid bactericidal activity against *Streptococcus pyogenes* through cell membrane damage. Sci. Rep., 11(1): 1487. https://doi.org/10.1038/s41598-020-79713-0

Pandey M, Victoria O, Ainslie C, Emma L, Jessica P, Tania RH, Mei-Fong H, Zachary P, Michael RB, Michael F (2016). Streptococcal immunity is constrained by lack of immunological memory following a single episode of pyoderma. PLoS Pathogens, 12(12): e1006122. https://doi.org/10.1371/journal.ppat.1006122

Patience S, Thomas S, Kirsten M, Bhavya C, Lea AT, Jörn H, Katharina JH, Ole H, Michael N, Mattias S, Per A, Steinar S (2023). Neutrophil-derived reactive agents induce a transient SpeB negative phenotype in *Streptococcus pyogenes*. J. Biomed. Sci., 30(1): 52. https://doi.org/10.1186/s12929-023-00947-x

Paul K, Craig J (2018). Immune responses in the liver. Ann. Rev. Immunol., 36: 247-277. https://doi.org/10.1146/annurev-immunol-051116-052415

Rafeek RA, Lobbe CM, Wilkinson EC, Hamlin AS, Andronicos NM, Millan DJ, Sriprakash KS, Ketheesan N (2021). Group A streptococcal antigen exposed rat model to investigate neurobehavioral and cardiac complications associated with post-streptococcal autoimmune sequelae. Anim. Models Exp. Med., 4(2): 151-161. https://doi.org/10.1002/ame2.12164

Reglinski M, Gierula M, Lynskey NN, Edwards RJ, Sriskandan S (2015). Identification of the *Streptococcus pyogenes* surface antigens recognized by pooled human immunoglobulin. Sci. Rep., 5(1): 15825. https://doi.org/10.1038/srep15825

Roua JM, Ikram AA (2021). Investigating the effect of three antigens of *Citrobacter freundii* on rabbit's immune response. Iraqi J. Vet. Med., 45(1): 56-62. https://doi.org/10.30539/ijvm.v45i1.1043

Sabrin RMI, Alaa S, Basma GE, Shaimaa GAM, Gamal AM (2021). Summary of natural products ameliorate concanavalin a-induced liver injury: Structures, sources, pharmacological effects, and mechanisms of action. Plants (Basel), 10(2): 228. https://doi.org/10.3390/plants10020228

Sadam HM, Manaf AA, Haidar KM (2014). Molecular identification of *Streptococcus equi* subspecies equi in Horses. Iraqi J. Vet. Med., 38(2): 1-8. https://doi.org/10.30539/iraqijvm.v38i2.215

SAS (2018). Statistical analysis system, users guide. Statistical 2018. Version 9, 6th SAS. Inst. Inc. Cary. N.C USA.

Simone B, Marcus F, Nikolai S (2022). Editorial: Streptococci in infectious diseases pathogenic mechanisms and host immune responses. Sci. Infect. Agents Dis., 13: 988671. https://doi.org/10.3389/fmicb.2022.988671

Steven KS, Bancroft CLJD (1997). Theory and practice of histological techniques.

Syed S, Viazmina L, Mager R, Meri S, Haapasalo K (2020). Streptococci and the complement system: interplay during infection, inflammation and autoimmunity. FEBS Letters, 594(16): 2570-2585. https://doi.org/10.1002/1873-3468.13872

Tan, LK, Mark R, Daryl T, Nada R, Lucy EML, Vaitehi N, Claire ET, Mats W, Inga-Maria F, Lars B, Shiranee S (2021). Vaccine-induced, but not natural immunity, against the streptococcal inhibitor of complement protects against invasive disease. NPJ Vaccines, 6(1): 62. https://doi.org/10.1038/s41541-021-00326-3

Toledo AG, Bratanis E, Velásquez E (2023). Pathogen-driven degradation of endogenous and therapeutic antibodies during streptococcal infections. Nat. Commun., 14(1): 6693. https://doi.org/10.1038/s41467-023-42572-0

Ulrich VPR, Johansson BP, Björck L (2002). IdeS a novel streptococcal cysteine proteinase with unique specificity for immunoglobulin. EMBO J., 21(7): 1607-1615. https://doi.org/10.1093/emboj/21.7.1607

Xu ZT, Dong Z, Yongyan C (2006). The differential effects of low dose and high dose concanavalin A on cytokine profile and their importance in liver injury. J. Inflamm. Res., 55(4): 144-152. https://doi.org/10.1007/s00011-006-0064-2

Yang H, Zhang T, Xu K, Lei J, Wang L, Li Z, Zhang Z (2011). A novel and convenient method to immunize animals: Inclusion bodies from recombinant bacteria as antigen to directly immunize animals. Afr. J. Biotechnol., 10(41): 8146-8150. https://doi.org/10.5897/AJB10.2681