



Ameliorative Effects of Monoammonium-Glycyrrhizinate on Liver Lipid Metabolism and Antioxidant Capacity in Laying Hens

Mengke Wang¹, Shucheng Huang², Cai Zhang^{1*}, Haizhou Gong¹, Shunan Cuan¹, Shuaishuai Wang¹, Qi Shao¹, Wenhao Xu¹, Sudan Meng¹, Pengfei Li¹, Yuqin Wang¹ and Zijun Yang¹

¹Laboratory of Environment and Livestock Products, Henan University of Science and Technology, Luoyang 471023, P. R. China.

²College of Animal Science and Veterinary Medicine, Henan Agricultural University, Zhengzhou 450002, P. R. China

Mengke Wang and Shucheng Huang contributed equally to this work.

ABSTRACT

Liver injury is elicited by a complex mechanisms involving free radical-induced oxidative stress, which can cause considerable injury to commercial laying hens. However, the effects of monoammonium-glycyrrhizinate in improving liver lipid metabolism and antioxidant capacity of laying hens is unclear. The current study examined the ameliorative effects of monoammonium-glycyrrhizinate (MAG) on liver lipid metabolism and antioxidant capacity in laying hens. One hundred eighty 320-day-old Hy-Line brown laying hens were allocated to five equal groups and administrated with the concentrations of 0 (control), 25, 50, 100, and 200 mg/L of MAG supplementation in the drinking water, respectively. The histological analysis results by Oil Red O and TUNEL staining showed that lipid deposition and hepatocytes apoptosis in the MAG treated groups were significantly lower than that in the control group. Blood biochemical indexes also revealed that MAG supplementation significantly decreased the activity of alanine aminotransferase (ALT) ($p < 0.05$), the content of total protein (TP), albumin (ALB) and globulin (GLB) ($p < 0.05$). Furthermore, supplementation of MAG increased the activity of total superoxide dismutase (T-SOD) ($p < 0.05$), slightly increased the activities of total antioxidant capacity (T-AOC) ($p > 0.05$) and catalase (CAT) ($p > 0.05$). And the concentrations of malondialdehyde (MDA) were reduced in MAG groups, yet the differences were not significant ($p > 0.05$). Notably, Liver weight, liver index, and triglyceride (TG) content were diminished significantly compared with the control group ($p < 0.05$). These results demonstrated that supplementation of MAG to drinking-water of layers can enhance the antioxidant capacity, improve lipid metabolism and has a protective on liver injury, while no dose dependence was found in this study.

Article Information

Received 12 November 2019

Revised 27 December 2019

Accepted 14 January 2020

Available online 15 October 2021

Authors' Contribution

MW and SH drafted the basic manuscript and analyzed the data. CZ, ZY and SH contributed to conception and design of the research and reviewed the manuscript. MW, HG, SC, SW, QS, WX, SM and PL participated in sample collection and laboratory testing. MW, SH, CZ and ZY participated in the data analysis and revising the manuscript. All authors read and approved the final manuscript.

Key words

Antioxidant capacity, Laying hens, Lipid metabolism, Liver injury, Monoammonium-glycyrrhizinate

INTRODUCTION

Licorice is widely used as a traditional Chinese herb. More than 100 kinds of flavonoids and 60 kinds of triterpenoid saponins, coumarin, alkaloids, and polysaccharide ingredients have been isolated from licorice (Tang *et al.*, 2015). It is noteworthy that triterpene saponins is the main active components which possess hepatoprotective, anti-inflammatory, and even anti-cancer effects (Tang *et al.*, 2015). Glycyrrhizic acid (GA), a triterpenoid saponin, consists of one molecule of glycyrrhetic acid and two molecules of glucuronic acid.

Moreover, glycyrrhizic acid is already highly used in the pharmaceutical industry, food products, beverages, and tobacco industries (Fenwick *et al.*, 1990; Tang *et al.*, 2015; El-Magd *et al.*, 2018).

Glycyrrhizic acid (GA) is known for its pharmacological and biological activities, such as hepatoprotective, anti-inflammatory, anti-virus, anti-cancer, and antiulcer (Asl and Hosseinzadeh, 2008; Tang *et al.*, 2015). GA can also be used to "fight" low blood pressure and repair alcoholic liver damage in rats (Huo *et al.*, 2018). GA is commonly used to treat liver diseases which can inhibit inter-epithelial inflammation and prevent liver fibrosis, hepatic apoptosis and necrosis (Li *et al.*, 2014; Huo *et al.*, 2018). It can reduce steatosis of liver cells significantly (Wang *et al.*, 2016) as well as promote cell regeneration (Kimura *et al.*, 2011). Previously, it

* Corresponding author: zhangcai@haust.edu.cn

0030-9923/2021/0006-2427 \$ 9.00/0

Copyright 2021 Zoological Society of Pakistan

has been reported that inhibition of Mrp2 by GA can achieve liver protection through increase in the content of glutathione (GSH) in liver cells (Xu *et al.*, 2012). In Japan, GA has been used to treat chronic hepatitis for more than 25 years without inducing side effects (Nishimoto *et al.*, 2010). Recent studies demonstrated that GA exhibit favourable hepatoprotective effects by enhancing the anti-inflammatory and antioxidant ability (Huo *et al.*, 2011; Wang and Du, 2016). Liver damage is common in farm animals, especially in bovine and laying hens. Antioxidant could provide a way of protecting the liver from oxidative stress (Chen, 2017). The current study aims to find a specific antioxidant to enhance animal health and animal welfare, hence reducing the economic loss caused by oxidative damage in poultry production.

Although GA preparations are widely used in human clinical and small animal diseases, and have achieved positive results, but there are few studies related to the effects of MAG on the farm animals. The present study evaluates the effects of MAG on liver lipid metabolism and anti-oxidant capacity in laying hens.

MATERIALS AND METHODS

Birds, experimental design and measurements

One hundred and eighty 320-day-old Hy-Line brown laying hens were obtained from local commercial hen farm. After 5 days of acclimatization, the hens were divided into five groups, 3 replicates per group and 12 laying hens per replicate. All hens were fed a basal corn-soybean meal diet (Table I), which were formulated mainly according to NRC (1994). On the sixth day, the treatments were named 0 mg/L group (control group), 25 mg/L group, 50 mg/L group, 100 mg/L group, 200 mg/L group respectively, based on the content of MAG in drinking water. Feed and water were supplied *ad libitum*, with 16 h light per day throughout the experimental period. Meanwhile, at the onset and end of the trial, the weight of each laying hen was recorded using an electronic scale. All experimental procedures were performed in strict accordance with animal ethics and approved by the Committee of Henan University of Science and Technology.

Sample collection

On the 21st day, all birds were weighed following a 12-h fasting. The blood samples were collected into tubes without anticoagulant through brachial wing vein puncture and left to clot at room temperature. The collected blood was slightly tilted at 4°C for 2 h before being centrifuged at 3,000 rpm for 10 min. Separated

serum was stored into 1.5 mL Eppendorf tubes and frozen at -20 °C until further analysis. All the hens were slaughtered according to animal welfare regulations of China. The whole livers were collected, weighed and used for triglyceride estimation and liver histopathology analysis.

Table I. Composition and nutrient content of basal diet.

Item	Content
Ingredient, %	
Soybean meal	23.00
Corn	64.00
Premix ¹	5.00
Stone powder	8.00
Total	100.00
Calculated value	
CP, %	16.18
EE, MJ/kg	10.82
Calcium, %	3.54
Available phosphorus, %	0.43
Lysine, %	0.78
Methionine, %	0.39
Tryptophan, %	0.18
Valine, %	0.65

¹The premix was provided by Henan EGDOO Biological Technology Corporation. Premixes are supplied per kilogram of diet: VA 7500 IU, VD₃ IU, VE 35 mg, VK₃ 1 mg, VB₁ 1.5 mg, VB₂ 4 mg, VB₆ 2mg, VB₁₂ 0.02 mg, Niacin acid 30 mg, folic acid 0.55mg, pantothenic acid 10 mg, biotin 0.16 mg, choline chloride 420 mg, Fe 64 mg, Zn 72 mg, Cu 15 mg, Mn 85mg, I 0.4 mg.

Liver histopathology

All liver tissues were placed in neutral formalin (10%, 4°C, 24 ~ 48h), embedded in paraffin, and sliced into 2-3 sections (5 µm in thickness). Lipid accumulation in the liver was histologically analyzed by using the Oil Red O soluble dye, which dyed neutral lipid (mainly triglycerides) to orange-red tint. Hepatocyte apoptosis was (were) stained with TUNEL staining. After staining, histopathological changes in the liver tissues were observed under an optical microscope (Olympus, Tokyo, Japan) with the magnification of 200.

Hepatic triglyceride

The liver tissue (0.5 g) was homogenized in 4.5ml phosphate buffer (pH 7.4), and then was centrifuged at 3,000 rpm for 10 min. The supernatant was used for estimation of hepatic triglyceride with the help of kit according to the manufacturer's instructions (Nanjing Jiancheng Bioengineering Institute, Nanjing, China).

Table II. Effects of MAG on liver weight and liver index in different experimental groups (n=12) of laying hens.

Item	0 mg/L group	Treatments			
		25 mg/L group	50 mg/L group	100 mg/L group	200 mg/L group
Body weight (g)	2098.00±150.82 ^b	2131.25±116.47 ^b	1962.10±202.37 ^{ab}	2064.44±175.45 ^{ab}	1916.7±160.04 ^a
Liver weight (g)	39.24±6.17 ^a	43.63±3.20 ^b	39.86±6.40 ^b	39.47±6.93 ^{ab}	34.05±3.52 ^{ab}
Liver index ¹ (%)	1.86±0.22 ^a	2.05±0.17 ^b	2.02±0.16 ^b	1.90±0.24 ^{ab}	1.77±0.16 ^{ab}

¹liver index=[liver weight (g)/Body weight (g)]×100. Data are shown as mean±SD, different letters represent statistically different (P < 0.05).

Table III. Effect of MAG on lipid profile, proteins and bilirubin in serum of different experimental groups of laying hens.

Item ¹	0 mg/L group	Treatments			
		25 mg/L group	50 mg/L group	100 mg/L group	200 mg/L group
TP (g/L)	46.13±2.17 ^b	39.63±2.61 ^a	40.83±4.44 ^{ab}	39.75±4.20 ^a	36.58±3.15 ^a
ALB (g/L)	16.70±0.78 ^b	14.93±1.16 ^{ab}	14.75±1.68 ^{ab}	15.10±2.06 ^{ab}	13.93±1.23 ^a
GLB (g/L)	29.43±1.45 ^b	24.73±1.89 ^a	26.08±2.83 ^{ab}	24.65±2.19 ^a	22.65±2.15 ^a
A/G	0.57±0.01	0.61±0.06	0.57±0.02	0.61±0.03	0.62±0.04
GLU (mmol/L)	11.67±0.20	11.14±0.75	11.24±1.29	11.01±1.53	11.19±1.54
CHOL (mmol/L)	2.27±0.76	1.85±0.25	1.84±0.62	1.69±0.31	1.60±0.29
HDLC (mmol/L)	1.10±0.20	0.88±0.16	1.00±0.09	1.04±0.14	1.01±0.09
LDLC (mmol/L)	0.81±0.21	0.77±0.05	0.80±0.14	0.84±0.19	0.77±0.17
TBIL (μmol/L)	1.80±0.40	1.58±0.33	1.50±0.30	1.70±0.10	1.45±0.17
DBIL (μmol/L)	0.77±0.21	0.83±0.31	0.60±0.30	0.70±0.44	0.38±0.26
IBIL (μmol/L)	1.03±0.40	0.75±0.06	0.90±0.00	1.00±0.35	1.08±0.41

¹Data are shown as mean±SD. Different letters represent statistically significant differences (P < 0.05). TP, total protein; ALB, albumin; GLB, globulin; A/G, albumin/globulin; GLU, glucose; CHOL, cholesterol; HDLC, high-density lipoprotein; LDLC, low-density lipoprotein; TBIL, total bilirubin; DBIL, direct bilirubin; IBIL, indirect bilirubin.

Measurement Blood biochemical parameters

The serum aspartate transaminase (AST), alanine aminotransferase (ALT), alkaline phosphatase (ALP), total protein (TP), albumin (ALB), globulin (GLB), total bilirubin (TBIL), direct bilirubin (DBIL), indirect bilirubin (IBIL), glucose (GLU), triglycerides (TG), cholesterol (CHOL), high-density lipoprotein (HDL-C) and low-density lipoprotein (LDL-C) concentrations were assayed by blood biochemical analyzer (Sysmex XE-2100, Biochemical Analyzer Medical System, Japan).

Determination of antioxidant activity in serum

Lipid peroxidation degradation products were determined by the thiobarbituric acid method (Arukwe *et al.*, 2016), which measures malondialdehyde (MDA) and expressed as nmol/mL and lipid peroxidation product of lipid breakdown caused by oxidative stress using colorimetric diagnostic kit (A003-1; Nanjing Jiancheng Bioengineering Institute, Nanjing, China).

Total antioxidant capacity (T-AOC), catalase (CAT), total superoxide dismutase (T-SOD) and TG in serum were measured by using some commercial kits (Nanjing Jiancheng Bioengineering Institute, Nanjing, China). All these indices were determined with Microplate Reader (Thermo Fisher Scientific, Shanghai, China).

Statistical analysis

All detected data were analyzed by SPSS statistics software (Version 17.0, SPSS Inc, Chicago, IL, USA), and were presented as the means ± standard deviations (SD). Comparative analysis of the different groups was made using one-way analysis of variance (ANOVA) followed by Fisher's least significant difference (LSD) Duncan test. P<0.05 was considered to be statistically significant. All results were repeated at least three times and representative histopathological results were shown.

RESULTS

MAG supplementation decreased liver weight and liver index

As shown in Table II, the liver wet weight and liver indices of all the experimental treatments were higher than the control group except for the 200 mg/L MAG group. Especially in the 25, 100 mg/L MAG groups liver weights and liver indices of laying hens were markedly higher than the control group ($P < 0.05$).

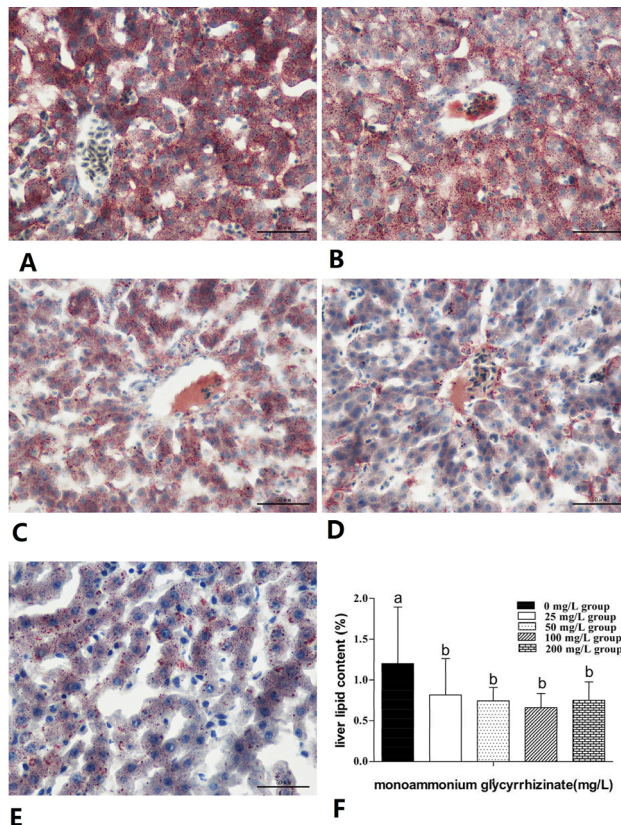


Fig. 1. Histological analysis of the livers and hepatic lipids. Lipid accumulation in the liver was checked by using the Oil Red O soluble dye that stains neutral lipid (mainly triglycerides) with an orange-red tint. **A)** The control group; **B)** 25 mg/L MAG group; **C)** 50 mg/L MAG group; **D)** 100 mg/L MAG group; **E)** 200 mg/L MAG group; Scale bar=100 μ m. **F)** liver lipid content. Data represent means \pm SD, one-way ANOVA, and different letters represent statistically significant differences ($P < 0.05$).

MAG supplementation inhibited lipid deposition and apoptotic hepatocytes production

As shown in Figure 1, Oil Red O-stained lipid droplet was observed and the degree of steatosis in the MAG group showed a clear reduction compared with the control group.

Moreover, the liver lipid content of laying hens was also obviously reduced compared to the control group ($P < 0.05$) (Fig. 1F). In comparison with the control, TUNEL-positive apoptotic hepatocytes in the MAG group were found to be decreased significantly (Fig. 2A-2E).

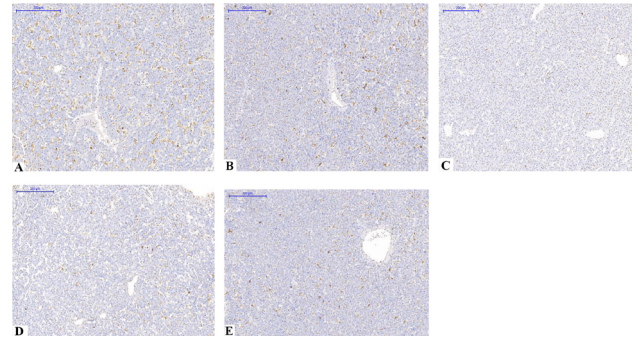


Fig. 2. Observation of hepatocyte apoptosis by TUNEL staining. Cells with nuclei that stained dark brown were considered to be TUNEL positive. **A)** The control group; **B)** 25 mg/L MAG group; **C)** 50 mg/L MAG group; **D)** 100 mg/L MAG group; **E)** 200 mg/L MAG group. In the MAG groups, decreased apoptotic cell number was seen compared to the control group. Scale bar=200 μ m.

MAG supplementation ameliorated serum biochemical parameters

In Table III, the levels of TP, ALB, and GLB in the MAG groups were decreased compared to the control group. Moreover, the ALB content in 200 mg/L group and the TP and GLB content in 25 mg/L group, 100 mg/L group and 200 mg/L group decreased significantly ($P < 0.05$), but no significant changes were observed in serum ALB/GLB ratio, and GLU, HDLC, LDLC, TBIL, DBIL, IBIL levels during the experiment (Table III). In addition, the activity of ALT was significantly decreased in 25 and 200 mg/L groups ($P < 0.05$) (Fig. 3A). In comparison with the control, the activities of AST and ALP were not effected in the MAG group ($P > 0.05$).

MAG supplementation decreased malondialdehyde concentration and enhanced antioxidant enzymes activity in serum

The T-AOC and CAT concentrations were higher in the MAG groups than in the control group (Fig. 3D and 3G). The MDA concentrations decreased slightly in Figure 3F ($P > 0.05$), which indicated no obvious change in the concentrations of T-AOC, CAT, and MDA through MAG supplementation. However, the serum oxidative stress index T-SOD showed a significant increase in 25, 50 and 100 mg/L groups, ($P < 0.05$) (Fig. 3E).

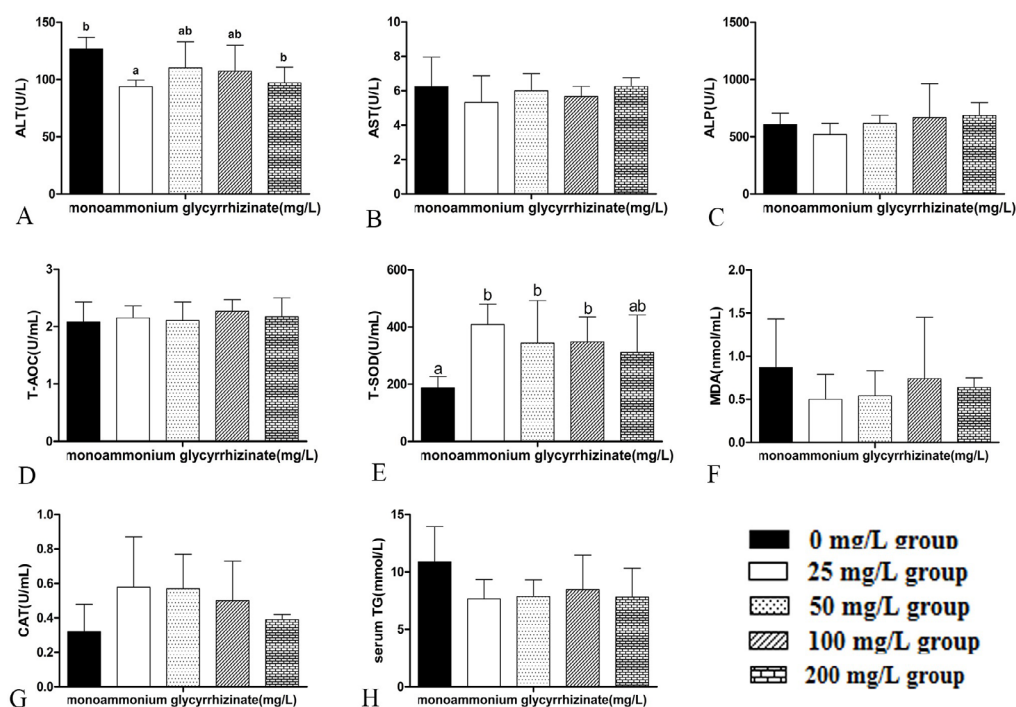


Fig. 3. Effect of different levels of MAG in serum parameters of laying hens. Data represent means \pm SD, one-way ANOVA, and different letters represent statistically significant differences ($P < 0.05$). ALT, alanine aminotransferase; AST, aspartate transaminase; ALP, alkaline phosphatase; T-AOC, total antioxidant capacity; T-SOD, total-superoxide dismutase; MDA, malondialdehyde; CAT, malondialdehyde; TG, serum triglycerides.

DISCUSSION

In this study, the results showed that liver weight, liver index, and liver lipid content significantly decreased compared with the control group. The levels of TP, ALB, and GLB decreased compared with the control group, but no significant difference was observed in A/G ratio. However, lipid parameters in MAG-treated groups were improved partly in serum samples. Compared with control group, TG and CHOL content in serum was decreased, but the difference was not significant. These findings were consistent with another study which found that obese rats with oral glycyrrhetinic acid 100 μ g/g for 28 d, triglyceride, blood glucose, and total cholesterol in serum were decreased (Eu *et al.*, 2010). It has also been reported by Chandramuli *et al.* (2011) that in high sucrose-fed rat after oral administration of glycyrrhetinic acid at 100 μ g/g for 28 d, blood glucose was significantly reduced and blood lipids improved. In this study, by adding different levels of MAG in the drinking water of the laying hens, GLU was decreased and the blood lipid was improved, which was consistent with the previous research results. Moreover, the degree of liver steatosis in the MAG supplement group was significantly reduced, consistent with the results

of liver triglyceride content. Lipid deposition decreases significantly in quadriceps femoris and abdominal muscle after oral 50 mg/kg of GA for one week in rats (Lim *et al.*, 2009). The result indicated that MAG can reduce liver fat deposition by reducing liver TG levels, but blood lipids are not decreased significantly.

The number of TUNEL-stained apoptotic cells in liver was decreased significantly compared with the control group, which indicated MAG supplement with drinking water of laying hens can protect the liver by reducing oxidative stress and cell apoptosis effectively. Upon clinical examination and experimental studies, the increase of ALT and AST levels in serum is recognized as biochemical markers of hepatocellular injury (Scheig, 1996; ArAgon and Younossi, 2010). After hepatocellular damage, these enzymes are released into the bloodstream (Ramaiah, 2007). Previous studies reported that licorice can protect the rats effectively from CCl₄-induced hepatic injury by decreased serum AST, ALT, and ALP activities (Nose *et al.*, 1994; Gumprecht *et al.*, 2005; Huo *et al.*, 2011). Pre-treatment with 18 β -glycyrrhetinic acid can decrease the activity of ALT and AST in serum and suppress hepatic lipid peroxidation caused by CCl₄ (Jeong *et al.*, 2002). Kim *et al.* (2006) reported that

liquiritigenin pretreatment with acetaminophen-induced rats can improve liver necrosis and reduce ALT activity. Moreover, 18-glycyrrhetic acid (50 mg/kg) protects the liver tissue by reducing serum AST, ALT and ALP activity significantly to maintain the liver's structural integrity and less histopathological change. Liquiritigenin and 18-glycyrrhetic acid belong to flavonoid and triterpene groups, respectively. In addition, low-dose glycyrrhetic acid in triptolide rats significantly increased SOD/CAT activity but strengthened the liver defense system for antioxidant (Yang *et al.*, 2017). Study also pointed out that the liver injury was positively correlated with ketoacidosis and the activity of AST and ALT. Ketosis cows usually show higher serum LDH content compared to normal cows (Du *et al.*, 2017). Similarly, Gumprecht *et al.* (2005) indicated that glycyrrhetic acid can inhibit hepatocyte apoptosis in rat by glycochenodeoxycholic acid-induced cytotoxicity. These results suggest that MAG supplement can suppress the activity of higher liver enzymes, thereby reducing liver damage.

Under normal circumstances, there is a stable dynamic balance between the oxidation system and the antioxidant system of the animal's body. Once this balance is broken, it will lead to oxidative stress (Reuter *et al.*, 2010). Many studies have found that oxidative stress plays a crucial function in liver damage such as fatty liver, liver fibrosis, viral hepatitis (Cederbaum *et al.*, 2009; Tolooei and Mirzaei 2015). Although low concentrations of reactive oxygen species (ROS) are involved in cell proliferation as intracellular messengers, a large number of ROS has direct effects on different types of cell death, including apoptosis and necrosis (Zhang *et al.*, 2015; Su *et al.*, 2016). Furthermore, ROS is not cleared in time or is overproduced, which also causes oxidative stress to occur. (Yu *et al.*, 2015). A study in rat heart mitochondria showed that glycyrrhetic acid depending on its concentration, is able to prevent or to induce oxidative stress, thereby affecting ROS production (Battaglia *et al.*, 2008). T-SOD is a vital antioxidant enzyme in organisms and is the primary material in vivo free radical scavenging. T-AOC can reflect the status of all antioxidants in body fluids and which is contributes to the balance of active oxygen (Ghiselli *et al.*, 2000; Rajani *et al.*, 2011). T-SOD and CAT play an important role in protecting cells from damage caused by ROS (Miao *et al.*, 2017). Serum MDA is a soluble lipid degradation end-product (Lorente *et al.*, 2015), and MDA contents can be used to monitor the extent of lipid peroxidation (Dragun *et al.*, 2017). Licorice extract against carbon tetrachloride can markedly suppressed the elevated concentrations of MDA and increased levels of SOD in comon carp (Yin *et al.*, 2011). Data of the present study suggest that MGA had a consistent and significant effect

in decreasing serum MDA content versus control. The serum SOD content was increased significantly after using MAG supplementation, resulting in a reduced superoxide anion concentration in laying hens. We speculate that MAG strengthen the oxidative defenses through increased T-SOD contents and decreased MDA content in serum.

CONCLUSION

According to the results of this study, supplementation of MAG through drinking-water in chickens can enhance the antioxidant capacity, improve lipid metabolism and have a curative effect on liver injury.

ACKNOWLEDGMENTS

The study was financially supported by the National Key RandD Program of China (2017YFE0129900), the National Natural Science Foundation of China (31402263, 31872537) and Science Foundation of Henan province (182300410087).

Statement of conflict of interest

The authors declared no conflicts of interest.

REFERENCES

- ArAGon, G. and Younossi, Z.M., 2010. When and how to evaluate mildly elevated liver enzymes in apparently healthy patients. *Cleve. Clin. J. Med.*, **77**: 195-204. <https://doi.org/10.3949/ccjm.77a.09064>
- Arukwe, A., Carteny, C.C. and Eggen, T., 2016. Lipid peroxidation and oxidative stress responses in juvenile salmon exposed to waterborne levels of the organophosphate compounds tris (2-butoxyethyl)- and tris (2-chloroethyl) phosphates. *J. Toxicol. environ. Hlth. A*, **79**: 515-525. <https://doi.org/10.1080/15287394.2016.1171978>
- Asl, M.N. and Hosseinzadeh, H., 2008. Review of pharmacological effects of *Glycyrrhiza* sp. and its bioactive compounds. *Phytother. Res.*, **22**: 709-724. <https://doi.org/10.1002/ptr.2362>
- Battaglia, V., Brunati, A.M., Fiore, C., Rossi, C.A., Salvi, M., Tibaldi, E., Palermo, M., Armanini, D. and Toninello, A., 2008. Glycyrrhetic acid as inhibitor or amplifier of permeability transition in rat heart mitochondria. *Biochim. biophys. Acta*, **1778**: 313-323. <https://doi.org/10.1016/j.bbame.2007.10.008>
- Cederbaum, A.I., Lu, Y. and Wu, D., 2009. Role of oxidative stress in alcohol-induced liver injury. *Arch. Toxicol.*, **83**: 519-548. <https://doi.org/10.1007/>

- s00204-009-0432-0
- Chandramouli, C., Ting, Y.S., Lyn, L.Y., Ha, T.S. and Kadir, K.A., 2011. Glycyrrhizic acid improves lipid and glucose metabolism in high-sucrose-fed rats. *J. Endocrinol. Metab.*, **1**:125-141. <https://doi.org/10.4021/jem39w>
- Chen, X. R., Liu, Z. J., Meng, R. Z., Shi, C., and Guo, N. 2017. Antioxidative and anticancer properties of Licochalcone A from licorice. *J. Ethnopharmacol.*, **198**: 331-337. <https://doi.org/10.1016/j.jep.2017.01.028>
- Dragun, Z., Marijić, V.F., Krasnići, N., Ramani, S., Valić, D., Rebok, K., Kostov, V., Jordanova, M. and Erk, M., 2017. Malondialdehyde concentrations in the intestine and gills of Vardar chub (*Squalius vardarensis* Karaman) as indicator of lipid peroxidation. *Environ. Sci. Pollut. Res. Int.*, **24**: 16917-16926. <https://doi.org/10.1007/s11356-017-9305-x>
- Du, X., Shi, Z., Peng, Z., Zhao, C., Zhang, Y., Wang, Z., Li, X., Liu, G. and Li, X., 2017. Acetoacetate induces hepatocytes apoptosis by the ROS-mediated MAPKs pathway in ketotic cows. *J. cell. Physiol.*, **232**: 3296-3308. <https://doi.org/10.1002/jcp.25773>
- El-Maghd, N.F.A., El-Mesery, M., El-Karef, A. and El-Shishtawy, M.M., 2018. Glycyrrhizin ameliorates high fat diet-induced obesity in rats by activating NrF2 pathway. *Life Sci.*, **193**: 59-170. <https://doi.org/10.1016/j.lfs.2017.11.005>
- Eu, C.H.A., Lim, W.Y.A., Ton, S.H. and bin Abdul Kadir, K., 2010. Glycyrrhizic acid improved lipoprotein lipase expression, insulin sensitivity, serum lipid and lipid deposition in high-fat diet-induced obese rats. *Lipids Hlth. Dis.*, **9**: 81. <https://doi.org/10.1186/1476-511X-9-81>
- Fenwick, G.R., Lutomski, J. and Nieman, C., 1990. Liquorice, *Glycyrrhiza glabra* L.-composition, uses and analysis. *Fd. Chem.*, **38**: 119-143. [https://doi.org/10.1016/0308-8146\(90\)90159-2](https://doi.org/10.1016/0308-8146(90)90159-2)
- Ghiselli, A., Serafini, M., Natella, F. and Scaccini, C., 2000. Total antioxidant capacity as a tool to assess redox status: critical view and experimental data. *Free Radic. Biol. Med.*, **29**: 1106-1114. [https://doi.org/10.1016/S0891-5849\(00\)00394-4](https://doi.org/10.1016/S0891-5849(00)00394-4)
- Gumprich, E., Dahl, R., Devereaux, M.W. and Sokol, R.J., 2005. Licorice compounds glycyrrhizin and 18 β -glycyrrhetinic acid are potent modulators of bile acid-induced cytotoxicity in rat hepatocytes. *J. Biol. Chem.*, **280**: 10556-10563. <https://doi.org/10.1074/jbc.M411673200>
- Huo, H.Z., Wang, B., Liang, Y.K., Bao, Y.Y., and Gu, Y., 2011. Hepatoprotective and antioxidant effects of licorice extract against CCl₄-induced oxidative damage in rats. *Int. J. Mol. Sci.*, **12**: 6529-6543. <https://doi.org/10.3390/ijms12106529>
- Huo, X., Yang, S., Sun, X., Meng, X. and Zhao, Y., 2018. Protective effect of glycyrrhizic acid on alcoholic liver injury in rats by modulating lipid metabolism. *Molecules*, **23**: 1623. <https://doi.org/10.3390/molecules23071623>
- Jeong, H.G., You, H.J., Park, S.J., Moon, A.R., Chung, Y.C., Kang, S.K. and Chun, H.K., 2002. Hepatoprotective effects of 18 β -glycyrrhetinic acid on carbon tetrachloride-induced liver injury: inhibition of cytochrome P450 2E1 expression. *Pharmacol. Res.*, **46**: 221-227. [https://doi.org/10.1016/S1043-6618\(02\)00121-4](https://doi.org/10.1016/S1043-6618(02)00121-4)
- Kim, Y.W., Ki, S.H., Lee, J.R., Lee, S.J., Kim, C.W., Kim, S.C. and Kim, S.G., 2006. Liquiritigenin, an aglycone of liquiritin in *Glycyrrhizae radix*, prevents acute liver injuries in rats induced by acetaminophen with or without buthionine sulfoximine. *Chem. Biol. Interact.*, **161**: 125-138. <https://doi.org/10.1016/j.cbi.2006.03.008>
- Kimura, M., Inoue, H., Hirabayashi, K., Natsume, H. and Ogihara, M., 2001. Glycyrrhizin and some analogues induce growth of primary cultured adult rat hepatocytes via epidermal growth factor receptors. *Eur. J. Pharmacol.*, **431**: 151-161. [https://doi.org/10.1016/S0014-2999\(01\)01424-8](https://doi.org/10.1016/S0014-2999(01)01424-8)
- Li, J.Y., Cao, H.Y., Liu, P., Cheng, G.H. and Sun, M.Y., 2014. Glycyrrhizic acid in the treatment of liver diseases: literature review. *BioMed. Res. Int.*, **2014**: 872139. <https://doi.org/10.1155/2014/872139>
- Lim, W.Y.A., Chia, Y.Y., Liong, S.Y., Ton, S.H., Kadir, K.A. and Husain, S.N., 2009. Lipoprotein lipase expression, serum lipid and tissue lipid deposition in orally-administered glycyrrhizic acid-treated rats. *Lipids Hlth. Dis.*, **8**: 31. <https://doi.org/10.1186/1476-511X-8-31>
- Lorente, L., Martín, M.M., Abreu-González, P., Ramos, L., Argueso, M., Solé-Violán, J., Riano-Ruiz, M. and Jiménez, A., 2015. Serum malondialdehyde levels in patients with malignant middle cerebral artery infarction are associated with mortality. *PLoS One*, **10**: e0125893. <https://doi.org/10.1371/journal.pone.0125893>
- Miao, L.P., Zhou, M.Y., Zhang, X.Y., Yuan, C., Dong X.Y. and Zou, X.T., 2017. Effect of excess dietary fluoride on laying performance and antioxidant capacity of laying hens. *Poult. Sci.*, **96**: 2200-2205. <https://doi.org/10.3382/ps/pex002>
- National Research Council, 1994. *Nutrient requirements*

- of poultry*. 9th rev. ed. National Academy Press, Washington, DC.
- Nishimoto, Y., Hisatsune, A., Katsuki, H., Miyata, T., Yokomizo, K. and Isohama, Y., 2010. Glycyrrhizin attenuates mucus production by inhibition of MUC5AC mRNA expression in vivo and in vitro. *J. pharmacol. Sci.*, **113**: 76-83. <https://doi.org/10.1254/jphs.09344FP>
- Nose, M., Ito, M., Kamimura, K., Shimizu, M. and Ogihara, Y., 1994. A comparison of the antihepatotoxic activity between glycyrrhizin and glycyrrhetic acid. *Planta Med.*, **60**: 136-139. <https://doi.org/10.1055/s-2006-959435>
- Quinlan, G.J., Martin, G.S. and Evans, T.W., 2005. Albumin: biochemical properties and therapeutic potential. *Hepatology*, **41**: 1211-1219. <https://doi.org/10.1002/hep.20720>
- Rajani, J., Torshizi, M.K., and Rahimi, S., 2011. Control of ascites mortality and improved performance and meat shelf-life in broilers using feed adjuncts with presumed antioxidant activity. *Anim. Feed Sci. Technol.*, **170**: 239-245. <https://doi.org/10.1016/j.anifeedsci.2011.09.001>
- Ramaiah, S.K., 2007. A toxicologist guide to the diagnostic interpretation of hepatic biochemical parameters. *Fd. Chem. Toxicol.*, **45**: 1551-1557. <https://doi.org/10.1016/j.fct.2007.06.007>
- Reuter, S., Gupta, S.C., Chaturvedi, M.M. and Aggarwal, B.B., 2010. Oxidative stress, inflammation, and cancer: how are they linked? *Free Radic. Biol. Med.*, **49**: 1603-1616. <https://doi.org/10.1016/j.freeradbiomed.2010.09.006>
- Scheig, R., 1996. Evaluation of tests used to screen patients with liver disorders. *Prim. Care*, **23**: 551-560. [https://doi.org/10.1016/S0095-4543\(05\)70347-X](https://doi.org/10.1016/S0095-4543(05)70347-X)
- Su, K., Wang, C.F., Zhang, Y., Cai, Y.J., Zhang, Y.Y. and Zhao, Q., 2016. The inhibitory effects of carnosic acid on cervical cancer cells growth by promoting apoptosis via ROS-regulated signaling pathway. *Biomed. Pharmacother.* **82**: 180-191. <https://doi.org/10.1016/j.biopha.2016.04.056>
- Tang, Z.H., Li, T., Tong, Y.G., Chen, X.J., Chen, X.P., Wang, Y.T. and Lu, J.J., 2015. A systematic review of the anticancer properties of compounds isolated from licorice (gancao). *Planta Med.*, **81**: 1670-1687. <https://doi.org/10.1055/s-0035-1558227>
- Tolooei, M. and Mirzaei, A., 2015. Effects of *Pistacia atlantica* extract on erythrocyte membrane rigidity, oxidative stress, and hepatotoxicity induced by CCl₄ in rats. *Glob. J. Hlth. Sci.*, **7**: 32-38. <https://doi.org/10.5539/gjhs.v7n7p32>
- Wang, C., Duan, X., Sun, X., Liu, Z., Sun, P., Yang, X., Sun, H., Liu, K. and Meng, Q., 2016. Protective effects of glycyrrhizic acid from edible botanical glycyrrhiza glabra against non-alcoholic steatohepatitis in mice. *Fd. funct.*, **7**: 3716-3723. <https://doi.org/10.1039/C6FO00773B>
- Wang, J.Q., Zhou, W.C., Song, J.B., Sone, Q., Zhang, X.Q., and Jiang, Z.R., 2001. Purification of monoammonium glycyrrhizinate. *J. Chem. Indust. Forest Prod.*, **01**: 8-13.
- Wang, Y.M. and Du, G.Q., 2016. Glycyrrhizic acid prevents enteritis through reduction of NF- κ B p65 and p38MAPK expression in rat. *Mol. Med. Rep.*, **13**: 3639-3646. <https://doi.org/10.3892/mmr.2016.4981>
- Xu, R., Zhang, X., Yang, J., Liu, X., Davey, A.K., and Wang, J., 2012. Effects of glycyrrhizin on biliary transport and hepatic levels of glutathione in rats. *Biopharm. Drug Dispos.*, **33**: 235-245. <https://doi.org/10.1002/bdd.1789>
- Yang, G., Wang, L., Yu, X., Huang, Y., Qu, C., Zhang, Z., Luo, D., Lin, J., Zhou, L., Su, Z., Zhang, X. and Chen, H., 2017. Protective effect of 18 β -glycyrrhetic acid against triptolide-induced hepatotoxicity in rats. *Evid. Based Compl. Alternat. Med.*, **2017**: 3470320. <https://doi.org/10.1155/2017/3470320>
- Yang, R., Li, W., Yuan, B., Ren, G. and Liu, Y., 2018. The genetic and chemical diversity in three original plants of licorice, glycyrrhiza uralensis fisch. glycyrrhiza inflata bat. and glycyrrhiza glabra l. *Pak. J. pharm. Sci.*, **31**: 525-535.
- Yin, G., Cao, L., Xu, P., Jeney, G., Nakao, M. and Lu, C., 2011. Hepatoprotective and antioxidant effects of Glycyrrhiza glabra extract against carbon tetrachloride (CCl₄)-induced hepatocyte damage in common carp (Cyprinus carpio). *Fish Physiol. Biochem.*, **37**: 209-216. <https://doi.org/10.1007/s10695-010-9436-1>
- Yu, J., Chen, Y., Zhai, L., Zhang, L., Xu, Y., Wang, S. and Hu, S., 2015. Antioxidative effect of ginseng stem-leaf saponins on oxidative stress induced by cyclophosphamide in chickens. *Poult. Sci.*, **94**: 927-933. <https://doi.org/10.3382/ps/pev055>
- Zhang, M., Harashima, N., Moritani, T., Huang, W. and Harada, M., 2015. The roles of ROS and caspases in TRAIL-induced apoptosis and necroptosis in human pancreatic cancer cells. *PLoS One*, **10**: e0127386. <https://doi.org/10.1371/journal.pone.0127386>