



Short Communication

Assessment of Three Dimensional Color Power Doppler Technique for Detecting Fetal Renal Vascular Perfusion in Pregnant Women with Gestational Hypertension

Hong Liu and Rui Xu*

Obstetrics and Gynecology Department, The Third People's Hospital of Lixia District of Jinan City, Jinan, 2500000, China

ABSTRACT

The main objective was to investigate the application value of three-dimensional color power angiography (3D-CPA) in detecting fetal renal blood perfusion in pregnant women with gestational hypertension. One-hundred single-fetal pregnant women diagnosed with gestational hypertension in our hospital from June 2017 to December 2019 were enrolled in the study. They were divided into mild prehypertension group (50 cases) and severe prehypertension group (50 cases). Another 50 cases of normal single-fetal pregnant women were selected as the control group. Within three months, all single-pregnant women received the measurement of the 3D-CPA vascularization index (VI) and flow index (FI) of the fetal kidney and the vascularization flow index (VFI) in the early pregnancy. In addition, blood flow parameters of the uterine artery and fetal umbilical artery of the pregnant woman were correlated at the 12th week and the 22nd week. We found that FI, VI and VFI decreased in the mild and severe prehypertension groups were compared with the control group ($P < 0.05$). There was a certain correlation of blood flow parameters of pregnant women's uterine artery and fetal umbilical artery with fetal kidney VI and FI which decreased in women with 12 and 22 weeks of pregnancy. Among all the measured parameters, fetal kidney FI showed the best sensitivity for the detection of fetal kidneys in patients with pregnancy-induced hypertension. It is concluded that 3D-CPA ultrasonography could be used to quantitatively analyze fetal kidneys with gestational hypertension in pregnancy, providing a quantitative basis for prenatal diagnosis of fetal renal blood perfusion in patients with gestational hypertension. It could also be used to detect risk pregnancy in early pregnancy.

Article Information

Received 29 October 2020

Revised 15 November 2020

Accepted 31 December 2020

Available online 20 May 2021

Authors' Contribution

HL and RX collected the samples. HL analysed the data. RX conducted the experiments and analysed the results. All authors discussed the results and wrote the manuscript.

Key words

3D-CPA Doppler ultrasonography, Gestational hypertension, Fetal kidney, Blood perfusion

The factors of fetal development problems caused by pregnancy-related problems such as preeclampsia and pregnancy-induced hypertension are diverse and unpredictable. However, from a clinical point of view, it seems that there is a potential basis, that is, abnormally low blood flow of fetal kidney (Tang, 2019). A clinical case supporting this hypothesis is the increase of fetal renal artery blood flow impedance measured by 2D Doppler ultrasonography in the second trimester of pregnancy. Studies have shown that there is a strong correlation between the decrease of fetal kidney blood flow caused by damaged trophoblast infiltration and pregnancy induced hypertension in pregnant women (Sha *et al.*, 2019). A possible method to evaluate trophoblast invasion in early pregnancy (i.e., when it actually occurs) may be to measure the vascularization and perfusion of fetal kidney. 3D-CPA Doppler ultrasonography is a method that allows observation of the number and flow of blood vessels in small tissues. It has been pointed out that it may be superior to spectral Doppler in low-speed blood flow. 3D method can provide this information for the whole fetal kidney. Most of the

previous studies on this particular aspect (Ma *et al.*, 2018; Li *et al.*, 2018) were carried out relatively late during pregnancy. This paper provides the routine 3D-CPA Doppler ultrasonography data of the whole fetal kidney completed between 11 and 14 weeks of pregnancy. To explore the value of 3D-CPA Doppler ultrasonography and its quantitative parameters in monitoring fetal renal blood perfusion in patients with gestational hypertension. By comparing these data, we aimed to determine whether these indicators could be used to evaluate fetal renal blood perfusion and provide quantitative basis for prenatal diagnosis of fetal renal blood perfusion in patients with gestational hypertension.

Materials and methods

A total of 100 single-fetal pregnant women who made an appointment to give birth in the Third People's Hospital of Lixia District of Jinan City from June 2017 to December 2019 were selected as research objects, and were divided into mild pre-eclampsia group (n=50) and severe pre-eclampsia group (n=50). Fifty healthy single-fetal pregnant women in the same period were selected as control group. There was no significant difference in pregnancy times, parity and age between the control group and the two experimental groups ($P > 0.05$). The

* Corresponding author: xurui0739@126.com
0030-9923/2021/0001-0001 \$ 9.00/0
Copyright 2021 Zoological Society of Pakistan

experiment was conducted with the subjects' consent. Inclusion criteria: patients who need general anesthesia for elective surgery; single-fetal pregnant women who make an appointment to give birth in our hospital, aged between 20 and 45, diagnosed as gestational hypertension, No previous history of general anesthesia. Exclusion criteria: chronic heart, liver and kidney insufficiency, suffering from neurological and mental system diseases before operation, severe endocrine and metabolic diseases, patients with chronic obstructive pulmonary disease, those with a score of simple mental state examination scale less than 24 points and those with a history of drug addiction.

In this study, all women who had a single-fetal pregnancy in early pregnancy were prospectively registered within three months. In addition to the conventional procedures mentioned above, the power Doppler vascularization index (VI) and flow index (FI) were also measured. To measure these indexes in the fetal kidney, the power Doppler color box was placed on the whole fetal kidney (Ju *et al.*, 2018). Doppler value was normalized at mass normal. The pulse repetition rate was 0.9 KHz. Wall motion filter low1 was used. The angle of gray image is 70°, with zoom of 1.6 and focus area of 1. The X-ray beams, CRI1, SRI3 and OTI, were normal, and harmonic frequency was high. Then, the volume box with the same size was placed on the same position as the color box. The process was recorded by using the maximum quality preset and finally stored.

All women were recorded at the same speed (10 seconds). All measurements were carried out by Voluson 730 Expert (General Electric Company Fairfield Connecticut USA). If artifacts occurred during volume recording, the recording process was repeated until sufficient volume quality could be achieved. All measurements were performed by only one operator (EH) to avoid differences between observers (Zhang, 2018). The above indices were measured in fetal kidney, respectively.

For calculation of indices, the fetal kidney was rotated horizontally in the A plane and the B plane. "VOXEL" was used. It is a built-in program for volume measurement. The fetal kidney boundary was carefully tracked in plane A by caliper, and the region of interest (ROI) was defined at the same time. Then, the fetal kidney was rotated by 30° in the horizontal plane and the fetal kidney boundary was tracked repeatedly. The angle of horizontal rotation was set in advance. At an angle of 30°, it took six cuts to completely define the fetal kidney boundary. After that, the machine automatically calculated VI and FI (as shown in Supplementary Fig. 1).

In order to determine whether the index varies by the fetal kidney position, these data (anterior or posterior fetal kidney attachment) were collected from 75 women, and the correlation was calculated. The 3D-CPA volume data

of fetal kidney of each subject was measured separately (as shown in Supplementary Fig. 2), and the same operation was carried out on each subject.

Women were required to return for abnormal fetal scanning at the 22nd gestational week. At this stage, the uterine artery and fetal umbilical artery were measured. For this purpose, they were recorded for at least five pulse Doppler cycles by color flow imaging.

According to 1.2.2, the blood perfusion of fetal kidney was investigated, and the blood flow was graded according to the method of Ma *et al.* (2018). The grading standard of blood flow distribution is shown in Table I.

All the data in this study were processed by SPSS 20.0 statistical analysis software (IBM Company); the measurement data was expressed by "mean±standard deviation" and the comparison between groups was made by one-way ANOVA. The pairwise comparison between groups was made by LSD-t test, and the comparison among multiple groups was made by one-way ANOVA; logistic regression was used to calculate the regression equation to analyze the relationship between the parameters of fetal kidney blood flow and uterine artery, fetal umbilical artery and gestational weeks, and χ^2 analysis was used for comparison between groups; $P < 0.05$ indicated statistically significant difference.

Table I. Grading standard of blood flow distribution in blood perfusion.

Grade	Renal blood flow imaging	Intrarenal arcuate artery	Intrarenal interlobar artery
Grade I	Rich	Clear	Clear
Grade II	Relatively rich	Peripheral defect	End vanishing
Grade III	Worse	Partial defect	Spotty distribution
Grade IV	Poor	Dispersed distribution	Disappearing

Results and discussion

Table II shows the general data of three groups of pregnant women, whereas Table III shows the grading of blood perfusion of fetal kidney by Doppler detection among three groups of pregnant women. Table IV shows comparison of vascular indices among the three groups of pregnant women. In this study, the fetal renal vascularization and blood flow in 150 cases of single-fetal pregnancy were measured. Six cases had to be excluded due to fetal aneuploidy or deformity, and two cases had abortions within 12 to 22 weeks. For unexplained reasons, 12 cases failed to show up at the scheduled fetal abnormality scan or were unable to ensure tracking of pregnancy outcomes. A total of 130 cases were evaluated.

There was significant difference in VI between severe pre-hypertension group and control group and significant

Table II. General data of three groups of pregnant women.

Group	Case (n)	Age (year)	Gestational weeks (week)	Pregnancy times	
				Primipara	Multipara
Control group	50	28.32±6.24	15.26±4.02	32/50	18/50
Mild pre-eclampsia group	50	30.89±3.71	16.18±4.33	27/50	23/50
Severe pre-hypertension group	50	31.12±4.30	16.58±5.42	21/50	29/50
F/ χ^2	-	1.235	1.005	0.256	
P	-	0.219	0.426	0.475	

Table III. Comparison of grading of blood perfusion of fetal kidney by Doppler detection among three groups of pregnant women.

Groups	Control group (n=49)	Mild pre-hypertension group (n=43)	Severe pre-hypertension group (n=38)	χ^2	P
Grade I	46 (93.88)	9 (20.93)	0 (0.00)	4.59	0.002
Grade II	3 (6.12)	16 (37.21)	7 (18.42)		
Grade III	0 (0.00)	11 (25.58)	11 (28.95)		
Grade IV	0 (00.00)	7 (16.28)	20 (52.63)		

Table IV. Comparison of Doppler monitoring parameters among three groups of pregnant women.

	Control group (n=49)	Mild pre-hypertension group (n=43)	Severe pre-hypertension group (n=38)	F	P
VI	21.46±4.28	48.15±5.24	8.73±1.09	14.023	0.021
FI	16.27±4.35	40.32±4.31	7.10±1.14	15.239	0.015
VFI	11.25±4.17	37.10±5.22	4.21±1.28	10.225	0.039

Table V. Correlation between Doppler monitoring parameters and blood perfusion in three groups of pregnant women.

	Vascular index		
	VI	FI	VFI
Control group/Mild pre-hypertension group	0.876	0.021*	0.015*
Control group/Severe pre-hypertension group	0.023*	0.312	0.148
Mild pre-hypertension group/Severe pre-hypertension group	0.035#	0.038#	0.031#

differences in VI, FI and VFI between mild pre-hypertension group and control group ($P < 0.05$). However, there was no significant differences in FI and VFI between severe pre-hypertension group and control group ($P < 0.05$), (Table V). It shows that analysis of correlation between three-dimensional energy index of fetal kidney and indexes of pregnant women's uterine artery, fetal umbilical artery and gestational weeks. There was no significant correlation between fetal kidney FI and indexes of pregnant woman's uterine artery, fetal umbilical artery and gestational weeks,

while fetal kidney VI and fetal kidney VFI were correlated with other indexes. Meanwhile, fetal kidney VI and fetal kidney VFI were positively correlated with gestational weeks.

Table VI. Analysis of correlation between three-dimensional energy index of fetal kidney and indices of pregnant woman's uterine artery and fetal umbilical artery and gestational weeks (r value).

Item	Fetal umbilical artery S/D	Pregnant woman's uterine artery PI	Gestational weeks
Fetal kidney VI	-0.487	-0.443	0.711
Fetal kidney FI	-0.154	-0.123	0.204
Fetal kidney VFI	-0.564	-0.462	0.669

Three-dimensional color power angiography (3D-CPA) is a new imaging mode of Doppler ultrasonography, which can display blood supply stereoscopically and intuitively (Liu and Zhao, 2018). CDFI and CPA are usually used to detect the blood supply of renal tumors, while 3D-CPA is used to calculate ty index (VI) and evaluate its clinical value in diagnosing and differentiating kidney. When fetal urethral dilatation hydronephrosis is detected before birth, the prediction of fetal renal function after birth is mainly evaluated by Doppler ultrasonography, and biochemical analysis of fetal urine or blood is carried out. The Doppler ultrasonography parameter has long been used as an index to predict renal function, such as amniotic fluid index and renal parenchyma evaluation. Studies have shown that this parameter is not sensitive and specific enough. Studying fetal blood or urine biochemistry has always been considered to improve the sensitivity of prenatal evaluation of fetal kidney function, and these indicators can also be used to predict the prognosis of fetuses with intrauterine growth restriction after birth.

CPA depends on the density, scattering intensity or energy of red blood cells in blood, which depends on the number of red blood cells passing through each area and the amplitude signal (Guo *et al.*, 2018). Therefore, the parameter not strictly limited by Nyquist is the energy signal corresponding to scattering objects in blood, rather than the flow velocity. Therefore, CPA is more sensitive to low speed and continuously displays blood vessels without confusion. Combining CPA with 3D technology, 3D-CPA

is a new technology, which can display three-dimensional blood vessel image of organs and tumor blood supply (Zhou and Zhang, 2018). On the basis of vascular anatomy and flow energy of organs and tumors, 3D-CPA is obtained, and the multisection plane of 100-250 2D-CPA 0.3-1.0 mm is inspected every time. The image acquisition time is between 15 sec and 30 sec, and the reconstruction time is less than 3 min. 3D-CPA can display the path, number and distribution of renal blood vessels, and evaluate renal blood supply. Because 3D-CPA shows the integration of blood supply in a continuous and three-dimensional manner, and shows the outline, size and corresponding vascular network of kidney, it is possible to quantitatively titrate the blood supply of kidney with VI.

One of the problems in 3D-CPA is its repeatability. It has been shown by Yang (2018) that VI and FI are affected by power Doppler settings such as gain, signal power and pulse repetition frequency. They are also affected by volume flow, attenuation, number of blood vessels and red blood cell density, but VI is linear and FI is cubic. With the increase of the distance between the transducer and the container, each index decreases, and there is a linear relationship between depth and VI. The relationship between depth and FI is more complex, especially above 55 mm. Therefore, VI seems to have a more predictable relationship, while FI shows a complex cubic relationship. To reduce these problems, it is important to point out that the preset of the Doppler ultrasonography machine used must always be the same, because the change of gray value, especially the color parameters such as pulse repetition rate and high-pass filter, leads to the difference in the number of color voxels. In other words, different settings on the Doppler ultrasonography machine lead to different results. When measuring the vascularization or blood flow index of the same woman with two different Doppler ultrasound presets, the results may be quite different. The power Doppler is related to the depth. According to the data of this study, the flow index was negatively correlated with the distance between transducers, making the vascularization index more reliable than the flow index. So, it is considered that they are superior in evaluating risk pregnancy. Even so, there are still some concerns about the repeatability and reliability of the proposed index. However, the correlation with the result data showed that MVI was promising in risk pregnancy. We think this can prove that the method is correct.

This study showed that 3D-CPA could display the vascular network in tissues, similar to stereo imaging or angiography (Mesquita *et al.*, 2015). 3D-CPA image also has some limitations. As the gestational age increases and the fetus continues to mature, it will block the kidney of the fetus, which will lead to insufficient images of the posterior and lateral walls. At the same time, the medical examination must be skilled enough, and the 3D images can be adjusted flexibly. The pregnant woman should

hold her breath and the fetus should be in a relatively quiet state before the images can be executed, because the pregnant woman's breathing and fetal movement will affect the images and deform and distort the interested areas. In addition, since the measurement algorithm of the machine and the setting of the data environment have a great influence on the results of the parameters, there are certain differences in these research results, which make the evaluation of the three parameters different (Guntupalli *et al.*, 2015). These factors affect the application of three-dimensional Doppler fetal vascular quantitative analysis in clinical trials of fetal renal function. Whether KVI can improve sensitivity in similar combinations, or how different excretion from some biochemical markers affects the vascularization and flow of fetal kidney will be of great significance (Duan *et al.*, 2020).

Supplementary material

There is supplementary material associated with this article. Access the material online at: <https://dx.doi.org/10.17582/journal.pjz/20201029141052>

Statement of conflicts of interest

The authors have declared no conflict of interest.

References

- Duan, F., Hu, M., Guo, C., Song, Y., Wang, M., He, L. and Zhou, L., 2020. *Chem. Eng. J.*, **398**: 125452. <https://doi.org/10.1016/j.cej.2020.125452>
- Guntupalli, K.K., Karnad, D.R. and Bandi, V., 2015. *Chest*, **148**: 1333-1345. <https://doi.org/10.1378/chest.14-2365>
- Guo, Q.J., Luo, Y.L. and Wu, M.L., 2018. *Anhui Med. Pharm. J.*, **22**: 1770-1772.
- Ju, C.N., Wang, S.R. and Chen, H.N., 2018. *J. Pract. Med. Tech.*, **25**: 1077-1079.
- Li, T.G., Nie, F. and Wang, Y.X., 2018. *J. clin. Ultras. Med.*, **20**: 675-678.
- Liu, G. and Zhao, P., 2018. *Guangdong Med. J.*, **39**: 2579-2583.
- Ma, B., Liu, X.L. and Wang, Y.X., 2018. *Chinese J. Family Plann. Gynecotokol.*, **10**: 48-51.
- Ma, R., 2019. *Modern Med. J. China*, **21**: 79-80.
- Mesquita, F.S., Ramos, R.S. and Pugliesi, G., 2015. *Biol. Reprod.*, **93**: 52. <https://doi.org/10.1095/biolreprod.115.129031>
- Sha, E.B., Wang, L.M. and Jing, C.L., 2019. *Guide China Med.*, **17**: 43-44.
- Tang, L., 2019. *Clin. Res. Pract.*, **4**: 29-31.
- Yang, Q., 2018. *J. Imag. Res. Med. Appl.*, **2**: 137-138.
- Zhang, L., 2018. Progress in ultrasonic diagnosis of placenta accrete. *Med. Equip.*, **31**: 199-200.
- Zhou, J.Y. and Zhang, Y., 2018. *Modern Instrum. Med. Treat.*, **24**: 16-18.

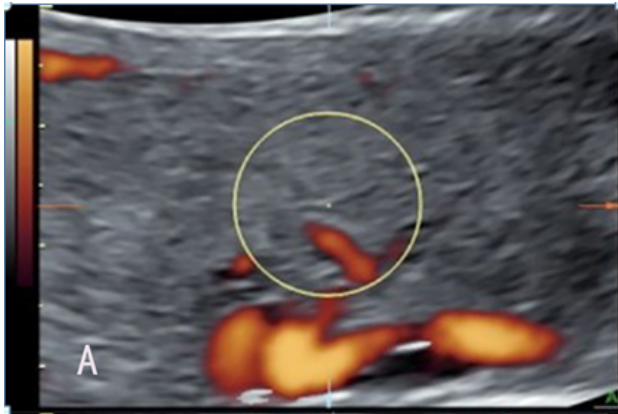

Supplementary Material

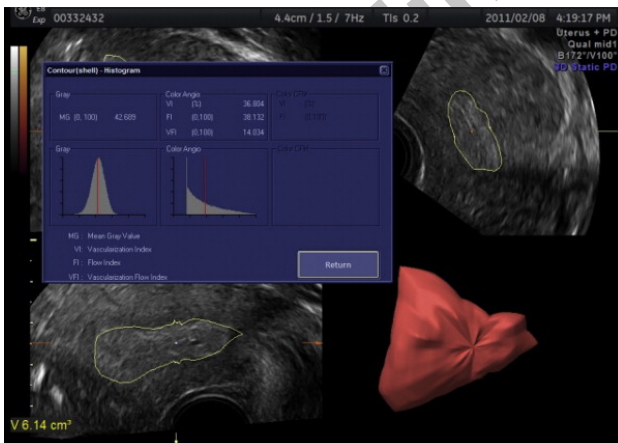
Assessment of Three Dimensional Color Power Doppler Technique for Detecting Fetal Renal Vascular Perfusion in Pregnant Women with Gestational Hypertension

Hong Liu and Rui Xu*

Obstetrics and Gynecology Department, The Third People's Hospital of Lixia District of Jinan City, Jinan, 2500000, China



Supplementary Fig. 1. 3D-CPA imaging of fetal kidney.



Supplementary Fig. 2. 3D-CPA volume image of fetal kidney.

* Corresponding author: xurui0739@126.com
0030-9923/2021/0001-0001 \$ 9.00/0
Copyright 2021 Zoological Society of Pakistan