



Short Communication

Pathology of Experimentally Induced Hydropericardium Syndrome in Ostrich

Attaur Rahman¹, Sadeeq ur Rahman^{1,*}, Ashfaq Ahmad², Abdul Sajid¹, Muhammad Asif Hussain¹, Mian Muhammad Salman¹, Niamat Ullah Khan¹, Kamran Khan³, Fazli Rabbani¹, Muhammad Akbar Shahid⁴, Irshad Ahmad⁵ and Shakoor Ahmad⁶

¹College of Veterinary Sciences and Animal Husbandry, Abdul Wali Khan University, Mardan

²Department of Plant Breeding and Genetics, University of Agriculture, Peshawar

³Sindh Poultry Vaccine Centre, Karachi

⁴Department of Pathobiology, Faculty of Veterinary Sciences, Bahauddin Zakariya University, Multan

⁵School of Biomedical Sciences, University of Leeds, United Kingdom

⁶Department of Animal Health, The University of Agriculture, Peshawar

ABSTRACT

Pathology of hydropericardium syndrome (HPS) induced by fowl adenovirus-4 (FAdV-4) in ostriches was compared with that of broiler chicken kept as standard. A $10^{6.25}$ /ml/bird (chicken lethal dose 50 (CLD₅₀)) was injected to ostriches and broiler (control) and were clinically observed for 7 days. Our results showed that a peak cloacal temperature was recorded on day 3 and day 4 with a 2.3°F and 1.2°F maximum rise in broiler and ostrich, respectively. A decrease in feed and water intake was recorded in both broiler and ostrich from 116 g to 82 g/bird and from 235 ml to 172 ml/bird for broiler, and from 1300g to 790 g/bird and from 1433 ml to 995 ml/bird for ostriches on days 0-7 post-inoculation. Interestingly, morbidity was observed 100%, while maximum mortality of 100% in broiler and 33% in ostriches was observed on day 7 and 6 post-inoculation, respectively. Interestingly, gross lesions were found similar comprising hydropericardium, hepatomegaly, hepatitis, nephritis and spleenomegaly. Altogether, albeit, FAdV-4 caused similar symptoms and lesions in ostriche, however, mortality remained comparatively lower.

Article Information

Received 03 November 2017

Revised 12 August 2018

Accepted 28 November 2018

Available online 19 March 2019

Authors' Contributions

AR, IA, MAS and SR conceived and designed the experiments. AR performed all the experimental work. AA, AS, MAH, MHS, NK, KK and SR helped in data analysis and writing of manuscript.

Key words

Hydropericardium syndrome, Ostrich, Experimental infection, Angara disease.

The fowl adenovirus serotype 4 (FAdV-4) has been implicated in hydropericardium syndrome (HPS) in chicken resulting huge economic losses in poultry industry of Pakistan. Chickens are considered primary hosts for the virus, but the disease has also been reported in pigeons, turkeys and ostrich chicks (Changjing *et al.*, 2016; Jadhao *et al.*, 1997). The prevalence of HPS, also known as Angara disease in Pakistan has been reported as high as 46.6% in chicken with higher mortality (up to 70%) in chicken of 3-7 weeks of age (Shafique *et al.*, 1993). The disease is characterized by its sudden onset, accumulation of jelly like fluid in the pericardial sac, inflammation of liver with overwhelming intranuclear inclusion bodies and congested kidneys. Furthermore, heart is misshaped, flabby with greasy fat deposits on epicardium, petechial and ecchymotic hemorrhages on heart musculature and the incised myocardium shows

congestion and suffusion with blood (Anjum 1990; Jaffery 1988; Kumar *et al.*, 1997). The course of the disease under natural conditions or following oral inoculation ranges from 7 to 15 days (Cheema *et al.*, 1989).

Diagnosis of the HPS infection is based on clinical signs, pathological lesions, histopathological alterations and virus isolation or identification. Field diagnosis however is mainly dependent on the clinical signs and pathological lesions observed on different organs such as liver and kidney. In addition to the characteristic clinical signs of HPS, the mortality and severity of the lesions may be greater in immune-compromised birds (Nakamura *et al.*, 2002). In Pakistan, ostrich farming is hardly a decade old and is developing quite fast. The emerging ostrich industry however is facing many obstacles including outbreaks of viral epidemics such as HPS. Unfortunately, very little scientific published information is available regarding the pathology, diagnosis and management of HPS in ostrich. Therefore, in this study, we injected a field clinical isolate of FAdV-4 to ostriches to experimentally induce the disease and observe its pathology for the purpose of

* Corresponding author: sadeeq@awkum.edu.pk
0030-9923/2019/0003-0001 \$ 9.00/0

Copyright 2019 Zoological Society of Pakistan

improved diagnosis and management. The findings have implications in ostrich health management and disease diagnosis.

Materials and methods

The current study was approved by the ethical committee of the Tando Jam Agriculture University, Sindh, and all experimental work including sample collection was carried out according to the national and institutional guidelines of animal ethics. All efforts were made to minimize the pain and discomfort to the animals during the experiment.

A total of 18 eighteen each 3-4 weeks broiler and 3-5 month old ostrich were arranged from the local market and brought to experimental farm of Sindh Poultry Vaccine Center (SPVC), Karachi. These birds were acclimatize for the next 24-48 h and were provided with and feed and water was provided with *ad libitum*.

A total of One hundred and ten 4-week old broiler chickens were used for determination of LD₅₀ as describe previously (Reed and Muench, 1938).

The FAdV-4 used for experimental induction of HPS was a kind gift from SPVC, Karachi. Eighteen birds of each broiler (4 weeks) and ostrich chickens (3 to 5 months) were divided in two groups (group A and B) comprising 9 birds each. Group A birds of chicken and ostriches were intramuscularly injected with a dose of 10^{6.25} LD₅₀/ml/bird as described previously (Raines *et al.*, 1997). The inoculated birds were then closely observed for development of any clinical signs, lesions, mortality, daily cloacal temperature, daily food and water intake. Dead Birds, seriously sick and euthanized, were necropsied for studying various lesions on visceral organs like heart, liver, kidneys and spleen.

Results and discussion

The results indicated that temperature increased

gradually from day 0 up to day 3 (104.5-106.8°F) in broiler and from day 0 up to day 4 (103.3-104.5°F) in ostrich and then gradually decreased from day 4 to day 7 (106.5-105.4°F) in broiler and day 5 to day 7 (104.3-103.9°F) in ostrich, respectively (Table I). Maximum rise in body temperature was 2.3°F in broiler, while 1.2°F in ostrich. On day 0 (before inoculation), mean cloacal temperature of broiler was found to be 104.5°F and 103.3°F in ostrich. The results in the present study are in accordance with the findings of Ahmad *et al.* (1989) who reported an increased body temperature in broiler after experimental inoculation of FAdV-4. The rise in temperature peaked on day-3 post-inoculation in broiler and on day-4 in ostrich (El-Attrache *et al.*, 2001; Ahmad *et al.*, 1989). Increased viral replication in viral diseases is directly proportional to rise in body temperature (Radostits *et al.*, 2000).

A marked decrease in daily feed intake was recorded in both broiler (116-82g/bird) and ostrich (1300-790g/bird) from days 0 to 7 post-inoculation, respectively. The results of the current study are in full agreement with previous studies (Anjum, 1990; Muneer *et al.*, 1989) who also reported that feed intake was reduced up to 25-50% on day 2 and day 3 of post inoculation, respectively (Table I). Reduced feed intake in HPS may be due to pyrexia along with virus induced hepatitis, hydropericardium and nephritis. A profound decrease in water intake was found in both broiler (235-172ml/bird) and ostrich (1433-995ml/bird) from day 0 to 7 post infections, respectively (Table I). The results of the present study are compatible with the findings of Anjum (1990) and Muneer *et al.* (1989) who reported that water intake was reduced up to 25-50% on day 2 and day 3 of post inoculation of FAdV-4 (Anjum, 1990; Muneer *et al.*, 1989).

A morbidity rate of 0-100% was recorded in both broiler and ostrich from day 0 to day 7 post-inoculation of FAdV-4 as observed earlier (Muneer *et al.*, 1989).

Table I.- Daily observation of the following parameters of broiler and ostrich after infection with FAdV-4.

Day	Broiler					Ostrich				
	CT (°F)	DFI (g)	DWI (ml)	Morb. (%)	Mort. (%)	CT (°F)	DFI (g)	DWI (ml)	Morb. (%)	Mort. (%)
0	104.5±0.48	116	235	0	0	103.3±0.23	1300	1433	0	0
1	106.4±0.83	112	229	40	0	103.7±0.16	1220	1390	11	0
2	106.6±0.72	110	223	60	0	104.1±0.20	1170	1320	22	0
3	106.8±0.53	104	214	77	10	104.1±0.22	1100	1240	44	0
4	106.5±0.26	98	203	85	30	104.5±0.37	1130	1180	55	11
5	106.2±0.98	93	191	83	60	104.3±0.37	940	1105	62	22
6	105.7±0.50	87	180	100	80	104.1±0.59	870	1030	85	33
7	105.4±0.14	82	172	100	100	103.9±0.51	790	995	100	0

CT, cloacal temperature; DFI, daily feed intake; DWI, daily water intake; Morb., Morbidity; Mort., Mortality. Control group (broiler) values: CT = 104.2°F; DFI= 118g/bird; DWI = 238ml/bird; Morbidity rate = 0%; Mortality rate = 0. Control group (ostrich) values: CT = 103.1°F; DFI = 1320g/bird; DWI = 1445ml/bird; Morbidity rate = 0%; Mortality rate = 0.

Typical clinical signs found in ostrich during induced HPS infection included depression, ruffled feathers, loose droppings sometimes with chalky material, paleness of comb and wattles, off feed and reluctance to move. Interestingly, similar clinical signs were also observed in the broiler chicken as observed earlier (El-Attrache *et al.*, 2001).

No mortality was recorded in broiler and ostrich until day 2 and 3 post-infection, respectively. Mortality started in broiler on day 3 and terminated at day 7, whereas in ostrich it started at day 4 and terminated on day 6 post-inoculation. Two ostriches were euthanized on day 7 post-inoculation to avoid unnecessary suffering as these were seriously sick (Table I). In contrast, Raines *et al.* (1997) inoculated five 3-days old ostrich chicks and found that all inoculated chicks died before 21 days post-inoculation. Higher mortality rate reported by Raines *et al.* (1997) may be due to higher susceptibility at a younger age since the age of ostrich chickens in the current experiment was 4-6 month. Of note, in the current study, ostrich have shown three times less mortality as compared to broiler. This phenomenon is however worthy to be investigated further.

Postmortem examination of ostrich and broiler was performed for all dead and euthanized birds suffering from induced HPS. Gross pathological changes in the affected visceral organs like heart, liver, kidneys and spleen were recorded. Each affected organ was scored according to intensity of lesions as light (1), moderate (2) and severe (3) as described in Supplementary Table I. The most prominent necropsy findings in the current study was accumulation of jelly like fluid in the pericardial sac, hepatitis, nephritis with necrosis and petechial and echymotic hemorrhages observed in 100% of the dead birds in both broiler and ostrich (Anjum, 1990; Muneer *et al.*, 1989; Raines *et al.*, 1997; El-Attrache *et al.*, 2001) (Supplementary Fig. 1). Spleen is also a site of virus replication therefore various lesions including hemorrhages, necrosis and inflammation are frequently observed in spleen of both broiler and ostrich (Supplementary Fig. 1). The findings of the current study are matching with previous findings (Arshad, 1991; Cheema *et al.*, 1989; Khan, 2008). Overall, our results showed that ostrich and broiler displayed a similar clinical picture when experimentally induced with HPS, however, ostrich revealed comparatively less mortality suggesting that HPS could be of reduced fatal nature in ostrich.

Conclusion

From this study, it has been concluded that FAdV-4 causes 100% morbidity in ostrich as like in broiler and displayed similar clinical picture, however, mortality in ostrich stayed comparatively lower suggesting that HPS could be less fatal for ostrich.

Acknowledgements

The authors highly acknowledge the kind gift of FAdV-1 gift from SPVC, and their facilitation of performing the studies in experimental poultry shed.

Supplementary material

There is supplementary material associated with this article. Access the material online at: <http://dx.doi.org/10.17582/journal.pjz/2019.51.3.SCI>

Statement of conflict of interest

The authors declare no conflict of interest.

References

- Ahmad, I., Afzal, M., Malik, M., Hussain, Z. and Hanif, W., 1989. *Pakistan J. agric. Res.*, **10**: 195-199. https://doi.org/10.1007/978-3-322-95534-0_19
- Anjum, A., 1990. *Avian Pathol.*, **19**: 655-660. <https://doi.org/10.1080/03079459008418721>
- Arshad, M., 1991. *Study of haematology and sodium, potassium levels in serum of broilers affected with hydropericardium syndrome*. M. Sc. thesis. Dept. Veterinary Pathology, CVS, Lahore.
- Changjing, L., Haiying, L., Dongdong, W., Jingjing, W., Youming, W., Shouchun, W., Jida, L., Ping, L., Jianlin, W. and Shouzhen, X., 2016. *Vet. Microbiol.*, **197**: 62-67. <https://doi.org/10.1016/j.vetmic.2016.11.005>
- Cheema, A., Ahmad, J. and Afzal, M., 1989. *Rev. Sci. Tech. Off. Int. Epiz.*, **8**: 789-795. <https://doi.org/10.20506/rst.8.3.420>
- El-Attrache, J., Villegas, P., O'Connor, B., Buhr, J. and Rowland, G., 2001. *Avian Dis.*, **45**: 442-446. <https://doi.org/10.2307/1592985>
- Jadhao, S., Kataria, J., Verma, K. and Sah, R., 1997. *Indian J. Comp. Microbiol. Immunol. Infect. Dis.*, **18**: 33-37.
- Jaffery, M., 1988. *J. Pak. Vet. Med. Assoc.*, **34**: 1-33.
- Khan, A.A., 2008. *A comparative study on the production and efficacy of different vaccines against avian adenovirus associated with hydropericardium syndrome*. PhD thesis, Deptt. of Microbiology and Molecular Genetics, University of the Punjab, Lahore, Pakistan.
- Kumar, R., Chandra, R., Shukla, S., Agrawal, D. and Kumar, M., 1997. *Trop. Anim. Hlth. Prod.*, **29**: 158-164. <https://doi.org/10.1007/BF02632346>
- Muneer, M., Ajmal, M., Arshad, M., Ahmad, M. and Chaudhry, Z., 1989. *Zootech. Int.*, **5**: 46-48.
- Nakamura, K., Tanaka, H., Mase, M., Imada, T. and Yamada, M., 2002. *Vet. Pathol.*, **39**: 403-406. <https://doi.org/10.1354/vp.39-3-403>

- Radostits, O., Gay, C., Blood, D. and Hinchcliff, K., 2000. *A textbook of the diseases of cattle, sheep, pigs, goats and horses*. WB Saunders, London, pp. 1329-1337.
- Raines, A.M., Kocan, A. and Schmidt, R., 1997. *J. Avian Med. Surg.*, **11**: 255-259.
- Reed, L.J. and Muench, H., 1938. *Am. J. Epidemiol.*, **27**: 493-497. <https://doi.org/10.1093/oxfordjournals.aje.a118408>
- Shafique, M., Khan, M., Javeed, M. and Khan, A., 1993. *Singap Vet. J.*, **16**: 58-64.

Online First Article



Supplementary Material

Short Communication: Pathology of Experimentally Induced Hydropericardium Syndrome in Ostrich

Attaur Rahman¹, Sadeeq ur Rahman^{1*}, Ashfaq Ahmad², Abdul Sajid¹, Muhammad Asif Hussain¹, Mian Muhammad Salman¹, Niamatullah Khan¹, Kamran Khan³, Fazle Rabbani¹, Muhammad Akbar Shahid⁴, Irshad Ahmad⁵ and Shakoor Ahmad⁶

¹College of Veterinary Sciences and Animal Husbandry, Abdul Wali Khan University, Mardan, Pakistan

²Department of Plant Breeding and Genetics, University of Agriculture, Peshawar, Pakistan

³Sindh Poultry Vaccine Centre, Karachi, Pakistan

⁴Bahauddin Zakariya University, Multan, Pakistan

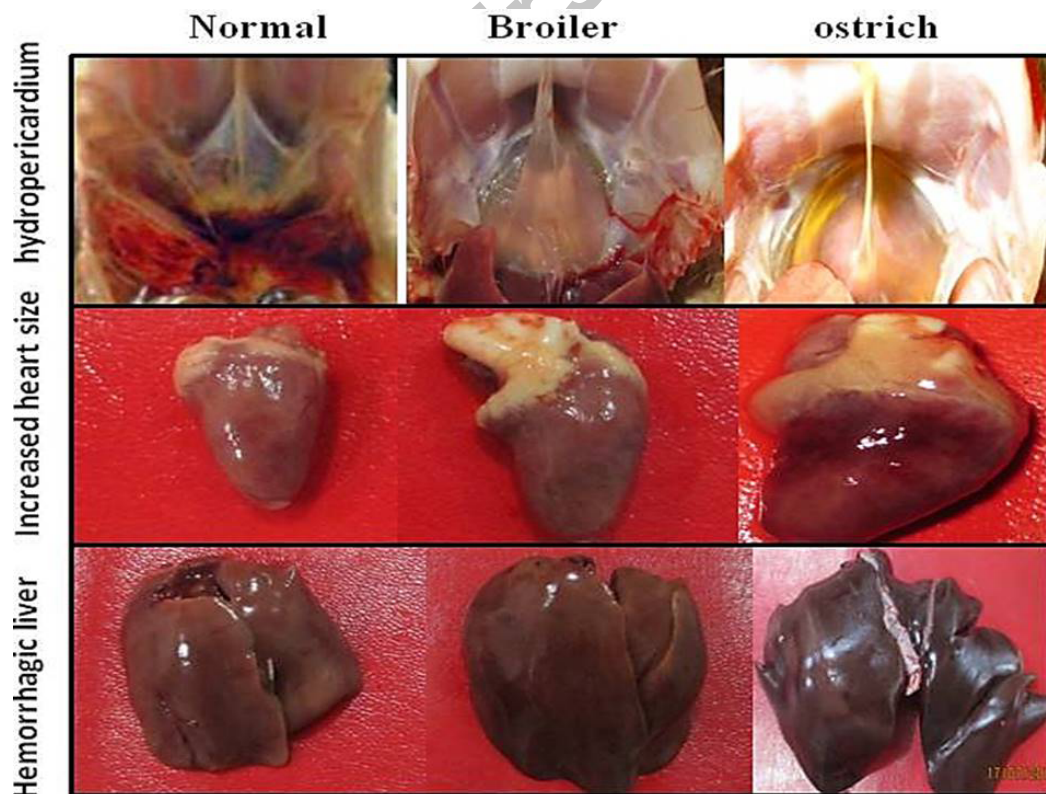
⁵School of Biomedical Sciences, University of Leeds, United Kingdom

⁶Department of Animal Health, The University of Agriculture, Peshawar, Pakistan

* Corresponding author: sadeeq@awkum.edu.pk

0030-9923/2019/0003-0001 \$ 9.00/0

Copyright 2019 Zoological Society of Pakistan



Supplementary Fig. S1. Postmortem lesions of induced HPS in broiler and ostrich. HPS was induced in broiler and ostrich birds and birds were examined for postmortem lesions. Fluid accumulation was observed both in broiler and ostrich. Beside, an obvious increase in the size of hearts, petechial and echymotic hemorrhages on postmortem resected heart and liver were also observed.

Supplementary Table I.- Gross pathological scoring of affected organs of FAdV-4 infected broiler and ostrich.

Organ affected	Mean scores							
	D0	D1	D2	D3	D4	D5	D6	D7
Broiler								
Liver	0	0	1	2	3	3	3	3
Kidney	0	0	2	3	3	3	3	3
Heart	0	0	1	3	3	3	3	3
Spleen	0	0	1	2	3	3	3	3
Ostrich								
Liver	0	0	0	1	2	3	3	3
Kidney	0	0	0	2	3	3	3	3
Heart	0	0	0	2	3	3	3	3
Spleen	0	0	0	0	1	2	3	3

0, no lesions; 1, light; 2, moderate; 3, severe.

Online First Article