



# Pathological Alterations during Co-Infection of Newcastle Disease Virus with *Escherichia coli* in Broiler Chicken

Qamar-un-Nisa<sup>1</sup>, Muhammad Younus<sup>2</sup>, Muti-ur-Rehman<sup>1</sup>, Azhar Maqbool<sup>3</sup>,  
Iahtasham Khan<sup>4</sup> and Sajid Umar<sup>5,\*</sup>

<sup>1</sup>Department of Pathology, University of Veterinary and Animal Sciences, Lahore

<sup>2</sup>Department of Pathobiology, College of Veterinary and Animal Sciences, Jhang

<sup>3</sup>Department of Parasitology, University of Veterinary and Animal Sciences, Lahore

<sup>4</sup>Department of Epidemiology and Public Health, College of Veterinary and Animal Sciences, Jhang

<sup>5</sup>Department of Pathobiology, Pir Mehr Ali Shah Arid Agriculture University, Rawalpindi, Pakistan

## ABSTRACT

Respiratory diseases are responsible for major economic losses at poultry farms especially during during co-infections of respiratory pathogens. However, impact of co-infections is not well known, especially in broilers. The current study was aimed to assess the probable synergism of *E. coli* (O78) and velogenic Newcastle disease virus (vNDV-CK-Pakistan-NARC-13N39-2013), in the broiler model. Three-week-old commercial broilers were inoculated with either vNDV, *E. coli* serotype O78 or both agents simultaneously or 3 days apart. The birds were clinically observed and swabbed daily. They were killed at 4 and 14 days after single or dual inoculations and were inspected for gross lesions. Samples of the respiratory organs (trachea, lungs, and air sacs) were taken for histological analyses. All the infected subjects showed clinical signs of varying severity. Co-infected groups showed the most obvious clinical signs, associated with significant higher mortality and respiratory organ abnormalities, in comparison with the mono-infected groups ( $P < 0.05$ ). There was a non-significant ( $P > 0.05$ ) effect of the inoculation time intervals between vNDV and *E. coli* inoculation (none or 3 days). Microscopic lesions staining supported clinical and macroscopic findings. Higher virus shedding ( $P < 0.05$ ) in oropharyngeal swabs was observed in co-infected groups than single infected groups. The results revealed that experimental co-infection of *E. coli* and NDV enhances the degree of severity of clinical signs, gross lesions and death rate and warns that *E. coli* and NDV can cause substantial economic losses by exercising additive or synergistic pathogenic effect in the reproduction of respiratory disease if given simultaneously or three days apart.

## Article Information

Received 25 April 2017

Revised 02 June 2017

Accepted 25 July 2017

Available online 12 October 2017

## Authors' Contribution

QN conducted the study and collected data. MY, MR and AM designed the study, analyzed and interpreted the data. IK and SU processed samples and drafted the manuscript.

## Key words

Broiler, Co-infection, *Escherichia coli*, Newcastle disease virus, Pathology.

## INTRODUCTION

Respiratory diseases have a major impact on poultry health, not only directly impacting growth and viability, but can also lead to secondary infections. Newcastle disease viruses (NDV) are particularly noteworthy due to their widespread circulation in domestic poultry (Alexander and Senne, 2008). It threatens the economy of farmer particularly when other co-infecting pathogens are present. Considerable information on the epidemiology of NDV in chickens and wild birds was published as a result of surveillance programs around the globe (Roussan *et al.*, 2008; Alexander and Senne, 2008).

NDVs, also called as avian Paramyxovirus 1, belong to genus Avulavirus of *Paramyxoviridae* family. Just like Avian influenza virus, these are single stranded and negative sense RNA viruses. NDV's also differ in the severity and type of the anomalies they cause, and various pathotypes, based on pathogenicity in poultry and the patterns around the protease cleavage site of fusion protein (F), have been defined in poultry: viscerotropic velogenic, neurotropic velogenic, mesogenic, lentogenic or respiratory, and asymptomatic (Alexander and Senne, 2008). Newcastle diseases *i.e.* infection in poultry by virulent (mesogenic and velogenic) strains of NDV, are diseases must be reported to the World Organization for Animal Health (Costa-Hurtado *et al.*, 2014). NDV causes high mortality to poultry in the field particularly during co-infection with other respiratory pathogens such as *Escherichia coli*. *E. coli* has been reported to be involved in co-infections with different respiratory pathogens

\* Corresponding author: [s.umar@uair.edu.pk](mailto:s.umar@uair.edu.pk);  
[sajncvi@gmail.com](mailto:sajncvi@gmail.com)  
0030-9923/2017/0006-1953 \$ 9.00/0  
Copyright 2017 Zoological Society of Pakistan

in poultry under field conditions (Kishida *et al.*, 2004; Majo *et al.*, 1997; Marien *et al.*, 2005; El Zowalaty *et al.*, 2011; Uman *et al.*, 2013). Pre-infection of NDV, infectious bronchitis virus or *Mycoplasma gallisepticum* enhances the susceptibility for *E. coli* infection in field conditions (Peighambari *et al.*, 2000). NDV and *E. coli* infections in chicken are crucial because they harm animal health and trade, and control costs are significantly high (Ahmed *et al.*, 2014). Co-infections of *E. coli* and NDV holds a complicated clinical manifestation which cause difficulty in the diagnosis of both of these pathogens, and unfortunately not much is documented about the connections between the two pathogens when co-infect poultry. Co-infection with more than one infectious agent is prevalent in poultry and results in severe clinical signs as compared to single pathogen infections (Stipkovits *et al.*, 2011, 2012; Pan *et al.*, 2012; Umar *et al.*, 2016a). On the other hand, infection with one pathogen can influence infection of second pathogen, which can be elaborated by viral interference, during which virus infected cells hamper the multiplication of other virus (da Palma *et al.*, 2010). Notable differences include alterations in tissue tropism, virus multiplication, virus progeny production and release, immunological and immunopathological responses. Moreover, viral interference is disadvantageous for the detection of virus in co-infected birds, as lower and undetectable viral titers might not give a comprehensive diagnosis (El Zowalaty *et al.*, 2011). Little information about the pathologic alterations during the course of co-infection of these two pathogens in poultry is available. Therefore, we decided to study the pathology during the co-infection of vNDV and *E. coli* (O78) in broilers.

In the present study, we investigated the consequences of co-infections of virulent NDV (vNDV) strain and *E. coli* (O78) in broiler chicken by inoculating both pathogens simultaneously and analyzing differences in the pathogenesis (clinical signs and lesions), titration of virus and shedding during single or co-infection. This study is the first controlled experiment that addresses the query of whether *E. coli* challenges effect pathogenesis of NDV or *vice versa*.

## MATERIALS AND METHODS

### *Experimental birds and management*

One hundred and fifty day old broiler chicks (*Gallus gallus*) (n=150) were procured from local well reputed hatchery and were confirmed negative for NDV through haemagglutination inhibition (Alexander and Senne, 2008). Standard managerial conditions was maintained with *ad libitum* feed and water. To avoid cross contamination, separate professionals were employed for feeding and

cleaning however, all the groups were given entirely similar management procedures. The birds were offered standard anti-coccidial agent (salinomycin) added feed, free of any antibacterial agents. The entire experimental procedure and protocol were presented to and approved by the Animal care and research committee of the University of Veterinary and Animal Sciences, Lahore.

### *Preparation of inoculums*

*E. coli* strain (O78) was provided by respected Dr. Muhammad Usman (Poultry Research Institute, Rawalpindi, Pakistan), originally isolated from chicken. A stock culture of *E. coli* strain was stored in glycerol broth (40%) at -80°C. McConkey agar was inoculated with a loopful of reference *E. coli* strain culture and incubated at 37°C for 24 h to obtain *E. coli* stock culture. Infecting *E. coli* cultures were prepared by 250 mL of DMEM (having Hepes 25mM as neutralizing medium) was inoculated with colonies from McConkey agar plate and incubated in an orbital shaker at 37°C for 24 h. The colony count was confirmed by plating 0.1 mL of 10<sup>5</sup> dilution of final culture on fresh McConkey agar plates.

NDV (NDV-CK-Pakistan-NARC-13N39-2013) was provided by respected Dr. Abdul Ghafar (National Agriculture Research Center, Islamabad, Pakistan). Virus amplification was performed by inoculation 9–11-day-old embryonating chicken eggs (ECE). The isolated pathotype confirmed as virulent by having a mean death time of 52 h in ECE (<60 being virulent) and intracerebral pathogenicity index of 1.83 (>1.5 for virulent) through standard protocols and procedures (Alexander, 1998). The stocks of virus were diluted in Brain heart infusion (BHI) broth containing 200U/mL penicillin, 100 U/mL polymyxin B sulfate, 200 µg/mL streptomycin, and 250 µg/mL gentamycin to finally obtain a titer of 10<sup>5.3</sup> EID<sub>50</sub> in 0.1mL.

### *Experimental design*

Broilers were individually identified, their individual body weight was measured and they were divided into groups in such a way that the average body weight of all the groups was uniform in Student's t test. Each isolation room having 20 birds served as treatment group and each isolation room had two isolators with ten birds each. Three-week-old commercial broilers were inoculated with either vNDV, *E. coli* serotype O78 or both agents simultaneously or 3 days apart. Each of 20 chickens were inoculated with 10<sup>5.3</sup> EID<sub>50</sub> in 0.1 mL of virus, divided into the right nares (50 %) and both the eyes (25% each). Non-infected controls were inoculated by PBS. The bacterial stock was diluted to yield a final titre of 10<sup>4</sup> colony forming unit (cfu)/0.5 mL and 0.5 mL of inoculum was given through intra-tracheal route in the experimental broiler birds. Birds were

grouped as follows: non infected group (negative control), Bacteria inoculated group (*E. coli* alone), Virus inoculated group (vNDV alone), group inoculated bacteria and virus simultaneously (*E. coli*+vNDV), group inoculated with bacteria and followed by virus inoculation three days later (*E. coli*/vNDV), group inoculated with virus and followed by *E. coli* inoculation three days later (vNDV/*E. coli*). The setup of experiment is summarized in Figure 1. Experiments were performed in two batches due to space constraints.

#### Clinical examination and sampling

Birds were monitored for clinical signs twice daily up to 14 days post infection (dpi), all birds were weighed at the start and end of experiment and observations were recorded in the form of general condition of birds, clinical signs of disease and mortality rate. We paid attention to any kind of pathology but especially to disorders of the respiratory system (head swelling, nasal discharge, sneezing, tracheal rales, coughing, and difficult breathing). Four birds from each group were euthanized on day 4 and 14 post-infection for the determination of gross and histopathological lesions. A scoring system was used to evaluate the severity of clinical signs. Each clinical sign was scored by the following scale: 0, no sign; 1, mild or slight; 2, moderate; 3, severe. The mean clinical score was based on the sum of clinical scores for each sign divided by the number of birds in each group at each observation time as previously described (Jirjis *et al.*, 2004).

#### Macroscopic and microscopic lesions examination

Birds were euthanized using an intracephalic injection of pentobarbital sodium (Anpro Pharmaceutical, Arcadia, CA) at 4 and 14 days post-infection (dpi). Necropsy was

performed immediately after the birds were euthanized. The presence of pathologic lesions was examined with special attention to respiratory organs. Lesions of trachea, bronchi, lungs and air sacs were scored for gross severity. Briefly, respiratory organs were scored altogether on a scale of 0 to 3: where, 0 = no lesions; 1 = mild or slight lesions; 2 = moderate severity lesions and 3 = severe lesions. The total of scores of one experimental group were used to statistically compare the severity of the lesions between the experimental groups. Trachea, lungs and air sacs samples were taken from each necropsied bird and fixed in 10% formalin for the determination of microscopic lesions. After fixation, tissues were processed in paraffin (sectioned at 3µm) and were stained with haematoxyline and eosin stains for microscopic investigation. Histological lesions were graded as: (-) no lesion, (+) light, (++) moderate or (+++) marked lesions as described previously (Nakamura *et al.*, 1992). Histopathological analyses were carried out by two certified veterinary pathologists.

#### Determination of virus shedding

Oropharyngeal swabs (OP) were taken every day from 1 to 8 days post virus inoculation to determine virus shedding in 1mL 1% gentamycin added phosphate buffered saline (PBS) and were kept at -80°C till further processing. Virus isolation (VI) was performed to determine virus shedding in OP swabs as reported earlier (Miller *et al.*, 2007). All the VI-positive swabs were titrated in 9–11 days old SPF ECE chicks as reported previously (Alexander and Senne, 2008). Virus titers were calculated through already reported Spearman–Kärber method (Kaerber, 1931) and were noted as mean embryo infectious dose (EID<sub>50</sub>/ 0.1 mL) on a Log<sub>10</sub> scale.

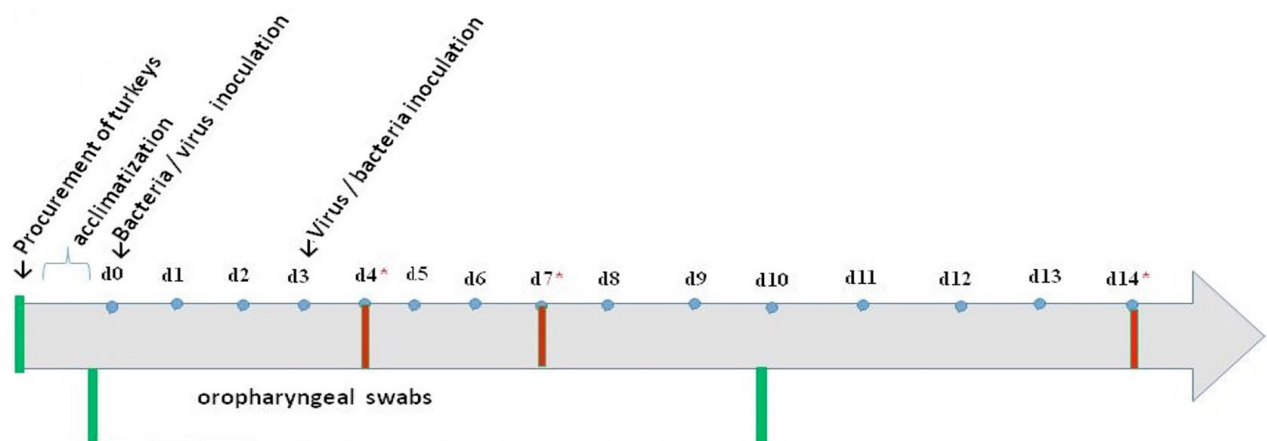


Fig. 1. Experimental setup of the co-infection study. Broiler groups: Non infected group (control negative). Bacteria inoculated group (*E. coli* alone). Virus inoculated group (vNDV alone). Simultaneous inoculation of virus and bacteria (vNDV+*E. coli*). Bacteria inoculation followed by virus inoculation (*E. coli*/vNDV). Virus inoculation followed by bacteria inoculation (vNDV/*E. coli*). \*Necropsy days.

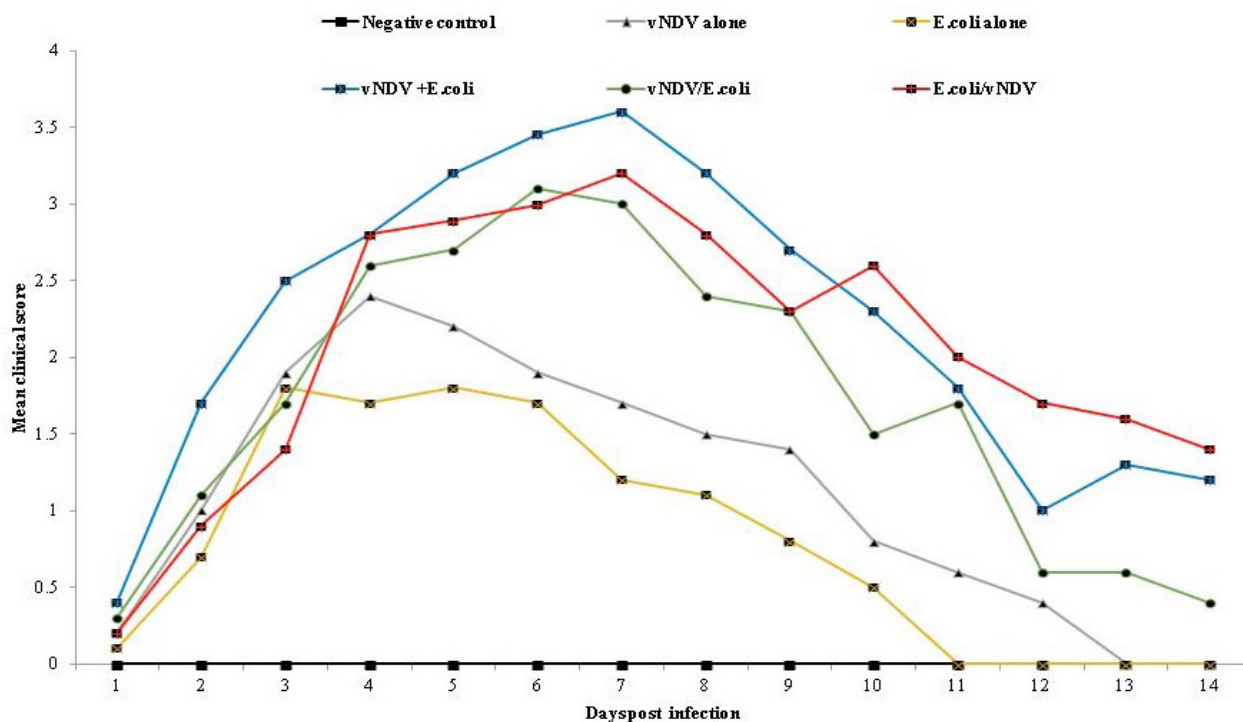


Fig. 2. Clinical scores in groups of broilers after inoculation with vNDV or *E. coli* (O78) or a combination of both. Each respiratory clinical sign was scored by the following scale: 0, no sign; 1, mild or slight; 2, moderate; 3, severe.

#### Determination of bacteria shedding

OP swabs were collected in PBS 1 to 8 days post-infection for the determination of bacterial shedding. Swabs were vortexed and tenfold serial dilutions were inoculated in duplicate Mckonkys agar. After 24-48 h of incubation at 37°C, viable counts were performed. Bacterial titres were expressed as Log<sub>10</sub> colonies forming units (CFU)/mL PBS solution.

#### Statistical analysis

Data was mentioned as means ±SEM (standard error of the mean) and analyzed using GraphPad Prism 6 software (GraphPad Software Inc., La Jolla, CA, USA). One Way Analysis of Variance (ANOVA) including Bonferroni correction were performed to assess putative differences in virus shedding in OP swabs, and in clinical signs and lesions at different time points in different groups. Differences were taken as statistically significant at  $p < 0.05$ .

## RESULTS

#### Clinical signs

Broiler birds of the negative control group remained healthy and active throughout the experiment period and did

not show any clinical sign. The birds remained active and became alert upon clapping and tapping the walls of shed. Milder clinical signs (depression and hunched posture) were shown by the birds affected with colibacillosis. Infection with vNDV alone caused clinical disease with moderate respiratory signs including snicking, swollen infraorbital sinuses open mouth breathing and foamy discharge in the mouth cavity. The vNDV and *E. coli* (O78) combined infection caused higher morbidity (Fig. 2) and mortality (Fig. 3) as compared to infection with either of single etiological agent. Survival rates were 100%, 95%, 82%, 65%, 59% and 56% in the control negative, *E. coli* alone, virus alone, *E. coli*/vNDV, vNDV/*E. coli*, and *E. coli*+vNDV groups, respectively (Fig. 3). The clinical symptoms were more severe and persisted markedly longer in co-infected groups. General sickness and head swelling was more pronounced in broilers of the vNDV/*E. coli* group than in broilers of the *E. coli*/vNDV and *E. coli*+vNDV groups.

#### Macroscopic and microscopic lesions

No bird in the negative control group demonstrated body cavity lesions and all organs were normal in size, shape and consistency. In *E. coli* group, walls of thoracic air sacs were thick and cloudy. Varying quantities of

serofibrinous exudates were accumulated on air sac and fibrin accumulation on liver and heart, and haemorrhages on kidney were also noticed in this group. On the other hand, only moderate air sacculitis, tracheal congestion and nephritis were observed in birds of the NDV group. In co-infected groups (*E. coli*+ NDV, *E. coli*/vNDV and vNDV/*E. coli*), the significant gross pathologic lesion was catarrhal exudates in trachea. The mucosal membrane of trachea was thick and erythematous, covered with thick mucus layer. Both the thoracic air sacs and abdominal air sacs were found filled with serofibrinous exudate. Sever gross lesions on liver, heart and kidney such as increase in size, haemorrhages, edema, and fibrin accumulation were more prominent in co-infected group at 4 dpi. The gross lesions were most prominent at 4 dpi in all infected groups while less prominent at 14 dpi. The pathologic lesion scores in co-infected groups had statistically significant higher values as compared to *E. coli* infected group or non-challenged control group ( $P < 0.05$ ). The mean clinical scores in different groups have been described in Figure 4.

In the control group, histology of all the organs were normal and no detectable lesion was recorded (Table I). Tracheal respiratory epithelium and primary bronchi in vNDV and *E. coli* group were statistically significantly thicker ( $P < 0.05$ ) than that in control group. Furthermore, the tracheal respiratory epithelium and primary bronchi of the birds of co-infected groups (*E. coli*+ NDV, *E. coli*/vNDV, vNDV/*E. coli*) were significantly thicker than those of birds in control group ( $P < 0.05$ ), NDV group ( $P < 0.05$ ), and *E. coli* group ( $P < 0.05$ ).

Microscopic examination of tracheal epithelium and primary bronchi in all infected groups revealed disruption of epithelial cells, desquamation of epithelial cells, loss of cilia and infiltration with histiocytes and lymphocytes. However, these changes were more pronounced and lasted longer in co-infected groups and histological scores were significantly higher as compared to control group and

other signal infected groups ( $P < 0.05$ ). Histology of the lungs of control birds showed healthy, non-ciliated flat epithelial cells in the parabronchi and secondary bronchi.

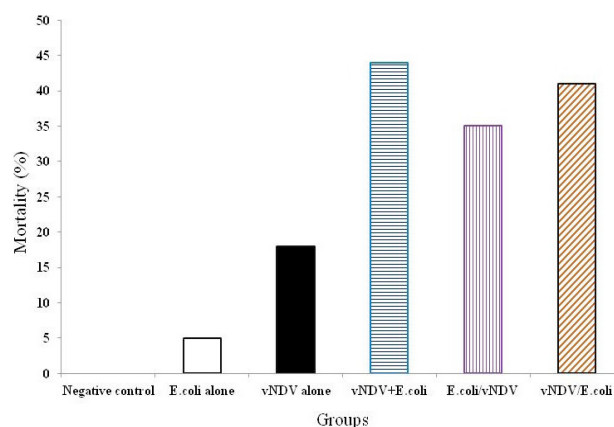


Fig. 3. Mortality (%) in different groups of broilers after inoculation with vNDV or *E. coli* (O78) or a combination of both.

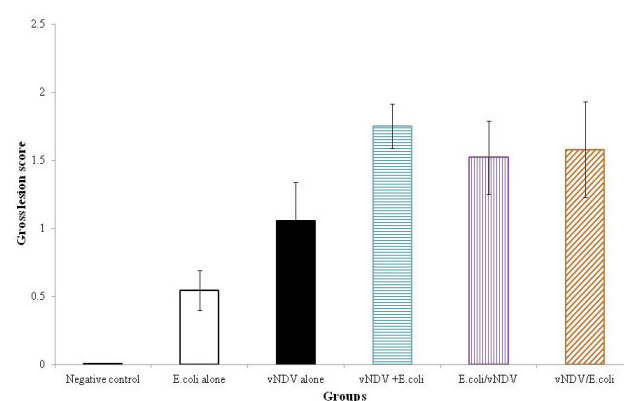


Fig. 4. Scores of macroscopic lesions in trachea, lungs and airsacs of broilers challenged with *E. coli* (O78) and vNDV singly or in combination.

Table I.- Summary of microscopic lesions and their intensity.

| Groups               | Intensity of microscopic lesions |  |                      |              |                   |              |                      |               |                   |
|----------------------|----------------------------------|--|----------------------|--------------|-------------------|--------------|----------------------|---------------|-------------------|
|                      | Trachea/bronchi                  |  |                      |              | Lungs/parabronchi |              |                      | Air sacs      |                   |
|                      | Tracheitis/bronchitis            | Necrosis and exfoliation of mucosal epithelium | Cellular infiltrates | Fib. exudate | Pneumonia         | Fib. exudate | Cellular infiltrates | Airsacculitis | Fibrinous exudate |
| Control              | -                                | -  | -                    | -            | -                 | -            | -                    | -             | -                 |
| <i>E. coli</i> alone | -                                | -  | +                    | -            | +-                | -            | +                    | ++            | ++                |
| vNDV alone           | ++                               | ++   | ++                   | +            | +                 | +            | +=                   | +             | +                 |
| vNDV+ <i>E. coli</i> | +++                              | +++  | +++                  | +++          | +++               | ++           | +++                  | +++           | ++                |
| <i>E. coli</i> /vNDV | ++                               | ++   | ++                   | ++           | ++                | ++           | ++                   | ++            | ++                |
| vNDV/ <i>E. coli</i> | +++                              | +++  | +++                  | +++          | ++                | +++          | +++                  | +++           | +++               |

Fib., Fibrinoluecocytic.

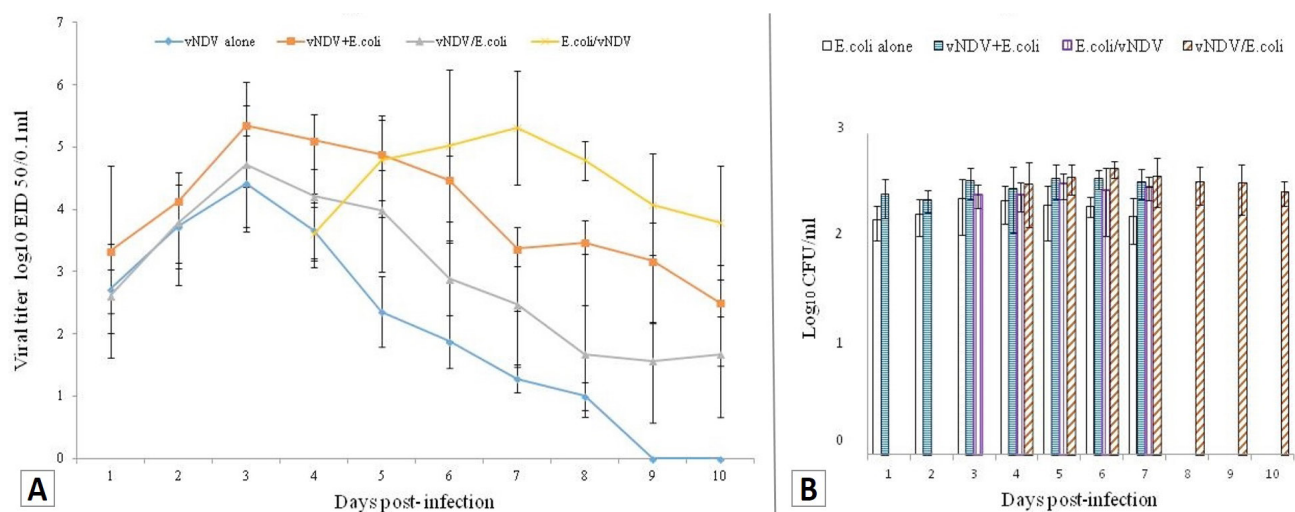


Fig. 5. Virus and bacteria shedding pattern in oropharyngeal swabs in different co-infected groups (A) and virus shedding in oropharyngeal swabs collected at different time points after vNDV inoculation (B) *E. coli* (O78) titres (Log<sub>10</sub> CFU/mL) in oropharyngeal swabs collected at different time points after *E. coli* (O78) inoculation.

No lymphocytes were accumulated in interparabronchial septum and in the blood around the vessels. A few germinal centers of small size were found. In infected groups, degeneration and hyperplasia at scattered sites of non-ciliated epithelial cell layer were recorded in the parabronchi and secondary bronchi. Cellular debris, serous exudate and heterophils were accumulated in the atrium, parabronchi and infundibulum and secondary bronchi. However, microscopic lesions were significantly more intense in severity than control negative or single infected groups.

#### Determination of virus shedding

Efficient virus replication was observed in all virus inoculated groups. All co-infected groups showed significantly higher virus shedding than other group broiler ( $p < 0.05$ ) at day 4 post-inoculation (Fig. 5A). However, virus shedding was non-significantly different between different co-infected groups.

#### Determination of bacterial shedding

*E. coli* (O78) was not found in OP swabs from negative control birds. The results of *E. coli* (O78) titrations of OP swabs of the rest of the groups are shown in Figure 5B. Mean titres (Log<sub>10</sub> CFU/mL) for each experimental group are depicted. Bacteria shedding was significantly higher in co-infected groups than single infected groups. Bacteria shedding was statistically non-significant ( $p > 0.05$ ) among different co-infection groups except vNDV/*E. coli* group who showed significantly higher bacteria shedding than *E. coli*/vNDV group at 6 dpi ( $P < 0.05$ ).

## DISCUSSION

Infectious respiratory diseases are of major concern in the modern poultry industry around the globe. It imparts substantial economic issues because of higher treatment cost and rates of mortality and carcass condemnation. Respiratory diseases had been documented because of mixed or/and single infections with different infectious agents (Yashpal *et al.*, 2004; Sid *et al.*, 2015). It is hypothesized that some organisms complement comprehensively each other as compared to other organisms. Co-infections of poultry cause serious complications in clinical manifestation of disease making its diagnosis difficult and less documentation of interactions between co-infecting pathogens make the situation even worst (Haghighat-Jahromi *et al.*, 2008; Costa-Hurtado *et al.*, 2014). Although, NDV is of major concern in this context, other respiratory viruses, avian influenza viruses, infectious bronchitis virus, and avian metapneumoviruses also cause secondary infections. Various bacteria are also of concern, including MG, *E. coli*, *Haemophilus paragallinarum*, *Ornithobacterium rhinotracheal* and, *Staphylococcus aureus* (Haghighat-Jahromi *et al.*, 2008). Co-infection of *E. coli* and influenza viruses has been reported in poultry. Natural viral and bacterial infections are thought to occur simultaneously and have been documented in poultry (Umar *et al.*, 2016b; Pan *et al.*, 2012), but unfortunately, the effects of such combined infections on the poultry health status is still not well understood. Combined viral and bacterial infections are common in poultry in field conditions and result in

more severe disease as compared to infections involving single agent (Stipkovits *et al.*, 2011, 2012; Pan *et al.*, 2012). A direct comparison with some of the parameters of this study outcomes is not recommended because of the dearth of published data on those parameters.

In the present study, *E. coli* infection caused classical lesions as reported previously (Peighambari *et al.*, 2000; Nakamura *et al.*, 1992). Moreover, clinical signs and lesions were significantly more severe and persisted longer in co-infected broilers than in birds infected with a single pathogen ( $p < 0.05$ ) possibly due to exaggeration of inflammatory responses (Dwars *et al.*, 2009). Respiratory distress was slightly higher in broilers inoculated with *E. coli* first and followed by vNDV while co-infected broilers showed more head swelling when vNDV was inoculated first followed by inoculation of *E. coli* possibly due to increased multiplication of *E. coli* after vNDV infection. However, this difference was found non-significant ( $p > 0.05$ ). It has been reported that infectious bronchitis virus increases *E. coli* infection susceptibility leading to severe respiratory distress (Matthijs *et al.*, 2003, 2009; Dwars *et al.*, 2009). Similarly, mortality was statistically significantly higher in co-infected groups. There was non-significant impact of *E. coli* and vNDV inoculation sequence in co-infected groups on disease outcome. All inoculated broilers in co-infected groups showed more or less similar clinical picture. Histopathological analysis supported clinical and gross findings. Virus shedding in OP swabs was significantly higher in co-infected groups than single infected groups. It seems that *E. coli* might have played a role in rapid replication of vNDV leading to higher virus shedding in OP swabs. However, No clear difference existed between single and dual inoculated birds regarding the shedding of *E. coli* in OP swabs. We determined pathogens shedding in OP swabs that actually reflect the pathogen shedding in the upper and not lower respiratory system. Secondly, we can assume that the severity of lesions may also be attributed to the innate immune response. Our experimental vNDV infection caused lesions are in agreement with field outbreak (Miller *et al.*, 2007, 2013). Inflammatory reaction and deciliation in trachea, cellular degeneration of the mucous gland respiratory epithelial damage were likewise previously demonstrated (Alexander and Senne, 2008).

In conclusion, it was shown that the *E. coli* strain (O78) and vNDV alone are able to produce moderate respiratory infection through adhesion and colonization of the respiratory tract, but without each other help do not induce severe respiratory disease and mortality in suspected broilers. The results of current study clearly indicate the occurrence of marked synergistic or additive effects between two distinct respiratory pathogens of

poultry. The established *E. coli* (O78) single and vNDV/*E. coli* combined infection models can be used to further probe the *E. coli* colonization and the vNDV/*E. coli* synergy. Further, the vNDV/*E. coli* co-infection model can be a tool to analyze curative and preventive measures to curtail the respiratory diseases. Considering the marked spread of *E. coli* and vNDV infections in poultry, a surveillance of vNDV and routine diagnosis of *E. coli* infection and anti *E. coli* treatment of flocks will help to avoid establish severe clinical disease which eventually will drop down the economic losses due to such combos. Continuous surveillance of vNDV infection and co-infections studies in experimental poultry models is warranted to find new strategies to control their circulation in domestic and wild poultry. The timing of co-infection would also require further systematic experimental studies to understand the role of prior/post/simultaneous inoculation in disease outcome, pathogenesis and virus shedding pattern. The present study unveils the multi-factorial respiratory disease complex in poultry, showing the aggravated outcome of vNDV infection in acutely *E. coli* predisposed broilers birds as compared to single vNDV effected birds. A clear understanding of the interaction between the various pathological agents will help making better diagnosis and treatment leading to better control of respiratory infections in poultry.

## ACKNOWLEDGEMENTS

We are thankful to Dr. Muhammad Usman (Poultry Research Institute Rawalpindi, Pakistan) and Dr. Abdul Ghafar (National Agricultural Research Centre, Islamabad, Pakistan) for providing strains of *E. coli* and Newcastle disease virus for inoculation. We are also thankful to the laboratory staff for sampling and technical help during the study.

### *Statement of conflict of interest*

The authors declare that there are no competing interests regarding the publication of this paper. None of the authors of this paper has a financial or personal relationship with other people or organizations that could inappropriately influence or bias the content of the paper.

## REFERENCES

- Alexander, D.J. and Senne, D.A., 2008. *Newcastle disease*. In: *Diseases of poultry*, 12<sup>th</sup> edition (eds. Y.M. Saif, J.R. Glisson, L.R. McDougald, L.K. Nolan and D.E. Swayne). Blackwell Publishing, Ames, Iowa, USA, pp. 75–100.
- Alexander, D.J. and Swayne, D.E., 1998. *Newcastle*

- disease virus and other avian paramyxoviruses. In: *A laboratory manual for the isolation and identification of avian pathogens* (eds. D.E. Swayne, J.R. Glisson, M.W. Jackwood, J.E. Pearson and W.M. Reed). The American Association of Avian Pathologists, Kennett Square, PA, pp. 156–163.
- Ahmed, K., Raja, I., Hussain, I., Jan, M. and Latif, A., 2014. Prevalence of *Escherichia coli* in suspected urinary tract infected patients and their sensitivity pattern against various antibiotics in Gilgit-Baltistan, Pakistan. *Pakistan J. Zool.*, **46**: 1783–1788.
- Costa-Hurtado, M., Afonso, C.L., Miller, P.J., Spackman, E., Kapczynski, D.R., Swayne, D.E., Shepherd, E., Smith, D., Zsak, A. and Pantin-Jackwood, M., 2014. Virus interference between H7N2 low pathogenic avian influenza virus and lentogenic Newcastle disease virus in experimental co-infections in chickens and turkeys. *Vet. Res.*, **45**: 1. <https://doi.org/10.1186/1297-9716-45-1>
- da Palma, T., Doonan, B.P., Trager, N.M. and Kasman, L.M., 2010. A systematic approach to virus-virus interactions. *Virus Res.*, **149**: 1–9. <https://doi.org/10.1016/j.virusres.2010.01.002>
- Dwars, R.M., Matthijs, M.G.R., Daemen, A.J.J.M., van Eck, J.H.H., Vervelde, L. and Landman, W.J.M., 2009. Progression of lesions in the respiratory tract of broilers after single infection with *Escherichia coli* compared to superinfection with *E. coli* after infection with infectious bronchitis virus. *Vet. Immunol. Immunopathol.*, **127**: 65–76. <https://doi.org/10.1016/j.vetimm.2008.09.019>
- El Zowalaty, M.E., Chander, Y., Redig, P.T., Abd El Latif, H.K., El Sayed, M.A. and Goyal, S.M., 2011. Selective isolation of avian influenza virus (AIV) from cloacal samples containing AIV and Newcastle disease virus. *J. Vet. Diagn. Invest.*, **23**: 330–332. <https://doi.org/10.1177/104063871102300113>
- Haghighat-Jahromi, M., Asasi, K., Nili, H., Dadras, H. and Shoostari, A.H., 2008. Coinfection of avian influenza virus (H9N2 subtype) with infectious bronchitis live vaccine. *Arch. Virol.*, **153**: 651–655. <https://doi.org/10.1007/s00705-008-0033-x>
- Jirjis, F.F., Noll, S.L., Halvorson, D.A., Nagaraja, K.V., Martin, F. and Shaw, D.P., 2004. Effects of bacterial coinfection on the pathogenesis of avian pneumo virus infection in turkeys. *Avian Dis.*, **48**: 34–49. <https://doi.org/10.1637/7017>
- Kaerber, G., 1931. 50% end-point calculation. *Arch. exp. Pathol. Pharmacol.*, **162**: 480–483.
- Kishida, N., Sakoda, Y., Eto, M., Sunaga, Y. and Kida, H., 2004. Co-infection of *Staphylococcus aureus* or *Haemophilus paragallinarum* exacerbates H9N2 influenza A virus infection in chickens. *Arch. Virol.*, **149**: 2095–2104. <https://doi.org/10.1007/s00705-004-0372-1>
- Majó, N., Gibert, X., Vilafranca, M., O’Loan, C.J., Allan, G.M., Costa, L., Pagès, A. and Ramis, A., 1997. Turkey rhinotracheitis virus and *Escherichia coli* experimental infection in chickens: histopathological, immunocytochemical and microbiological study. *Vet. Microbiol.*, **57**: 29–40. [https://doi.org/10.1016/S0378-1135\(97\)00101-6](https://doi.org/10.1016/S0378-1135(97)00101-6)
- Marien, M., Decostere, A., Martel, A., Chiers, K., Froyman, R. and Nauwynck, H., 2005. Synergy between avian pneumovirus and *Ornithobacterium rhinotracheale* in turkeys. *Avian Pathol.*, **34**: 204–211. <https://doi.org/10.1080/03079450500096414>
- Matthijs, M.G.R., Ariaans, M.P., Dwars, R.M., van Eck, J.H.H., Bouma, A., Stegeman, A. and Vervelde, L., 2009. Course of infection and immune responses in the respiratory tract of IBV infected broilers after superinfection with *E. coli*. *Vet. Immunol. Immunopathol.*, **127**: 77–84. <https://doi.org/10.1016/j.vetimm.2008.09.016>
- Matthijs, M.G.R., Van Eck, J.H.H., Landman, W.J., Stegeman, J.A., 2003. Ability of Massachusetts-type infectious bronchitis virus to increase colibacillosis susceptibility in commercial broilers: A comparison between vaccine and virulent field virus. *Avian Pathol.*, **32**: 473–481. <https://doi.org/10.1080/0307945031000154062>
- Miller, P.J., Afonso, C.L., El Attrache, J., Dorsey, K.M., Courtney, S.C., Guo, Z. and Kapczynski, D.R., 2013. Effects of Newcastle disease virus vaccine antibodies on the shedding and transmission of challenge viruses. *Dev. Comp. Immunol.*, **41**: 505–513. <https://doi.org/10.1016/j.dci.2013.06.007>
- Miller, P.J., King, D.J., Afonso, C.L. and Suarez, D.L., 2007. Antigenic differences among Newcastle disease virus strains of different genotypes used in vaccine formulation affect viral shedding after a virulent challenge. *Vaccine*, **25**: 7238–7246. <https://doi.org/10.1016/j.vaccine.2007.07.017>
- Nakamura, K., Cook, J.K.A., Frazier, J.A. and Narita, M., 1992. *Escherichia coli* multiplication and lesions in the respiratory tract of chickens inoculated with infectious bronchitis virus and/or *E. coli*. *Avian Dis.*, **36**: 881–890. <https://doi.org/10.2307/1591546>
- Pan, Q., Liu, A., Zhang, F., Ling, Y., Ou, C., Hou, N. and He, C., 2012. Coinfection of broilers with *Ornithobacterium rhinotracheale* and H9N2 avian influenza virus. *BMC Vet Res.*, **8**: 104. <https://doi.org/10.1186/1746-6148-8-104>



- Peighambari, S.M., Julian, R.J. and Gyles, C.J., 2000. Experimental *Escherichia coli* respiratory infection in broilers. *Avian Dis.*, **44**: 759–769. <https://doi.org/10.2307/1593047>
- Roussan, D.A., Haddad, R. and Khawaldeh, G., 2008. Molecular survey of avian respiratory pathogens in commercial broiler chicken flocks with respiratory diseases in Jordan. *Poult. Sci.*, **87**: 444–448. <https://doi.org/10.3382/ps.2007-00415>
- Roussan, D.A., Khawaldeh, G. and Shaheen, I.A., 2015. A survey of *Mycoplasma gallisepticum* and *Mycoplasma synoviae* with avian influenza H9 subtype in meat-type chicken in Jordan between 2011 and 2015. *Poult. Sci.*, **94**: 1499–1503. <https://doi.org/10.3382/ps/pev119>
- Sid, H., Benachour, K. and Rautenschlein, S., 2015. Co-infection with multiple respiratory pathogens contributes to increased mortality rates in Algerian poultry flocks. *Avian Dis.*, **59**: 440–446. <https://doi.org/10.1637/11063-031615-Case.1>
- Stipkovits, L., Egyed, L., Palfi, V., Beres, A., Pitlik, E., Somogyi, M., Szathmary, S. and Denes, B., 2011. Effect of low-pathogenicity influenza virus H3N8 infection on *Mycoplasma gallisepticum* infection of chickens. *Avian Pathol.*, **41**: 51–57. <https://doi.org/10.1080/03079457.2011.635635>
- Stipkovits, L., Glavits, R., Palfi, V., Beres, A., Egyed, L., Denes, B., Somogyi, M. and Szathmary, S., 2012. Pathologic lesions caused by coinfection of *Mycoplasma gallisepticum* and H3N8 low pathogenic avian influenza virus in chickens. *Vet. Pathol.*, **49**: 273–283. <https://doi.org/10.1177/0300985811415702>
- Umar, S., Khan, M.I., Ahmed, S., Usman, M., Younus, M., Sarwar, F., Ali, S. and Nisa, Q., 2016a. *In vitro* and *in vivo* sensitivity of a Flagellated protozoan, *Histomonas meleagridis* to metronidazole and nitarson. *Pakistan J. Zool.*, **48**: 209-214.
- Umar, S., Khan, M.I., Younus, M., Yaqoob, M. and Nisa, Q., 2016b. A Report on an outbreak of botulism in broilers in Pakistan. *Pakistan J. Zool.*, **48**: 298-300.
- Usman, W., Siddique, M., Arshad, M., Ali, M. and Saeed, A., 2013. Preparation of Newcastle disease vaccine from VG/GA strain and its evaluation in commercial broiler chicks. *Pakistan J. Zool.*, **45**: 339-344.
- Yashpal, S.M., Devi, P.P. and Sagar, M.G., 2004. Detection of three avian respiratory viruses by single-tube multiplex reverse transcription-polymerase chain reaction assay. *J. Vet. Diagn. Invest.*, **16**: 244–248. <https://doi.org/10.1177/104063870401600314>