



# Effect of $^{32}\text{P}$ Application Combined with Timolol Maleate on Circulating Vascular Endothelial Growth Factor and Basic Fibroblast Growth Factor in Children with Cutaneous Hemangioma

Zongliang Li<sup>1</sup>, Rongxin Ma<sup>2,\*</sup>, Yan Wei<sup>1</sup> and Jianghua Zuo<sup>3</sup>

<sup>1</sup>Department of Nuclear Medicine, Xingtai People's Hospital, Xingtai 054001, China

<sup>2</sup>Department of Pharmacy, Xingtai People's Hospital, Xingtai 054001, China

<sup>3</sup>Department of Clinical Laboratory, Xingtai People's Hospital, Xingtai 054001, China

## ABSTRACT

The aim of this study was to investigate the effect of  $^{32}\text{P}$  application combined with timolol maleate on circulating vascular endothelial growth factor and basic fibroblast growth factor in children with cutaneous hemangioma. Eighty children with hemangioma treated in the Provincial Women and Children's Hospital from May 2018 to April 2019 were enrolled in the study, including 37 males and 43 females. The children were randomized into two groups according to the experiment: the conventional treatment group (taking one tablet of propranolol) and the combination treatment group (topical application of timolol maleate and  $^{32}\text{P}$  application). mRNA expression of VEGF and TGF- $\beta$  was increased in the conventional treatment group compared with the combination treatment group ( $P < 0.05$ ). The protein expression of bFGF and IL-6 in the combined treatment group was lower than that in the conventional treatment group ( $P < 0.05$ ). The conventional treatment group 30 (75.00%) had a lower tumor growth rate ( $P < 0.05$ ) than the combination treatment group (92.50%), and the combined treatment group 32 (80.00%) had a significantly reduced tumor depth compared with the conventional treatment group 21 (52.50%). There was no difference in the rate of bronchospasm between the conventional treatment group and the combination treatment group ( $P > 0.05$ ).  $^{32}\text{P}$  application combined with timolol maleate has a good therapeutic effect on hemangiomas, which can reduce the expression of circulating vascular endothelial growth factor and basic fibroblast growth factor.

## Article Information

Received 07 April 2021

Revised 30 April 2021

Accepted 03 May 2021

Available online 01 June 2022  
(early access)

Published 25 February 2023

## Authors' Contribution

ZL collected the samples. RM analysed the data. YW and JZ conducted the experiments and analysed the results. All authors discussed the results and wrote the manuscript.

## Key words

Hemangioma, Endothelial growth factor, Basic fibroblasts,  $^{32}\text{P}$  application, Timolol maleate.

## INTRODUCTION

Infantile hemangioma (IH) is a neoplastic proliferation of endothelial cells that grows after birth and usually subsides spontaneously (Abouzaripour *et al.*, 2018). IH is a benign tumor of endothelial cells, which is characterized by proliferation in infancy and then spontaneous regeneration in the next 5-10 years, often leaving fibrous fat residues, atrophic scar formation or telangiectasis (Shill *et al.*, 2018). The incidence rate in infants ranges from 4% to 10%. Common locations of hemangioma include

the periorbital area, oropharynx, anterior ear, or parotid gland area. Such hemangiomas require early and effective treatment to prevent permanent sequelae (Willis *et al.*, 2019). The proportion of hemangioma concerns the high incidence among infants and children. At present, there are not many treatment options, and corticosteroids have always been the first-line drugs for IH's systemic therapy (D'Haens *et al.*, 2018). Recently, oral propranolol, a non-selective  $\beta$ -receptor blocker, has become an alternative drug for IH treatment (Gossiel *et al.*, 2008). Corticosteroids and propranolol may incur significant systemic adverse reactions (Anupam *et al.*, 2018). The limit on the number of external agents has been adapted to corticosteroids and imiquimod for IH treatment. Recently, it has been reported that topical non-selective  $\beta$ -receptor blocker timolol maleate is a potential new topical drug for IH. In this study, timolol maleate combined with  $^{32}\text{P}$  application was used to explore its effect on circulating vascular endothelial growth factor (VEGF) and basic fibroblast growth factor (bFGF) in infants with cutaneous hemangioma.

\* Corresponding author: m243705339@163.com  
0030-9923/2023/0003-1091 \$ 9.00/0



Copyright 2023 by the authors. Licensee Zoological Society of Pakistan.

This article is an open access article distributed under the terms and conditions of the Creative Commons Attribution (CC BY) license (<https://creativecommons.org/licenses/by/4.0/>).

## MATERIALS AND METHODS

### *General information*

Participants in the study were 80 infant patients who underwent hemangioma treatment in the Provincial Maternal and Child Care Hospital from May 2018 to April 2019, including 37 male children and 43 female children. Aged 2~90 months, the infants had an average age of  $31.57 \pm 6.28$  months. There were 54 cases of vascular venous malformations and 26 cases of proliferative hemangioma. All the patients with vascular lesions were selected from the Department of Vascular Abnormalities of Maternal and Child Care Hospital, who were not completely cured.

Inclusion criteria: infant/children male or female, aged 1~10, first diagnosed with hemangioma by the hospital. If hemangioma is not treated, compound hemangioma will soon appear or affect appearance. The child should be accompanied by a guardian.

Exclusion criteria: those with contraindications to  $\beta$ -receptor blockers, including bronchial asthma, heart failure, sinus bradycardia, hypoglycemia, hypotension, heart block and known allergy to  $\beta$ -receptor blocker. Those with ulcers or mucosal hemangioma and those with abnormal mental state, congenital dementia were excluded.

### *Medical ethics issues*

The study obtained the informed consent of all participants and their guardians and was strictly reviewed and approved by the Institutional Review Board of People's Hospital.

### *Grouping*

The children who participated in the study were randomly divided into two groups: the conventional treatment group (the patients in this group were treated with propranolol tablets at a dose of 1.0 mg/kg once a day,  $n=40$ ), and the combined treatment group (the patients were locally treated with timolol maleate, combined with 0.5% gel and  $^{32}\text{P}$  application twice a day,  $n=40$ ). The two groups completed treatment and experiment with the help of doctors and guardians, during which medication was discontinued immediately for observation in case of harmful complications.

### *Evaluation before and during treatment*

Statistics on hemangioma lesion in children were as follows: the head and neck area 39 (48.75%), chest 20 (25.00%), limbs 15 (18.75%) and genitalia 6 (7.50%). Most children suffer from varying degrees of damage and impact on vision, food intake, urination, or bowel movements due to rapidly progressing ulcers or recurrent bleeding at the lesion. Some others sought treatment due to the possible

cosmetic deformities in the future. Before treatment, all patients underwent comprehensive medical history and physical examination, including clinical examination, ultrasound examination, echocardiography, blood pressure and blood glucose measurement. It was planned that the patients receive IHs score review, physical examination (including blood pressure, heart rate, and blood glucose measurements), body weight measurement at 1st, 3rd, 6th, and 9th month after the start of treatment to adjust the dose and record adverse reactions until the end of treatment. All patients underwent detailed cardiac assessment via echocardiogram and electrocardiogram and blood pressure was measured.

### *Dose and duration*

Children in each group received oral propranolol or topical timolol maleate and  $^{32}\text{P}$  application. With the guardian's consent, the propranolol dose was 1.0 mg/kg/day, because propranolol has always been a concern for safety of heart rhythm. In the other group, timolol maleate 0.5% gel was evenly applied to the tumor surface 3 times a day with the dose depending on the surface area of the lesion, and then  $^{32}\text{P}$  application was given for combined treatment. This dose was maintained throughout the study period. The treatment purpose is to inhibit further growth and promote complete regression of the lesion. The treatment was continued until the objective goal was reached or further improvement was impossible. Then, oral dose of propranolol was gradually reduced by half for 2 weeks and then to a quarter for 2 weeks, and then the medication was stopped. When the tumor surface composition showed no improvement, stop the topical use of propranolol or gel.

### *Treatment effect/cure rate and occurrence of unfavorable conditions*

Two senior oral and maxillofacial surgeons independently assessed all children by determining their hemangioma score at each follow-up visit. The hemangioma score was evaluated as effective, good, and fairly good treatment to assess its mobility and severity. Improvement indicators include 5 components: color, surface consistency, hardness, ultrasound depth, and organ involvement. Detailed information about the course of treatment and adverse events, vital signs (including heart rate and blood pressure, ulcers, *etc.*) were determined by the attending physician, but were not routinely checked at every follow-up visit. Improvement of hemangioma is defined as the change of hemangioma color from dark red to lighter shade. The full resolution of hemangioma is defined as the absence of stains at the location of the hemangioma.

### qRT-PCR

A blood sample of 1 mL was drawn from each child's vein on an empty stomach. The serum was separated from the sample within 1 to 2 h and frozen at 20°C. Total RNA was isolated from serum using TriFast and reverse transcribed with random hexamer. RNA was diluted to 500 ng/ $\mu$ l with RNase-free water. Ten microliters of each sample was mixed with 1  $\mu$ l of 3.5  $\mu$ M anchored oligomerization (dT) 23 and denatured at 70°C for 10 min, and then incubated on ice for 2 min. Quantitative RT-PCR was performed using DyNAmo SYBR Green qPCR kit under the following thermal conditions: 95°C for 7 min, 95°C for 40 sec, 60°C for 30 sec, and the kit was placed at 72°C for 15 sec. GAPDH was used as a standardized control (Table I).

**Table I.- RT-PCR primer sequences.**

Gene	Sequence (5' → 3')
<i>VEGF</i>	U: CGGTTTATAGCGCATATCGT D: CCCGGAGAGATTTTAGCTTAT
<i>TGF-<math>\beta</math></i>	U: TATGGTATAGCTGATCGAATG D: GTATAGATCGGGTAATATAGA
<i>GAPDH</i>	U: CGTCGCGCGCCCGTTTATA D: CGTATATATGGTATGATTAATAG

U, upstream; D, down stream.

### Western blot analysis

For Western blot, Biopsy tissue samples were homogenized with RIPA buffer containing protease inhibitors. An aliquot of tissue lysate was used for protein analysis and then separated on 12% SDS-PAGE. Western blot analysis was carried out under a standard protocol using antibodies from Santa Cruz Biotechnology. ECL fluorescence imaging was used to visualize the bands.

### Statistical analysis

One-way analysis of variance (ANOVA) was taken, followed by Tukey post-hoc test, and a significance test was performed for the difference in VEGF/FGF levels between all patients and the control group. Correlation was analyzed using Spearman rank correlation or Pearson C test. A p value smaller than 0.05 is considered as statistically significant. All analyses were performed using Medcalc 9.0.

## RESULTS AND DISCUSSION

### qRT-PCR analysis on mRNA expression of VEGF, TGF- $\beta$

mRNA expressions of angiogenesis related factors VEGF and TGF- $\beta$  in the two groups were analyzed by qRT-PCR, showing that mRNA expressions were higher

in the conventional treatment group than in the combined treatment group ( $P < 0.05$ ) (Fig. 1, Table II).

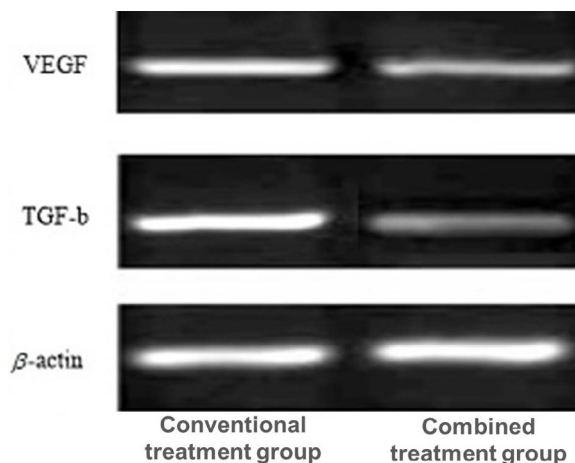


Fig. 1. qRT-PCR analysis on mRNA expression of VEGF, TGF- $\beta$ .

**Table II.- mRNA expression levels of VEGF and TGF- $\beta$  ( $\bar{x} \pm s$ , n=40) in conventional (A) and combined treatment groups (B).**

Group	n	VEGF	TGF- $\beta$
A	40	1.93 $\pm$ 0.31	1.75 $\pm$ 0.26
B	40	1.12 $\pm$ 0.20	1.06 $\pm$ 0.18
t value		5.127	4.068
P value		0.016	0.025

A, conventional treatment group treated with propranolol tablets at a dose of 1.0 mg/kg once a day.

B, combined treatment group locally treated with timolol maleate, combined with 0.5% gel and  $^{32}P$  application twice a day.

### Western blot analysis of protein expression of bFGF and IL-6

Western blot analysis of protein expression of bFGF and IL-6 in different groups showed that the protein expression of bFGF and IL-6 was lower in the combined treatment group than in the conventional treatment group ( $P < 0.05$ ) (Fig. 2, Table III).

**Table III.- Protein expression levels of bFGF, IL-6 ( $\bar{x} \pm s$ , n=40) in conventional (A) and combined treatment groups (B).**

Group	bFGF	IL-6
A	2.14 $\pm$ 0.38	1.95 $\pm$ 0.26
B	1.34 $\pm$ 0.22	0.86 $\pm$ 0.13
t value	6.534	4.288
P value	0.003	0.013

For details of A and B groups, see Table II.

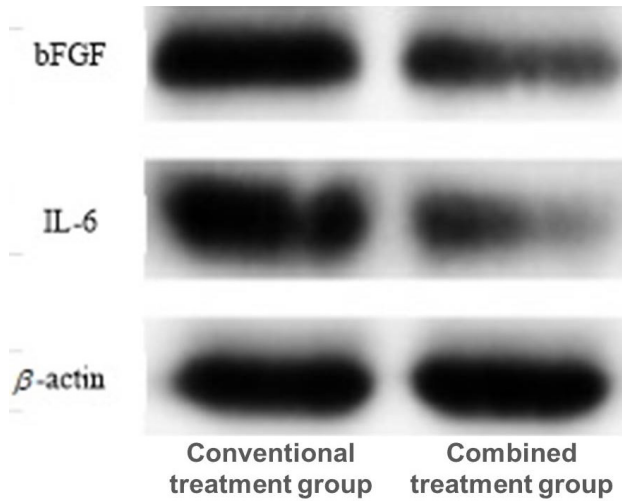


Fig. 2. Western blot analysis of protein expression of bFGF and IL-6.

*Comparison of treatment effect*

Six months after treatment, the hemangioma treatment effect in the two groups was compared and evaluated. The conventional treatment group 30 (75.00%) had lower tumor growth arrest rate than the combined treatment group 37 (92.50%) ( $P < 0.05$ ). The combined treatment group had increased significant relief rate in tumor depth 32 (80.00%) compared with the conventional treatment group 21 (52.50%) ( $P < 0.05$ ). The combined treatment group had increased rate in shallower tumor color 36 (90.00%) compared with the conventional treatment group 25 (62.50%) ( $P < 0.05$ ). The conventional treatment group had lower tumor area reduction rate 27 (67.50%) than the combined treatment group ( $P < 0.05$ ) (Fig. 3, Table IV).

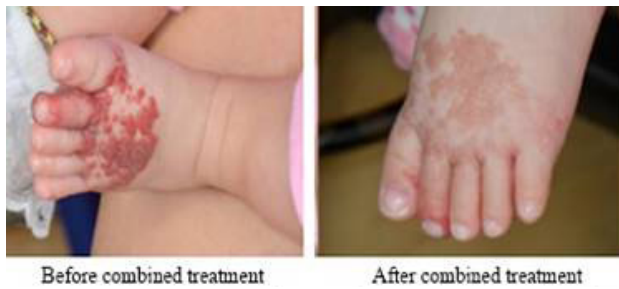

Fig. 3. Comparison of children in the combined treatment group before and after treatment.

*Comparison of cure rate*

The conventional treatment group had higher fairly good cure rate 15 (37.50%) than combined treatment group 7 (17.50%) ( $P < 0.05$ ), the combined treatment group had

higher good cure rate 19 (47.50%) than the conventional treatment group 9 (22.50%) ( $P < 0.05$ ), and the combined treatment group had higher rate of lesion disappearance 14 (35.00%) than the conventional treatment group 6 (15.00%), ( $P < 0.05$ ) (Table V).

**Table IV.- Comparison of the treatment effect ( $\bar{x} \pm s$ ,  $n=40$ ) in conventional (A) and combined treatment groups (B).**

Group	Growth arrest	Significant relief in tumor depth	Shallower tumor color	Tumor area reduction
A	30(75.0%)	21(52.5%)	25(62.5%)	19(47.5%)
B	37(92.5%)	32(80.0%)	36(90.0%)	27(67.5%)
$\chi^2$ value	5.217	4.326	6.140	5.278
<i>P</i> value	0.028	0.017	0.035	0.021

For details of A and B groups, see Table II.

**Table V.- Comparison of cure rate of the children ( $\bar{x} \pm s$ ,  $n=40$ ) in conventional (A) and combined treatment groups (B).**

Group	Fairly good	Good	Lesion disappearance
A	15(37.50%)	9(22.50%)	6(15.00%)
B	7(17.50%)	19(47.50%)	14(35.00%)
$\chi^2$ value	5.268	4.084	6.221
<i>P</i> value	0.015	0.026	0.034

For details of A and B groups, see Table II.

*Complications during treatment*

During the treatment, both groups had complications in different symptoms. Further medication was suspended in case of low blood pressure and bronchospasm. The conventional treatment group 3 (7.50%) had higher hypotension rate than the combined treatment group 1 (1.42%) ( $P < 0.05$ ), combined treatment group 1 (1.42%) had lower ulceration rate than the conventional treatment group 4 (10%) ( $P < 0.05$ ). The combined treatment group 8 (20.00%) had higher complication rate than the conventional treatment group 3 (7.50%) ( $P < 0.05$ ). No difference was shown in the rates of bronchospasm complications between the conventional treatment group and the combined treatment group ( $P > 0.05$ ) (Table VI).

**Table VI.- Comparison of complications ( $\bar{x}\pm s$ , n=40) between the conventional (A) and combined treatment groups (B).**

Group	Hypotension	Bronchospasm	Ulceration	Total
A	3(7.50%)	1(1.42%)	4(10%)	8(20.00%)
B	1(1.42%)	1(1.42%)	1(1.42%)	3(7.50%)
$\chi^2$ value	5.628	6.135	5.039	4.376
P value	0.024	0.217	0.011	0.026

For details of A and B groups, see Table II.

## DISCUSSION

IH is the most common benign vascular tumor in infants, whose various risk factors include premature birth, low birth weight, multiple pregnancies, advanced maternal age and in vitro fertilization, *etc.* More than 60% of IH affects the head and neck area (Cho *et al.*, 2018). Morphologically, hemangioma is divided into superficial type, deep type and compound type (Van *et al.*, 2018). The effect of propranolol on IH can be attributed to the molecular mechanisms: vasoconstriction, down-regulation of the protein kinase pathway activated by RAF-mitogen, reduced expression of VEGF and bFGF genes, inhibition of angiogenesis, and induction of apoptosis (Dierkes *et al.*, 2018). Propranolol therapy may cause serious systemic complications which demand close monitoring of the infant. The most common side effects of propranolol include hypotension, bradycardia, hypoglycemia and bronchospasm (Schaalan *et al.*, 2018). Oral propranolol has become the standard treatment for high-risk and deep IH, while timolol maleate is typically used for superficial lesions to minimize systemic side effects (Bébarová *et al.*, 2018). In this study, we introduced combination therapy of local  $^{32}\text{P}$  application combined with timolol maleate, which showed good therapeutic effect. Through statistical analysis of complications of the two groups, the combined treatment group 8 (20.00%) had a higher complication rate than the conventional treatment group 3 (7.50%) ( $P < 0.05$ ).

In this study, the overall remission rate was 100%, indicating that combination therapy can inhibit the growth of compound IH and promote its regression. According to reports, there are various methods for treating IH, including laser surgery, cryosurgery, and medical treatment (*i.e.*, corticosteroids, vincristine,  $\alpha$ -interferon, cyclophosphamide, and propranolol). Their response rate to compound IH is between 67%–100%. The previous case series and observational studies have shown that after the start of treatment, there are visible color changes and marked softening of the lesion within 1 month, followed by growth arrest or progressive rejuvenation (Martin *et*

*al.*, 2019). As we all know, cytokines play an important role in normal physiological processes (Zutt, 2019) as putative regulators of proliferation and degeneration of hemangioma. Changing the cytokine environment or the expression of specific genes in the lesion through steroid therapy provides insights into the possible mechanism of hemangioma response to steroids (Gumina and Yan, 2019). Hemangiomas are characterized by the proliferation of capillary endothelial cells, multiple stratification of the basement membrane and the accumulation of cellular components including macrophages, plasma cells, pericytes and mast cells (Desrosiers *et al.*, 2019). In this study, it was observed that individuals with hemangiomas had higher levels of bFGF. Western blot analysis of the protein expression of bFGF and IL-6 in different groups of children revealed that the combined treatment group had lower protein expression of bFGF and IL-6 than conventional treatment group ( $P < 0.05$ ). These results indicate that the production and metabolism of bFGF and VEGF are thought to be relevant to the pathogenesis of hemangioma. However, steroids reduced the transcripts of the cytokines PDGF-A and -B, IL-6, TGF- $\beta$ 1 and - $\beta$ 3. The reduced transcription of PDGFs is believed to promote cell proliferation, suggesting that steroids may cause accelerated regression of proliferative hemangiomas by inhibiting these cytokines. After treatment, a decrease in IL-6 m protein expression was observed. IL-6 is another growth factor that plays a role in angiogenesis. According to reports, this cytokine is attenuated by glucocorticoids (Kawaguchi *et al.*, 2019). VEGF is one of the most effective angiogenesis factors in the growth of hemangioma (Yang *et al.*, 2019). The angiogenesis factor can increase vascular permeability, stimulate endothelial cell proliferation, and prevent endothelial cell apoptosis (Wu *et al.*, 2020). According to the latest report, VEGF, matrix metalloproteinase and estrogen enhance the mobilization of bone marrow-derived endothelial progenitor cells, and bone marrow progenitor cells seem to play a key role in the formation of hemangioma due to five isoforms, all of which are bound to VEGFR-1 and VEGFR-2 receptors, thereby stimulating early hypoxia-induced angiogenesis (Cheng and Liu, 2020). Such proliferation depends on complex mechanisms, including activation of angiogenin, metalloproteinases, tumor growth factor- $\beta$ , and platelet-derived growth factors. Some studies have found that compared with progressive hemangiomas and vascular malformations, VEGF is strongly expressed in proliferative hemangiomas, showing different expressions in some isoforms. However, although numerous studies have examined expression of VEGF tissue, only one study in the literature examined and found elevated serum VEGF levels in hemangioma patients. Elevated



serum VEGF levels were also found in two patients with hemangioendothelioma (Gao et al., 2018).

To sum up, studies have shown that <sup>32</sup>P application combined with timolol maleate has a good therapeutic effect on hemangioma, which can reduce the expression of VEGF and bFGF in circulation (Gao et al., 2019).

### ACKNOWLEDGEMENT

The research is supported by: Application research of <sup>32</sup>P applicator brachytherapy combined timolol in the treatment of infantile hemangioma-Hebei Youth Science and Technology project, No. 20201580.

### Statement of conflict of interest

The authors have declared no conflict of interests.

### REFERENCES

- Abouzaripour, M., Fathi, F., Daneshi, E., Mortezaee, K., Rezaie, M.J. and Abdi, M., 2018. Combined effect of retinoic acid and basic fibroblast growth factor on maturation of mouse oocyte and subsequent fertilization and development. *Int. J. Fertil. Steril.*, **12**: 68.
- Anupam, K., Kaushal, J., Prabhakar, N. and Bhatnagar, A., 2018. Effect of redox status of peripheral blood on immune signature of circulating regulatory and cytotoxic T cells in streptozotocin induced rodent model of type I diabetes. *Immunobiology*, **223**: 586-597. <https://doi.org/10.1016/j.imbio.2018.07.004>
- Bebarova, L., Skalický, P., Srovnal, J., Prokopová, A., Zapletalová, J., Hajdúch, M. and Loveček, M., 2018. The effect of circulating tumor cells on the survival of patients with pancreatic cancer 5-year results. *Rozhledy Chirurgii: Mesicnik Ceskoslovenske Chirurgicke Spolecnosti*, **97**: 94-98.
- Cheng, H. and Liu, Y., 2020. An improved RSU-based authentication scheme for VANET. *J. Internet Technol.*, **21**: 1137-1150.
- Cho, Y.K., Shin, E.Y., Uehara, H. and Ambati, B., 2018. The effect of 0.5% timolol maleate on corneal (lymph) angiogenesis in a murine suture model. *J. Ocular Pharmacol. Therap.*, **34**: 403-409. <https://doi.org/10.1089/jop.2017.0119>
- Desrosiers, A.S., Ibrahim, J.M. and Jacks, S.K., 2019. A barrier to care: Distance traveled affects adherence to treatment and follow-up plans for patients with infantile hemangioma. *Pediat. Dermatol.*, **36**: 402-403. <https://doi.org/10.1111/pde.13788>
- Dierkes, J., Seifert, R., Gregory, J.F. and Nygård, O., 2018. Long-term supplementation with folic acid and vitamin B-12 has no effect on circulating uric acid concentrations in Norwegian patients with coronary artery disease. *Am. J. clin. Nutr.*, **107**: 130-132. <https://doi.org/10.1093/ajcn/nqx017>
- D'Haens, G., Vermeire, S., Vogelsang, H., Allez, M., Desreumaux, P., Van Gossom, A., Sandborn, W.J., Baumgart, D.C., Ransohoff, R.M., Comer, G.M. and Ahmad, A., 2018. Effect of PF-00547659 on central nervous system immune surveillance and circulating  $\beta$ 7+T cells in Crohn's disease: report of the TOSCA study. *J. Crohn's Colitis*, **12**: 188-196. <https://doi.org/10.1093/ecco-jcc/jjx128>
- Farimani, A.R., Hariri, M., Azimi-Nezhad, M., Borji, A., Zarei, S. and Hooshmand, E., 2018. The effect of n-3 PUFAs on circulating adiponectin and leptin in patients with type 2 diabetes mellitus: A systematic review and meta-analysis of randomized controlled trials. *Acta Diabetol.*, **55**: 641-652. <https://doi.org/10.1007/s00592-018-1110-6>
- Gao, N., Cheng, B., Hou, H. and Zhang, R., 2018. Mesophase pitch based carbon foams as sound absorbers. *Mat. Lett.*, **212**: 243-246. <https://doi.org/10.1016/j.matlet.2017.10.074>
- Gao, N.S., Guo, X.Y., Cheng, B.Z., Zhang, Y.N., Wei, Z.Y. and Hou, H., 2019. Elastic wave modulation in hollow metamaterial beam with acoustic black hole. *IEEE Access*, **7**: 124141-124146. <https://doi.org/10.1109/ACCESS.2019.2938250>
- Gossiel, F., Scott, J.R., Paggiosi, M.A., Naylor, K.E., McCloskey, E.V., Peel, N.F., Walsh, J.S. and Eastell, R., 2018. Effect of teriparatide treatment on circulating periostin and its relationship to regulators of bone formation and BMD in postmenopausal women with osteoporosis. *J. clin. Endocrinol. Metab.*, **103**: 1302-1309. <https://doi.org/10.1210/jc.2017-00283>
- Gumina, M.E. and Yan, A.C., 2019. Atenolol as an alternative to propranolol for the management of sleep disturbances in the treatment of infantile hemangiomas. *Pediat. Dermatol.*, **36**: 556-557. <https://doi.org/10.1111/pde.13839>
- Kawaguchi, A., Kunimoto, K., Inaba, Y., Mikita, N., Kaminaka, C., Kanazawa, N., Yamamoto, Y., Kakimoto, N., Suenaga, T., Takeuchi, T. and Suzuki, H., 2019. Distribution analysis of infantile hemangioma or capillary malformation on the head and face in Japanese patients. *J. Dermatol.*, **46**: 849-852. <https://doi.org/10.1111/1346-8138.15051>
- Kazemi-Lomedasht, F., Muiyldermans, S., Habibi-Anbouhi, M. and Behdani, M., 2018. Design of a humanized anti vascular endothelial growth factor nanobody and evaluation of its in vitro function.

- Iranian J. Basic med. Sci.*, **21**: 260.
- Martin, B.C., Friedmann, D.P. and Mishra, V., 2019. Commentary on combination of sclerotherapy and dual-wavelength laser in the management of infantile hemangiomas in Chinese patients. *Dermatol. Surg.*, **45**: 1260-1261. <https://doi.org/10.1097/DSS.0000000000001861>
- Rodríguez-Lee, M., Kolatkar, A., McCormick, M., Dago, A.D., Kendall, J., Carlsson, N.A., Bethel, K., Greenspan, E.J., Hwang, S.E., Waitman, K.R. and Nieva, J.J., 2018. Effect of blood collection tube type and time to processing on the enumeration and high-content characterization of circulating tumor cells using the high-definition single-cell assay. *Arch. Pathol. Lab. Med.*, **142**: 198-207. <https://doi.org/10.5858/arpa.2016-0483-OA>
- Schaalan, M.F., Ramadan, B.K. and Abd Elwahab, A.H., 2018. Synergistic effect of carnosine on browning of adipose tissue in exercised obese rats; a focus on circulating irisin levels. *J. cell. Physiol.*, **233**: 5044-5057. <https://doi.org/10.1002/jcp.26370>
- Shill, D.D., Lansford, K.A., Hempel, H.K., Call, J.A., Murrow, J.R. and Jenkins, N.T., 2018. Effect of exercise intensity on circulating microparticles in men and women. *Exp. Physiol.*, **103**: 693-700. <https://doi.org/10.1113/EP086644>
- Sultan, S., Alzahrani, N. and Al-Sakkaf, K., 2018. The postpartum effect of maternal diabetes on the circulating levels of sirtuins and superoxide dismutase. *FEBS Open Bio*, **8**: 256-263. <https://doi.org/10.1002/2211-5463.12370>
- Van Schyndel, S.J., Carrier, J., Bogado Pascottini, O. and LeBlanc, S.J., 2018. The effect of pegbovigrastim on circulating neutrophil count in dairy cattle: A randomized controlled trial. *PLoS One*, **13**: e0198701. <https://doi.org/10.1371/journal.pone.0198701>
- Willis, S.A., Sargeant, J.A., Thackray, A.E., Yates, T., Stensel, D.J., Aithal, G.P. and King, J.A., 2019. Effect of exercise intensity on circulating hepatokine concentrations in healthy men. *Appl. Physiol. Nutr. Metab.*, **44**: 1065-1072. <https://doi.org/10.1139/apnm-2018-0818>
- Wu, Z., Liu, Y. and Jia, X., 2020. A novel hierarchical secret image sharing scheme with multi-group joint management. *Mathematics*, **8**: 448. <https://doi.org/10.3390/math8030448>
- Yang, F., Yang, F., Wang, G., Kong, T., Wang, H. and Zhang, C., 2020. Effects of water temperature on tissue depletion of florfenicol and its metabolite florfenicol amine in crucian carp (*Carassius auratus gibelio*) following multiple oral doses. *Aquaculture*, **515**: 734542. <https://doi.org/10.1016/j.aquaculture.2019.734542>
- Zutt, M., 2019. Laser treatment of vascular dermatological diseases using a pulsed dye laser (595 nm) in combination with a Neodym: YAG-laser (1064 nm). *Photochem. Photobiol. Sci.*, **18**: 1660-1668. <https://doi.org/10.1039/C9PP00079H>