

Pathology of induced Velogenic Viscerotropic Newcastle Disease (VVND) in Japanese Quail and Myna

Muhammad Faisal Ayoob^{1,2}, Zaheer Ahmed Nizamani¹, Asghar Ali Kamboh³, Mansoor Ayoob⁴, Waseem Ali Vistro³ and Abdul Sattar Baloch^{3*}

¹Department of Veterinary Pathology, Sindh Agriculture University, Tandojam.

²National Veterinary Laboratories, Ministry of National Food Security and Research, Islamabad

³Department of Veterinary Microbiology, Sindh Agriculture University, Tandojam

⁴Department of Animal Products Technology, Sindh Agriculture University, Tandojam

ABSTRACT

The present study was designed to investigate the pathology and transmission of experimental velogenic viscerotropic newcastle disease (VVND) in Japanese quails and mynas. Both birds were divided into Q1, Q2, Q3, M1, M2 and M3 group each of four bird. The birds of group Q1, M1 and Q2, M2 were administered with 0.3ml of VVND virus (1.8×10^9 EID₅₀) via intramuscular and oral routes, respectively, whereas, birds of group Q3 and M3 were kept in contact exposure with VVND virus infected chickens. Clinical signs were observed in Japanese quails and mynas on 4th day post-inoculation. The major clinical signs were green yellowish diarrhea, ruffled feathers, anorexia and torticollis in all groups except Q3. The mean clinical scores and mean death time (days) were statistically non-significant ($P > 0.05$) among all the groups. Higher mortality rate (75%) was recorded in mynas as compared to Japanese quails (50%). Major necropsy lesions observed were pin point hemorrhages in proventriculus, demarcated button-like ulcers of intestinal mucosa, hemorrhages in trachea and spleen. Histopathological lesions observed in proventriculus were erosions in epithelium, localized hemorrhages and congestion in the glandular region. In small intestine of affected birds, villi appeared hyperemic and ulcerated. Tracheal surface epithelium often showed discontinuation, the loss of cilia of the lining epithelium and disturbance of the coherence among various histological layers. In spleen, there was enormous infiltration with mononuclear lymphocytes, especially in the area of red pulp. Haemagglutination inhibition titer of all experimental groups was found higher on day 21 as compared to day 0 and 7. Taken together, experimental data showed the susceptibility of Japanese quails and mynas to experimental intramuscular and oral inoculation with VVND virus. Moreover, clinical VVND does not occur in Japanese quails upon contact exposure to VVND virus infected chickens although there is sero-conversion.

Article Information

Received 25 September 2019

Revised 21 October 2019

Accepted 30 October 2019

Available online 12 February 2021

Authors' Contribution

ZAN and AAK designed the study. MFA and MA executed the experimental work. MFA, ASB and WAV wrote the article.

Key words

Japanese quail, Myna, VVND (Velogenic Viscerotropic Newcastle Disease), Histopathology, Haemagglutination, Necropsy

INTRODUCTION

Newcastle disease (ND) is an exceptionally contagious viral disease of domestic poultry, cage and wild birds of all age groups (Alexander, 1997) characterized by respiratory, digestive and nervous signs (Mishra *et al.*, 2000). ND is a major problem for the poultry industry worldwide (Maw *et al.*, 2003; Oladele *et al.*, 2005) and is included in list A contagious diseases of poultry by the world organization of animal health (OIE) on the basis of its economic and veterinary importance (Alexander, 2000). ND causes significant economic losses to the poultry industry due to high mortality, morbidity, stress, reduced egg production and hatchability all over the world

(Sonaiya and Swan, 2005; Lueck *et al.*, 2004). The virulence of ND strains differs significantly with the host, however breed does not seem to have a major affection on the vulnerability of chickens to the disease (Cole and Hutt's, 1961; Higgins, 1971). In other avian species, the disease produced by virulent ND viruses ranges clinically from in apparent to a rapidly fatal condition.

In addition to variation in severity of disease with virus strain, the species of bird, the immunity, age and rearing conditions may also greatly affect the disease signs seen, while the presence of other organisms may greatly exacerbate even the mildest forms of disease. As a consequence, no disease signs may be regarded as pathognomonic (McFerran and McCracken, 1988). Of the five pathotypes of NDV, the velogenic viscerotropic Newcastle disease virus (VVNDV) has been considered to possess the greatest virulence (Utterback and Schwartz, 1973). This pathotype is commonly found in South Asia and South East Asia.

* Corresponding author: balochsattar@gmail.com
0030-9923/2021/0002-0521 \$ 9.00/0
Copyright 2021 Zoological Society of Pakistan

ND is caused by a negative sense, single stranded RNA virus having envelop belongs to the family Paramyxoviridae, sub-family Paramyxovirinae and genus Avulavirus (Lamb *et al.*, 2005). Eleven serotypes of avian paramyxoviruses (APMV) are present currently which are designated as APMV-1 to APMV-11 (Tiana *et al.*, 2012). The ND virus belonging to avian paramyxovirus type-1 serotype (APMV-1) infects different hosts including broilers, hens, rock pigeons, turkeys and quails. The transmission of NDV occurs through freshly introduced birds, marketing of sick birds, contact with contaminated feed, water, utensils, faecal material and extra excretions from diseased birds (Tu *et al.*, 1998).

VVND has been reported in Brazil in ducks, pigeons, quails, turkeys, teal and guan (Cubas, 1993). However, Japanese quails are more resistant to Newcastle disease virus than chickens; the severity of the disease may increase under stress conditions. For appropriate developing of quail industry it is necessary to consider prevention of ND in this bird (Abshar *et al.*, 2000). Japanese quails remain healthy and act as a carrier all the way through their life (Lima *et al.*, 2004). Some other wild birds like waterfowl, geese and teals also maintain Newcastle disease virus strains. The virulent strain circulating in wild environment can be transmitted to commercial poultry flocks (Hlinak *et al.*, 2006). It shows that other avian species which are carriers and shedders of ND virus are potential source of infection to chickens (Chukwudi *et al.*, 2012).

In the recent years, quail and pet birds production has been successfully done on a large commercial scale. Therefore, it is necessary to study the epidemiology and pathology of VVND virus in bird species that are frequently found in the surroundings of housed chickens as these birds may potentially transmit VVND virus to the chickens and vice versa. Therefore, this research work was planned to study the susceptibility of Japanese quails and myna to VVNDV and also their possible role in disease transmission from infected chickens housed along with them.

MATERIALS AND METHODS

VVND virus culture

The VVND virus isolate available at the Sindh poultry vaccine center (SPVC) Karachi was used. The virus (0.1 ml) was inoculated in the allantoic cavity of 9 days old embryonated chicken eggs. After 72 h post-inoculation, embryonated eggs were chilled (4°C) and opened to harvest amnio-allantoic fluid (AAF). Presence of viral antigen was confirmed by haemagglutination (HA) test (OIE, 2012), prepared aliquot, stored at -40 °C and used for whole research work.

Embryo infectious dose₅₀ (EID₅₀)

EID₅₀ of harvested VVND virus titer of stock solution was determined by culturing in 9 days old embryonated chicken eggs using standard method as described in World Organization for Animal Health manual (OIE, 2012). Finally, EID₅₀ was calculated using the Reed and Muench (1938) formula.

Experimental birds

A total of 12 birds of each species (Japanese quail and myna) were purchased from local bird market and were kept separately under hygienic, properly disinfected and well ventilated condition in experimental rooms where feed and water was provided *ad-libitum*.

Blood collection and antibodies titration by haemagglutination inhibition (HI) test

1 ml blood sample was collected on day 0, 7 and 21 of experiment from the wing vein and jugular vein of Japanese quails and mynas with sterile 1 ml syringe and needle without anticoagulant into 1.5 ml of Eppendorf tubes and allowed to clot at room temperature. After clotting of blood Eppendorf tubes were centrifuged at 3000 rpm for 5 min to have a clear serum (supernatant) from the blood. Sera were poured into new labelled Eppendorf tubes and stored at -40 °C until tested. All the sera were tested for antibodies titers against VVND virus by using standard haemagglutination inhibition (HI) method (Allan and Gough, 1974).

Experimental design and infection

Japanese quails and mynas were divided into 3 treatment groups, namely Q1 (n=4), M1 (n=4), Q2 (n=4), M2 (n=4) and Q3 (n=4), M3 (n=4). Each bird of Q1, M1 and Q2, M2 groups were injected with 0.3 ml (1.8×10^9 embryo infectious dose₅₀) of VVND virus intramuscular and oral route, respectively. Birds of group Q3 and M3 were uninfected and exposed contact with VVND infected chicken birds. The infected birds were monitored daily for the development of clinical signs, morbidity and mortality.

Necropsy findings

Postmortem examination was performed on the birds dying during the course of disease for studying various lesions on visceral organs which were found affected during necropsy of experimental birds of each specie. On day 30 post-infection all the surviving birds were euthanized and dissected for observation of lesions. Organs showing lesions were scored as normal 0, light 1, moderate 2 and severely 3 affected according to intensity and morphological changes.

Histopathological examination

Tissue samples (06mm³) of affected organs (trachea,

proventriculus, intestine and spleen) were collected and preserved in 10% neutral buffered formalin dehydrated in series of ascending concentrations of ethanol followed by clearing in two changes of pure xylene and the tissues then were infiltrated in two changes of melted histological paraffin wax (Merck) at 65 °C. Embedding was done on embedding center (HT Company, UK) with melted paraffin wax and finally 6 µm thickness sections were cut by using rotary microtome. The histopathological slides were stained with hematoxylin and eosin (H and E) in automatic tissue stainer (HT Company). Histopathological changes were observed with the help of light microscope at 10X and 40X magnifications.

Histopathological lesion scoring

Histopathological lesion scoring was done according to the intensity of cellular changes by observing the tissue slides under microscope. 0 for normal histological architecture without pathogenic lesions, 1 for few scattered degeneration, leucocyte infiltration and necrosis, 2 for moderate necrosis, leucocyte infiltration and hemorrhagic areas, and 3 for severe necrosis, leucocyte infiltration and hemorrhagic areas.

Statistical Analysis

The data obtained were tabulated and statistically analyzed using computer software named Student Edition of Statistics (SXW), Version. 8.1 (Copyright 2005, Analytical Software, USA).

RESULTS AND DISCUSSION

Anti-VVNDV antibody titers in surviving Japanese quails and mynas determined by HI test

HI test was performed on the sera obtained from Japanese quails and mynas before start of experiment and were found sero-negative with antibodies titer mean values of 1.3, 0.8, 1, 0.8, 1 and 0.8 in Q1, Q2, Q3, M1, M2 and M3, respectively (Fig. 1A). After inoculation of VVND virus to the different groups of Japanese quails and mynas by different routes (viz. intramuscular, oral, contact exposed) sera were collected on day 7 and 21 post infection. Among the groups highest mean HI titer 11 was recorded in M1 on day 21 and lowest 0.8 in Q2, M1 and M3 on day 0. It was also noted that in all the groups HI titer increased by the passage of the time and highest mean HI titer was recorded on day 21 among all the groups and showed statistically significant variation from day 7 and day 0 among all the groups. Presence of antibodies titers in the sera of Japanese quails and mynas indicates that

these birds has been exposed to VVND virus by any route viz. inhalation, intramuscular and oral inoculation. These results provide evidence that Japanese quails and mynas can carry VVND virus for at least 3 weeks and studies of Lima *et al.* (2004) also in agreement with this. Czirjak *et al.* (2007) also confirmed presence of anti-NDV antibodies from Japanese quails flock by haemagglutination inhibition test. Similar type of results obtained by Salihu *et al.* (2012), investigated the sero-prevalence of Newcastle disease in adult household scavenging birds raised under the traditional management system in Nigeria through antibody detection using haemagglutination inhibition test. The results of Abdulla *et al.* (2014) also in agreement with present study results in which they isolated six Newcastle disease virus field strains from samples collected from wild birds including quails and pigeons in Qatar through antibody detection by haemagglutination inhibition test. HI test is most widely used serological test for measuring NDV antibodies in birds and considered the gold standard test for this disease (OIE, 2012).

Clinical findings

Different clinical signs were observed in various groups of birds on different days post-inoculation. First clinical signs in Japanese quails and mynas were observed on 4th day post-inoculation. During the course of experiment till completion the most common clinical findings detected were ruffled feathers, anorexia, diarrhea, torticollis and ataxia in Japanese quails and mynas after inoculation of VVND virus. Czirjak *et al.* (2007) reported similar clinical signs in Japanese quails in natural outbreak of Newcastle disease most commonly manifested clinically by central nervous system dysfunction. Saif *et al.* (2005) also recorded clinical signs in birds infected with VVND virus were mainly diarrhea and visceral organs hemorrhages. During experimental infection of Newcastle disease virus to Japanese quails by Nguyen *et al.* (2000), they found clinical signs like ruffled feathers, anorexia and diarrhea which are same with the findings of present study. Another study conducted by Cynthia *et al.* (2005) reported that VVND clinical signs often begins with anorexia, listlessness, weakness, greenish diarrhea, torticollis and paralysis of legs and wings in fully susceptible species (flock). There is no such information available regarding clinical signs of VVND in mynas in natural and experimental infection.

Mortality rate

Mortality rate was recorded in the experimental birds inoculated with VVND virus. Mortality in Japanese quails started on day 5 and in mynas on day 8 post-inoculation (Fig. 1B). Highest mortality rate was recorded

75% in myna which were administered with VVND virus intramuscularly as compared to other experimental groups of Japanese quails and mynas. A Mortality rate of 50% were recorded in the groups administered VVND virus orally in both experimental species (Japanese quails and mynas). Whereas no mortality was seen in contact exposed group of Japanese quails (Fig. 1C). The result of present study is come to an understanding with Erickson *et al.* (1978) who examined 6 pet species including lesser hill Mynah for epizootiological aspect of VVND and carried out experimental infection and found a mortality of 22% in 5 pet species including Myna. Nguyen *et al.* (2000) reported 60%, 50% and 20% mortality in Japanese quails experimentally infected with Newcastle disease virus intramuscularly, orally and contact-exposed respectively. Their findings are in agreement with present study findings. As highest mortality rate were seen in myna than Japanese quails also mortality recorded in contact-exposed group of myna is showing greater susceptibility of myna to VVND virus infection. In present study, no mortality was recorded in contact-exposed groups of Japanese quails it suggests that VVND virus does not cause clinical infection in natural exposure of Japanese quails but act as a carrier, shed virus and can transmit infection to other species when came in contact. Lima *et al.* (2004) reported Japanese quail as an important carrier for the Newcastle disease virus that is promising with present study findings.

Postmortem findings of the dead birds

Dead birds were examined for postmortem findings and lesions on major infected organs and were scored. The average lesions score of oral groups were higher than intramuscular and contact-exposed groups (Fig. 1D). The most common necropsy findings were seen pin point hemorrhages in proventriculus, hemorrhagic ulcers in intestinal mucosa and hemorrhages in trachea and spleen in both Japanese quails and mynas. Moreover, in proventriculus reddened pin point hemorrhages present at the tip of proventricular glands. On small intestine button-like ulcers of the intestinal mucosa, marked from the serosa and mucosal surfaces. In trachea, mucosal surface was hemorrhagic with numerous red streaks showing congestion. On spleen, petechial hemorrhages and pale focal necrotic lesions were present. Spleen was congested, swollen and enlarged. These findings agreed with McFerran and McCracken (1988) who recorded respiratory tract mucosal hemorrhages and marked congestion of trachea in birds affected with VVND virus. Moreover, identical postmortem lesions were recorded by Alexander (2003) in birds infected with VVND virus. Czirjak *et al.* (2007) recorded similar necropsy findings in experimentally infected Japanese quails.

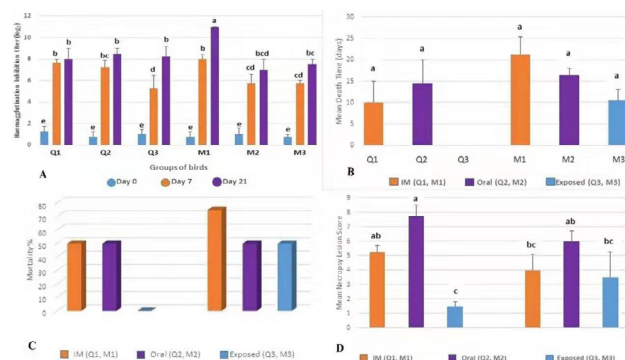


Fig. 1. A, Haemagglutination inhibition titer mean values of serum sample(s) taken from experimental bird species (Japanese quail and myna) on Day 0, 7 and 21 of the experiment showing higher HI titers on day 21 as compared to day 0 and 7.

B, Mean death time (days) was recorded in experimental bird species (Japanese quail and myna) and early mortality was seen in Japanese quails as compared to mynas post-inoculation of VVND virus.

C, Mortality percentage was calculated in experimental bird species (Japanese quail and myna) and higher mortality rate was recorded in myna (75% intramuscular group) as compared to Japanese quail. Different groups of myna showed susceptibility to VVND whereas no mortality was recorded in Japanese quail (contact exposed group).

D, Dead birds were examined for postmortem findings and lesions on major infected organs and were scored according to severity of lesions. The average lesions score of oral groups of both experimental bird species (Japanese quail and myna) were higher than intramuscular and contact-exposed groups.

Histopathology

In present study histopathological lesions observed in various organs of Japanese quails and mynas were as under. In proventriculus histopathological lesions were mainly observed in the mucous membrane of the proventriculus. Extensive erosions in the epithelium, localized hemorrhages and congestion in the glandular region were observed. Glandular openings (villi) were swollen and had various degree of sloughed off mucosae, and irregular outline (Fig. 2A and B). Microscopically small intestine of affected birds showed hyperemic and ulcerated microvilli. Surface desquamation was also prominent (Fig. 2C and D). Histopathological findings in trachea were discontinuation of surface epithelium. Loss of cilia of the lining epithelium and disturbance of coherence among various histologic layers were also noticeable (Fig. 3A and B). In spleen, there was enormous infiltration with mononuclear lymphocytes, especially in the area of red pulp. This region also showed hyperemic changes, petechial hemorrhages were also observed (Fig. 3C and D).

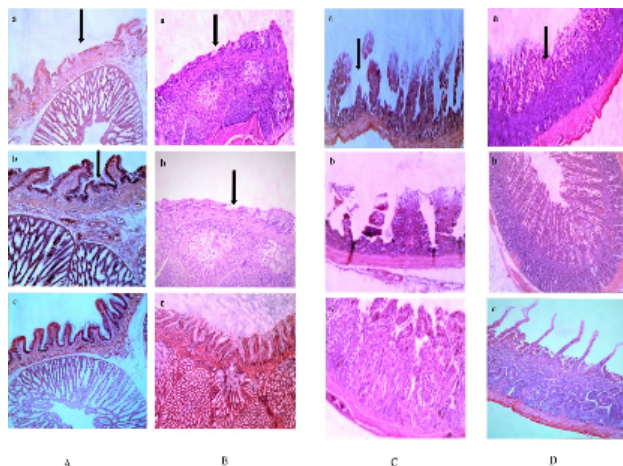


Fig. 2. Histopathological lesions observed in proventriculus of Japanese quail (A) and myna (B) were mainly observed in the mucous membrane of the proventriculus. Extensive erosions in the epithelium, localized hemorrhages and congestion in the glandular region were observed. Glandular openings (villi) were swollen and had various degree of sloughed off mucosae, and irregular outline. Histopathological lesions observed in small intestine of Japanese quail (C) and myna (D) were mainly showed hyperemic and ulcerated microvilli. Surface desquamation was prominent and sloughing off the microvilli was also present.

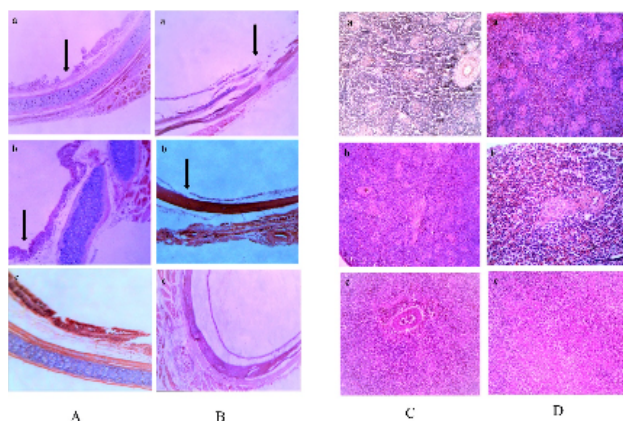


Fig. 3. (A and B) Histopathological lesions observed in trachea of Japanese quail (A) and myna (B) were mainly discontinuation of surface epithelium. Loss of cilia of the lining epithelium and disturbance of coherence among various histologic layers were also noticeable. (C and D) Histopathological lesions observed in spleen of Japanese quail (C) and myna (D) were mainly enormous infiltration with mononuclear lymphocytes, especially in the area of red pulp. This region also showed hyperemic changes, petechial hemorrhages were also observed.

The histopathological lesions observed in various organs of infected Japanese quails and mynas were similar with those reported by several researchers in chickens. Saif *et al.* (2005) and Nisa *et al.* (2019) recorded respiratory tract lesions including loss of cilia of the epithelia, congestion and edema of the mucosa with dense mononuclear cells infiltration. Saidu *et al.* (2006) observed sub-mucosal edema, hemorrhages, congestion and ulceration of the mucosa and villi of the intestine. This study also in agreement with the study of Kianizadeh *et al.* (2002) who mention microscopic changes in spleen especially in lymphoid tissues, lymphoid follicles of the spleen were necrotic and most of the lymphocytes in the medulla were undergoing degeneration and various nuclear changes that occur in the stages of necrosis. Mohammad and Qubih (2011) recorded changes in proventriculus of chicken after Newcastle disease virus infection histological findings were necrotic and hemorrhagic lesion, lymphocytic infiltration in lymphoid follicles and shortening of proventricular papillae.

CONCLUSIONS

Japanese quails and mynas are susceptible to experimental intra-muscular and oral inoculation with VVNDV however mynas are more susceptible. Clinical VVND does occur in mynas upon contact exposure to VVNDV infected chicken. Clinical VVND does not occur in Japanese quails upon contact exposure to VVNDV infected chicken although there is sero-conversion. VVNDV produces similar gross and histopathological lesions in Japanese quails and mynas but with different incubation periods.

ACKNOWLEDGEMENT

We want to acknowledge “Sindh Institute of Animal Health” formerly known as “Sindh Poultry Vaccine Center (SPVC)” for providing the Newcastle Disease (VVND) virus to execute this research work.

Statement of conflict of interest

The authors declare there is no conflict of interest.

REFERENCES

- Abdulla, N.M., Haroun, M., Shalaby, M.A. and Elsanousi, A.A., 2014. Comparative study on some characteristics of Newcastle disease virus field strains isolated from captivated avian species in Qatar. *J. Hum. Virol. Retrovirol.*, **1**: 00014. <https://doi.org/10.15406/jhvr.2014.01.00014>

- Abshar, N., Ahgakhani, S.N., Marounesi, C.H., Sami, Z., Rasoul, S.N.F., Khodashenas, M. and Pourbakhsh, S.A., 2000. Study of quail bronchitis virus (serotype 1, avian adenovirus) isolated from quails. *Paj. Sazan.*, **48**: 128-134.
- Alexander, D.J., 1997. Newcastle disease and other paramyxoviridae infections. In: *Disease of poultry* (eds. B.W. Calnek, H.J. Barnes, C.W. Beard, W.M. Reid and H.W. Jorder Jr), Ames, Iowa State University Press. pp. 541-569.
- Alexander, D.J., 2000. Newcastle disease and other avian paramyxoviruses. *Rev. Sci. Tech. Off. Int. Epiz.*, **19**: 443-462. <https://doi.org/10.20506/rst.19.2.1231>
- Alexander, D.J., 2003. Newcastle disease, other avian paramyxoviruses and pneumovirus infections. In: *Diseases of poultry* (eds. H.J. Barnes, A.M. Fadly, J.R. Glisson, L.R. McDougald, D.E. Swayne and Y.M. Saif). Iowa State University press, Ames, Iowa. pp. 63-99.
- Allan, W.H. and Gough, R.E., 1974. A standard haemagglutination inhibition test for Newcastle disease I. A comparison between macro and micro methods. *Vet. Rec.*, **95**: 120 -123. <https://doi.org/10.1136/vr.95.6.120>
- Chukwudi, O.E., Chukwuemeka, E.D. and Mary, U., 2012. Newcastle disease virus shedding among healthy commercial chickens and its epidemiological importance. *Pak. Vet. J.*, **32**: 354-356.
- Cole, R.K. and Hutt's, F.B., 1961. Genetic differences in resistance to Newcastle disease. *Avian Dis.*, **5**: 205-214. <https://doi.org/10.2307/1587625>
- Cubas, Z.S., 1993. Natural diseases of free-ranging birds in South America. In: *Zoo and wild animal medicine, current therapy* (ed. M.E. Fowler). W.B. Saunders Company, USA. pp. 166-172.
- Cynthia, M., Kahn, L. and Scott, L., 2005. *The Merck veterinary manual*. 9th edn. pp. 2255- 2256.
- Czirjak, G.A., Kobolkuti, L.B., Cadar, D., Ungvari, A., Niculae, M. and Bolfa, P., 2007. An outbreak of Newcastle disease in Japanese quail (*Coturnix coturnix japonica*). *Bull. USAMV-CN.*, **64**: 589-589.
- Erickson, G.A., Mare, C.J., Beran, G.W. and Carbrey, E.A., 1978. Epizootologic aspects of viscerotropic velogenic Newcastle disease in six pet bird species. *Am. J. Vet. Res.*, **39**: 105-107.
- Higgins, D.A., 1971. Nine disease outbreaks associated with myxoviruses among ducks in Hong Kong. *Trop. Anim. Hlth. Prod.*, **3**: 232-240. <https://doi.org/10.1007/BF02359585>
- Hlinak, A., Muhle, R.U., Werner, O., Globig, A., Starick, E., Schirrmeyer, H., Hoffmann, B., Engelhardt, A., Hubner, D., Conraths, F.J., Wallischlager, D., Kruckenberg, H. and Muller, T., 2006. A virological survey in migration waders and other waterfowl in one of the most important resting sites of Germany. *J. Vet. Med. B.*, **53**: 105-110. <https://doi.org/10.1111/j.1439-0450.2006.00935.x>
- Kianizadeh, M., Aini, I. and Gholami, G.R., 2002. A comparative study on histopathologic effects of Iranian Newcastle disease virus isolates. *Arch. Razi Ins.*, **54**: 17-29.
- Lamb, R.A., Collins, P.L., Kolakofsky, D., Melero, J.A., Nagai, Y., Oldstone, M.B.A., Pringle, C.R. and Rima, B.K., 2005. Paramyxoviridae. In: *Virus taxonomy* (eds. C.M. Fauquet, M.A. Mayo, J. Maniloff, U. Desselberger and L.A. Ball). Elsevier, Amsterdam. pp. 655-668.
- Leighton, F.A. and Heckert, R.A., 2007. Newcastle disease and related paramyxoviruses. In: *Infectious diseases of wild birds* (eds. N.J. Thomas and C.T. Atkinson). Blackwell publishing.
- Leuck, D., Haley, M. and Harvey, D., 2004. *U.S. 2003 and 2004 livestock and poultry trade influenced by animal disease and trade restrictions*. 1-15. Available at: <https://www.ers.usda.gov/publications/pub-details/?pubid=37372>.
- Lima, F.S., Satin, E., Paulillo, A.C., Doretto, L., Barbosa de Mordes, V.M. and Hurrino, R.P., 2004. Japanese quail (*Coturnix coturnix japonica*) as Newcastle disease virus carrier. *Int. J. Sci.*, **3**: 383-484. <https://doi.org/10.3923/ijps.2004.483.484>
- Maw, Y.L., Hung, J.L. and Guan, M.K., 2003. Genetic and antigenic analysis of Newcastle disease viruses from recent outbreaks in Taiwan. *Avian Pathol.*, **32**: 354-350. <https://doi.org/10.1080/0307945031000121086>
- McFerran, J.B. and McCracken, R.M., 1988. Newcastle disease. In: *Newcastle disease* (ed. D.J. Alexander). Kluwer Academic Publishers, Boston. pp. 161-183. https://doi.org/10.1007/978-1-4613-1759-3_10
- Mishra, S., Kataria, J.M., Verma, K.C. and Shah, R.I., 2000. Response of chickens to infection with Newcastle disease virus isolated from guinea fowl. *Trop. Anim. Hlth. Prod.*, **32**: 277-284. <https://doi.org/10.1023/A:1005260806046>
- Mohammad, A.O.G. and Qubih, T.S., 2011. Histopathology of virulent Newcastle disease virus in immune broiler chickens treated with IBMO. *Iraqi. J. Vet. Sci.*, **25**: 9-13. <https://doi.org/10.33899/ijvs.2011.5695>
- Nguyen, T.H., Nguyen, D.K., Nguyen, T. and Pham,

- T.L., 2000. Newcastle disease virus transmission in quails. *Vet. Sci. Tech.*, **7**: 38-42.
- Nisa, Q., Younus, M., Rehman, M., Maqbool, A. and Umar, S., 2019. Pathological alterations during co-infection of Newcastle disease virus with *Escherichia coli* in broiler chicken. *Pakistan J. Zool.*, **50**: 495-503.
- OIE., 2012. Newcastle disease. In: *Office International Des Epizooties – Manual of standards for diagnostic tests and vaccines*. Chapter 2.3.14 [http://www.oie.int/Newcastle dis.pdf](http://www.oie.int/Newcastle%20dis.pdf). 2012.
- Oladele, S.B., Nok, A.J., Esievo, K.A.N., Abdu, P. and Useh, N.M., 2005. Haemagglutination inhibition antibodies, rectal temperature and total protein of chickens infected with a local Nigerian isolate of VVND virus. *Vet. Res. Com.*, **29**: 171-179. <https://doi.org/10.1023/B:VERC.0000047495.03341.2b>
- Reed, L.J. and Muench, H., 1938. A simple method of estimating fifty percent endpoints. *Am. J. Hyg.*, **27**: 493-497. <https://doi.org/10.1093/oxfordjournals.aje.a118408>
- Saidu, L., Abdu, P.A., Tekdek, L.B., Umoh, J.U., Usman, M. and Oladele, B.S., 2006. Newcastle disease in Nigeria. *Nigerian Vet. J.*, **27**: 23-32. <https://doi.org/10.4314/nvj.v27i2.3512>
- Saif, Y.M., Barnes, H.J., Glisson, J.R., Fadly, A.M., McDougald, L.R. and Swayne, D.E., 2005. *Diseases of poultry*, 11th eds, pp. 66 – 78.
- Salihu, A.E., Chukwuedo, A.A., Echeonwu, G.O.N., Ibu, J.O., Chukwuekezie, J.O., Ndako, J., Junaid, S.A., Onovoh, E.M., Paul-Abu L.G., Ujah, A.E., Dalyop, A.K., Tende, M.D., Shittu, I., Chindo, H.Z. and Umahi, N.F., 2012. Seroprevalence of Newcastle disease virus infection in rural household birds in Lafia, Akwanga and Keffi metropolis, Nasarawa state Nigeria. *Int. J. agric. Sci.*, **2**: 109-112.
- Sonaiya, E.B. and Swan, S.E.J., 2005. *Manual small-scale poultry production technical guide*. Food and Agriculture Organization of the United Nations, Rome, 2004.
- Tiana, Z., Chaia, Z., Lia, F., Suna, J., Chena, G., Hub, X., Huaa, Y. and Xiang, W., 2012. Complete nucleotide sequence of avian paramyxovirus type-6 strain JL isolated from mallard ducks in China. *J. Virol.*, **86**: 13112. <https://doi.org/10.1128/JVI.02317-12>
- Tu, T.D., Phuc, K.V., Dinh, N.T.K., Quoc, D.N. and Spradbrow, P.B., 1998. Vietnamese trials with a thermostable Newcastle disease vaccine (strain I-2) in experimental and village chickens. *Prev. Vet. Med.*, **34**: 205-214. [https://doi.org/10.1016/S0167-5877\(97\)00065-2](https://doi.org/10.1016/S0167-5877(97)00065-2)
- Utterback, W.W. and Schwartz, J.H., 1973. Epizootiology of velogenic viscerotropic Newcastle disease in southern California, 1971-1973. *J. Am. Vet. Med. Assoc.*, **163**: 1080-1088.