



# Hepato-renal Toxicity of Patulin and its Modulation by Ginger (*Zingiber officinale*) in Rats

Kadry A. El-Bakry<sup>1</sup>, Lamiaa E.M. Deef<sup>1\*</sup>, Lotfy Z. Habbak<sup>1</sup> and Samia S. El-Naeli<sup>2</sup>

<sup>1</sup>Department of Zoology, Faculty of Science, Damietta University, New Damietta, Damietta, Egypt.

<sup>2</sup>Department of Zoology, Faculty of Science, Al-Zawia University, Libya

## ABSTRACT

The present study was conducted to investigate the possible protective effect of ginger on patulin (PAT)-induced hepato-renal toxicity in male rats. Rats were intraperitoneally (i.p) injected with PAT in a single dose (3.75mg/kg body weight). Rats were treated with ginger in a dose (100 mg/kg-1 body weight) for 4 weeks and 8 weeks. Blood samples for biochemical analysis and liver tissues were collected and fixed in 10% formalin for histopathological studies. The present study showed that, PAT causes elevated alanine aminotransferase (ALT) and aspartate aminotransferase (AST) activities and significantly increases serum level of malondialdehyde (MDA) but decrease the activity of superoxide dismutase (SOD) enzyme. On the other hand, in patulin injected rats and treated with ginger, the activity of ALT, AST and SOD were improved and level of MDA was decreased significantly. The liver and kidney tissues showed markers of improvement after treatment the patulin rats with ginger. In conclusion, treatment with ginger can protect liver and kidney from the toxicity induced by patulin.

## Article Information

Received 17 May 2019

Revised 14 June 2019

Accepted 20 June 2019

Available online 28 January 2020

## Authors' Contribution

KAE, LEMD and LZH, designed the experiments. LEMD and SSN performed the experiments, KAE, LEMD and LZH analyzed the data and wrote the paper.

## Key words

Hepatotoxicity, Kidney, Antioxidant, SOD enzyme, Histopathology

## INTRODUCTION

Patulin (PAT) is a mycotoxin produced as a secondary metabolite by several fungal species particularly *Aspergillus*, *Byssoschlamys*, and *Penicillium* (Ramalingam *et al.*, 2018). PAT can induce a number of toxic effects in several animal organs including liver, kidney and intestinal tissues, in addition to immune system and brain (Song *et al.*, 2014a; Ramalingam *et al.*, 2018).

Ginger possesses medicinal properties and has been used since ancient times to treat ailments like cold, headaches, nausea, stomach upset, diarrhea, digestive gastrointestinal disturbances, rheumatic complaints, and parasitic infections (Haniadka *et al.*, 2013). Its extract has been reported to possess a variety of biological properties including anticancer, antioxidation, anti inflammation, antiplatelet aggregation and antifungal (Wei *et al.*, 2005). Gingerols are the main components of ginger (Kato *et al.*, 2006), and it has a strong anti-oxidant activity, antitumor, anti-inflammatory properties and prevent generation of free radicals, it is considered as a harmless herbal medicine without side effects (Chun *et al.*, 2002; Shen *et al.*, 2003; Verma *et al.*, 2004; Ali *et al.*, 2008). The present study

was conducted to evaluate the hepato-renal toxicity of PAT and the possible protective effects of ginger against these toxicities.

## MATERIALS AND METHODS

### Experimental animals

Adult male Sprague Dawley rats, weighing about 100 g were obtained from Zagazig University, Faculty of Veterinary Medicine, Egypt. They were kept under good conditions of humidity, temperature and photoperiod (12 h light and 12 h dark). They were fed on commercial rodent pellet diet and water was provided ad libitum for 20 days. Nursing and use of the animals were managed under control of the Animal Ethics Committee of Mansoura University, Egypt. After acclimatization, rats were divided randomly into 6 groups each of 5 rats as follows (i) control group rats received no treatment, (ii) PAT group rats were injected i.p with PAT purchased from Sigma, Aldrich, Germany at a single dose of 3.75 mg/kg, (iii) ginger group rats were given diet containing ginger obtained from Hypermarket, New Damietta City, Damietta, Egypt 100 mg/kg for 8 weeks, (iv) PAT and ginger group (4 weeks) rats injected with a single dose of PAT as in group (ii) and given diet containing ginger as in group (iii) for 4 weeks, and (v) PAT and ginger group (8 weeks): rats injected with a single dose of PAT as in group ii and given diet containing ginger

\* Corresponding author: lamiaadeef@du.edu.eg

0030-9923/2020/0002-0679 \$ 9.00/0

Copyright 2020 Zoological Society of Pakistan

as in group iii for 8 weeks.

#### Sample preparation

Rats were sacrificed under anesthesia 24 h after injection of PAT. Blood was drawn directly from the heart by a needle and collected in the presence of ethylenediaminetetraacetic acid (EDTA) for hematological study. A part of blood sample was added in tubes without EDTA. Serum was separated for biochemical analysis. Large lobe of liver of each rat was quickly removed, washed with normal saline and fixed immediately in 10 % formalin for 24 h for histopathological studies.

#### Determination of complete blood picture

Blood picture for each rat was obtained by Sysmex the automatic hematology analyzer SF 3000, Kobe, Japan.

#### Biochemical studies

Blood serum was used for estimation of liver enzymes alanine aminotransferase (ALT) and aspartate aminotransferase (AST) according to [Reitman and Frankel \(1957\)](#). Serum level of malondialdehyde (MDA) and activity of superoxide dismutase (SOD) enzyme were measured by the colorimetric technique according to manufacture's instructions (Bio-diagnostic, Giza, Egypt).

#### Histopathological assessment of liver damage

Fixed specimens were dehydrated with ascending series of ethanol alcohol and embedded in paraffin, sectioned at 5  $\mu$ m and stained with hematoxylin–eosin according to [Drury \*et al.\* \(1967\)](#) and with Masson's Trichrome according to [Masson \(1929\)](#).

#### Statistical analysis

All the grouped data were statistically evaluated with SPSS 22 software. Differences among groups were evaluated by one-way analysis of variance (ANOVA) and paired-samples (t test) taking into consideration the control results as basal values.

## RESULTS

#### Haematological studies

A significant difference in the haemoglobin (Hb) content and platelet count  $\times 10^3$  in PAT group compared with control group ([Table I](#)). On the other hand, a significant difference was observed in the RBCs and WBCs count in ginger group compared with control group ([Table I](#)). In ginger treated group for 4 weeks, there was significant increase in the platelet count compared with control group ( $P=0.03$ ). Otherwise, after treatment with ginger for 8 weeks, a significant difference was observed in the WBCs

and platelet counts compared with control group.

#### Liver function

The activity of AST enzymes was significantly increased in PAT group compared with that of the control group ( $P=0.01$ ). After treatment with ginger for (8weeks), the activities of ALT and AST were significantly increased compared with control group ([Fig. 1](#)). After treatment with ginger for 4weeks, the activity of AST was significantly decrease compared with PAT group ( $P=0.02$ ). Also, the activity of ALT and AST were significantly difference after treatment with ginger for 8weeks compared PAT group ( $P=0.03$ ,  $P=0.01$  respectively). On other hand, the activity of AST was a significant increase in ginger and PAT 8 weeks compared with ginger group ( $P=0.02$ ). Otherwise, the activity of ALT was a significant increase in PAT and ginger 4 weeks group compared with PAT and ginger 8 weeks group ( $P=0.03$ ).

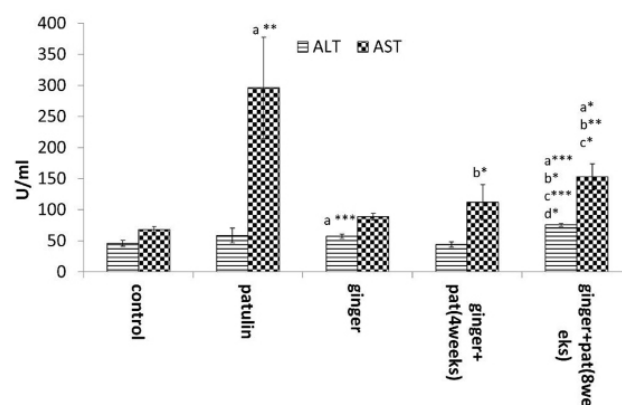


Fig. 1. Serum alanine aminotransferase (ALT) and a separate aminotransferase (AST) activities U/ml in the experimental groups.

#### MDA and SOD activities

The level of MDA was significantly increased in PAT group compared with that of the control group ( $P=0.000$ ). In ginger group, there was a significant increase of MDA level compared with control group ( $P=0.004$ ). After treatment with ginger for 4 weeks, significant increase in MDA while SOD enzyme was decreased compared with that of control group. On other side after treatment with ginger for 8 weeks, significant increase of the level of MDA were found compared with control group ( $P=0.003$ ). After treatment with ginger for 4 weeks, there was a significant decrease in the SOD activity compared with PAT group ( $P=0.03$ ). After treatment with ginger for 8 weeks, there were significant differences on the level of MDA and SOD activity were observed compared with PAT group. On other hand there were significant differences in the level of MDA and SOD activity compared with ginger group ([Fig. 2](#)).

**Table I. Mean count of blood cells and haemoglobin (Hb) content of experimental groups.**

	Control (n=5)	Patulin (n=5)	Ginger (n=5)	Ginger + PAT	
				4 weeks (n=5)	8 weeks (n=5)
Platelet (x 10 <sup>3</sup> )	420.3±182.9	143.4±129.6a*	626.6±136.3	561±233.35a*	669.6±91.92 a*b***
WBCs (x 10 <sup>3</sup> )	20.0±6.35	9.1±2.4	6.1±1.06a**	8.75±2.33	6.4±1.94a**
Hb (g/dl)	13.9±0.85	10.9 ±1.07a**	12.10 ±0.89	15.35±0.21	13.6±0.9b**
RBCs (x 10 <sup>6</sup> )	6.1±1.93	6.2±1.19	7.8±0.65a*	8.95±0.97	7.8 ±0.87b*

Values are expressed as Mean ± SD in each group; \*significant; \*\*highly significant and \*\*\* extremely significant. When compared all groups with control group, a: compared with control group; b: compared with patulin group; c: compared with ginger group; d: compared with patulin and ginger 8weeks group.

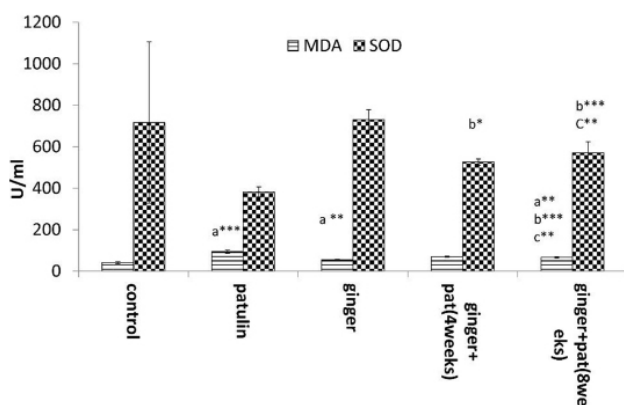


Fig. 2. The hepatic superoxide dismutase (SOD) activity (U/ml) and malondialdehyde (MDA) (nM/ml) content in the experimental groups.

#### Creatinine concentration

A significant difference of serum creatinine concentration was observed between ginger group and ginger and patulin group compared with control group ( $P=0.000$ ,  $P=0.001$ ), respectively. Also, there was a significant difference in serum creatinine concentration between ginger and patulin for 8weeks group compared with patulin group ( $P=0.001$ ). In ginger and patulin 8weeks group, there was significant decrease in serum creatinine concentration compared with ginger group ( $P=0.03$ ) (Fig. 3).

#### Histopathological studies

##### Liver tissue

Liver tissue of patulin injected rats showed periportal hepatic vacuolation with dark pyknotic nuclei and bile duct proliferation (Fig. 4b) and increased the periportal fibrous

connective tissue (Fig. 5b). After treatment with ginger for 4 and 8 weeks, liver tissues showed marked improvement in terms of decreased degree of hyperplasia in liver and thin fibrous layer (Fig. 4c, 4d and Fig. 5c, 5d) compared with liver tissue of the control group.

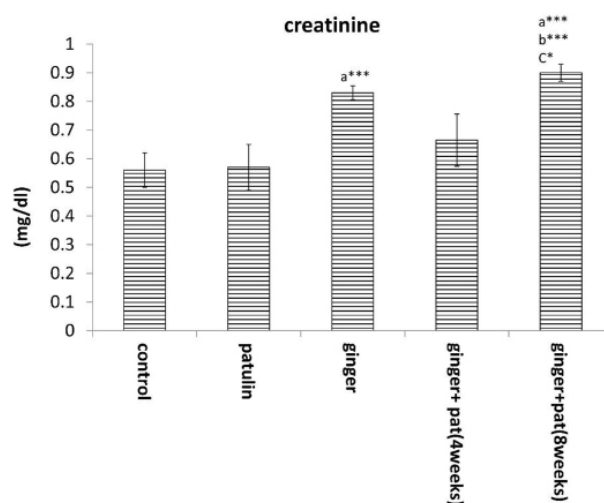


Fig. 3. Mean of serum creatinine concentration (mg/dl) in the experimental groups.

##### Kidney tissue

Figure 6a and Figure 7b showed congestion of the glomerular tufts with oedema of the Bowman's space and degenerative changes within the renal tubular epithelium. There is increased thickness of the periglomerular and peritubular fibrous layer in PAT treated rats. Treatment with ginger for 4 and 8 weeks, showed normal renal glomeruli, normal renal tubules and thin perivascular layer of fibrous tissue (Fig. 6b, 6c and Fig. 7c, 7d) compared with kidney tissue of the control group.



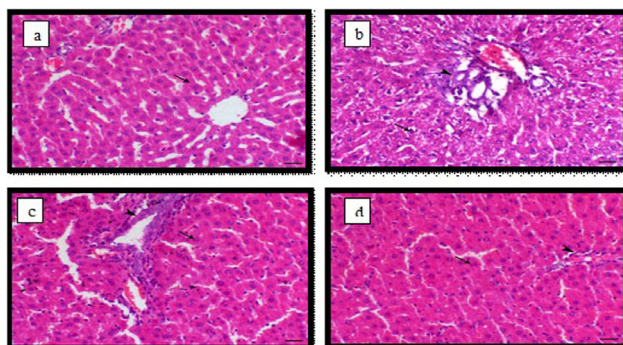


Fig. 4. Light micrograph of liver, (a) control animals showing normal hepatocytes arranged in cords around the central vein (arrow); (b) PAT-treated animals showing periportal hepatic vacuolation with dark pyknotic nuclei (arrow) and bile duct proliferation (arrowhead); (c) PAT and ginger (4 weeks) animal showing normal periportal hepatic cells (arrow) and mild hyperplasia of the lining epithelium of the bile duct (arrowhead) and (d) PAT and ginger animals (8 weeks) showing normal hepatic cells (arrow) and normal portal tissues (arrowhead), Haematoxylin and Eosin stain, bar = 40  $\mu$ m.

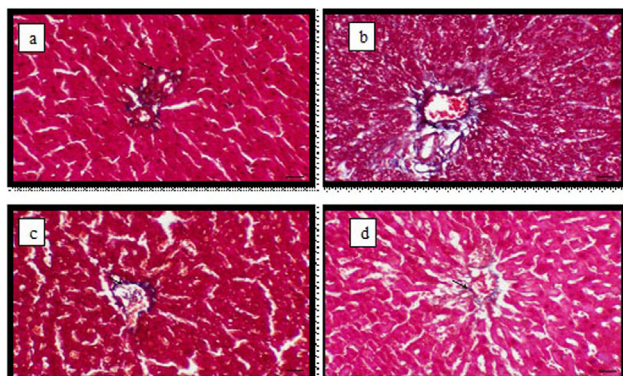


Fig. 5. Light micrograph of liver, (a) control animals showing thin layer of periportal fibrous connective tissue (arrow); (b) PAT-treated animals showing increased the periportal fibrous connective tissue (arrow); (c) PAT and ginger (4 weeks) animals showing thin layer of periportal fibrous connective tissue (arrow) and (d) PAT and ginger (8 weeks) animals showing thin layer of periportal fibrous connective tissue (arrow), Masson's trichrome staining bar = 40  $\mu$ m.

## DISCUSSION

PAT has been reported to decrease glutathione (GSH) level and glutathione-s-transferase (GST) activity and increased DNA damage in mice liver (Pfeiffer *et al.*, 2005). PAT also depresses protein synthesis in hepatoma tissue culture (Arafat and Musa, 1995), and decreases the

viability of hepatic cells (Zhou *et al.*, 2009).

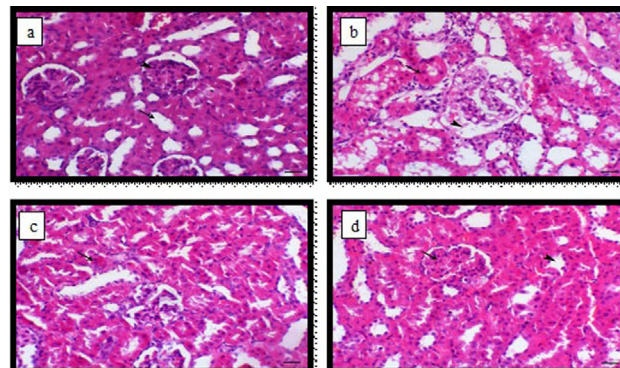


Fig. 6. Light micrograph of kidney, (a) control animal showing normal renal glomeruli and tubules (arrow head and arrow respectively); (b) PAT-treated animal showing congestion of the glomerular tufts with oedema of the Bowman's space (arrowhead) and degenerative changes within the renal tubular epithelium (arrow); (c) PAT and ginger-treated animal for 4 weeks showing mild to moderate degenerative changes within renal tubular epithelium (arrow) and (d) PAT and ginger treated animal for 8 weeks showing normal renal glomeruli and tubules (arrow and arrowhead respectively), Haematoxylin and Eosin stain, bar = 40  $\mu$ m.

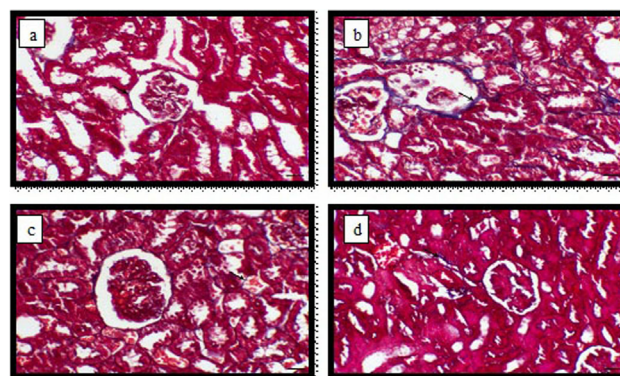


Fig. 7. Light micrograph of kidney, (a) control animals showing thin layer of periglomerular and peritubular fibrous layer (arrow); (b) PAT -treated animals showing increased the thickness of the periglomerular and peritubular fibrous layer (arrow); (c) PAT and ginger -treated animals for 4 weeks showing thin periglomerular and peritubular fibrous layer (arrow) and (d) PAT and ginger -treated animal for 8 weeks showing thin perivascular layer of fibrous connective tissue (arrow), Masson's trichrome stain, bar = 40  $\mu$ m.

The present study showed significant decreases in Hb content in PAT group compared with that of the control

group. Decreased Hb in our study is in accordance with the studies of [Rolinec et al. \(2010\)](#) and [Bačovský \(2013\)](#). [Camguilhem et al. \(1976\)](#) reported that PAT caused anemia in other mammals such as sheep. The results of our study showed significant improvement in blood parameters such as RBCs, Hb, WBCs, PLT, after treatment of PAT group with ginger for 4 or 8 weeks.

The present study showed that injection of PAT in male rats caused a significant elevation in serum level of MDA corresponding to markedly decreased antioxidant parameters including, SOD activity. This finding indicates that PAT caused oxidative injury in liver and kidney of the treated rats. The present findings closely resemble to that obtained by several studies demonstrating the toxic effect of PAT in different organs, including the liver, kidney and brain ([Heussner et al., 2006](#); [Saxena et al., 2011](#); [Song et al., 2014b](#)). In addition, [Liu et al. \(2006\)](#) found that inhibition of both SOD and catalase (CAT) could play a role in PAT-induced oxidative damage in certain types of human cells in vitro. Moreover, studies on dermal toxicity of PAT showed that, in the presence of promoter, PAT in a single topical application (400 mmol) led to tumor formation along with marked rise in lipid peroxidation product and decrease in activity of antioxidant enzymes including CAT, SOD and glutathione reductase (GSH-RD) in treated mice ([Saxena et al., 2011](#)).

In the present study, PAT administration in rats caused elevation in the serum activities of ALT and AST. This result confirmed that PAT is a hepatotoxic mycotoxin and has the ability to produce hepatocyte injury. The mechanism of this liver injury seemed to be due to PAT-increased lipid peroxidation product and reduced both GSH and antioxidant enzymes in the liver of treated mice. Hepatotoxic effect of PAT was further confirmed by obtained finding of lowered serum concentrations of total proteins and albumin, which reflects inhibition of liver synthetic function. Thus, injection of PAT in rats could induce oxidative stress which resulted in hepatic cell injury and dysfunction. Hepatocellular damage of PAT may be time dependent as reported by [El-Sawi et al. \(2018\)](#).

Histopathological results showed that, liver tissue of PAT injected rats show periportal hepatic vacuolation with dark pyknotic nuclei and bile duct proliferation and increased the periportal fibrous connective tissue. In another study, liver tissues of PAT treatment in BALB/c mice undergo necrosis of hepatocytes, infiltration by inflammatory cells, focal hepatocellular vacuolation, and slight hemorrhaging ([Jayashree et al., 2017](#)). After treatment with ginger for 4 and 8 weeks, liver tissues showed marked improvement in which it can be observed that degree of hyperplasia in liver and thin fibrous layer is decreased.

In kidney tissue there are some findings such as congestion of the glomerular tufts with oedema of the Bowman's space and degenerative changes within the renal tubular epithelium and increased the thickness of the periglomerular and peritubular fibrous layer in PAT treated rats. [El-sawi et al. \(2015\)](#) found that PAT injection induces several histopathological changes in the kidney tissue of male albino rats, e.g., shrinkage and hyper cellularity of glomeruli, hyperplasia of the epithelial lining, and wall destruction. Moreover, PAT causes the loss of microvilli (apical), mitochondria, and of the brush border of proximal and distal convoluted tubules as well as infiltration of interstitial inflammatory cells into rat kidney tissue. However, in mouse kidneys there are uncovered degeneration of renal corpuscles, Bowman's capsules, kidney tubules, and glomeruli; hemorrhage and extravasation in tubules of the cortical region; hyper cellularity in glomeruli and medullary tissue; and flaking out of the epithelial cells as reported by [Al-Hazmi \(2014\)](#).

Treatment with ginger for 4 and 8 weeks, showed normal renal glomeruli and renal tubules and thin perivascular layer of fibrous tissue ([Fig. 6b, 6c](#) and [Fig. 7c, 7d](#)) compared with kidney tissue of the control group. Due to the antioxidant activity of ginger the present results showed that treatment with ginger, attenuated the severity of inflammation induced by PAT in liver and kidney which can be observed from the present findings that, normal liver and kidney tissue and a thin layer of collagen fibers was observed after ginger treatment for 4 and 8 weeks.

## CONCLUSION

The present study shows that the ginger protects the liver of rats from PAT-induced injury by suppressing hepatic inflammation and attenuating hepatic oxidative stress. Ginger has the ability to down regulate free radicals, improve liver function and ameliorate hepatic marker enzymes.

### *Ethics approval and consent to participate*

All animal experiments involved in this study were approved by the Laboratory Animal Welfare and Animal Experimental Ethical Committee of IACUC Cairo University. We followed guidelines of the Committee for experimental animals during this study.

### *Statement of conflict of interests*

The authors declare no competing interests exist.

## REFERENCES

Al-Hazmi, M.A., 2014. Patulin in apple juice



- and its risk assessments on albino mice. *Toxicol. Ind. Hlth.*, **30**: 534-545. <https://doi.org/10.1177/0748233712457454>
- Ali, B.H., Blunden, G., Tanira, M.O. and Nemmar, A., 2008. Some phytochemical, pharmacological and toxicological properties of ginger (*Zingiber officinale* Roscoe): a review of recent research. *Fd. Chem. Toxicol.*, **46**: 409-420. <https://doi.org/10.1016/j.fct.2007.09.085>
- Arafat, W. and Musa, M.N., 1995. Patulin-induced inhibition of protein synthesis in hepatoma tissue culture. *Res. Commun. Mol. Pathol. Pharmacol.*, **87**: 177-186.
- Báčovský, J., 2013. *Blood count interpretation*. online: 5 August 2013. [http://public.fnol.cz/www/3ik/vyuka/education\\_english/bacovsky/blood\\_count\\_interpretation\\_1.pdf](http://public.fnol.cz/www/3ik/vyuka/education_english/bacovsky/blood_count_interpretation_1.pdf)
- Camguilhem, R., Escoula, L. and Henry, M., 1976. Toxins of *Bysschochlamys nivea* Westling. I. Preliminary study of toxicity in sheep. *Annls Vet. Res.*, **7**: 177-183.
- Chun, K.S., Park, K.K., Lee, J., Kang, M. and Surh, Y.J., 2002. Inhibition of mouse skin tumor promotion by anti-inflammatory diarylheptanoids derived from *Alpinia oxyphylla* Miquel (Zingiberaceae). *Oncol. Res.*, **13**: 37-45. <https://doi.org/10.3727/096504002108747944>
- Drury, R.A.B., Wallington, E.A. and Cameron, S.R., 1967. *Carleton's histological technique*, London.
- El-Sawi, M.R., Hemieda, F.A., Shabana, S. and Khmalj, R.G., 2018. Role of N-acetyl-L-cysteine in the prevention of hepatotoxicity induced by patulin in male mice. *J. Pharm. Chem. Biol. Sci.*, **6**: 1-10. <https://doi.org/10.5455/egyjebz.20170202100538>
- Elsawi, N.M., El-Sawi, N.M., Al-Seni, M.N., El Haliem, N.G.A., El-Wassimy, M.T., Salah, H. and Abdo, A.S., 2015. Biochemical and histological studies of Goji extract role on patulin mycotoxin on male rat kidney. *Int. J. Fd. Nutr. Sci.*, **2**: 122-128. <https://doi.org/10.15436/2377-0619.15.036>
- Haniadka, R., Saxena, A., Shivashankara, A., Fayad, R., Palatty, P., Nazreth, N., Francis, A., Arora, R. and Baliga, M., 2013. Ginger protects the liver against the toxic effects of xenobiotic compounds: preclinical observations. *J. Nutr. Fd. Sci.*, **3**: 1000226.
- Heussner, A.H., Dietrich, D.R. and O'Brien, E., 2006. In vitro investigation of individual and combined cytotoxic effects of ochratoxin A and other selected mycotoxins on renal cells. *Toxicol. in Vitro*, **20**: 332-341. <https://doi.org/10.1016/j.tiv.2005.08.003>
- Jayashree, G.V., Krupashree, K., Rachitha, P. and Khanum, F., 2017. Patulin induced oxidative stress mediated apoptotic damage in mice, and its modulation by green tea leaves. *J. clin. exp. Hepatol.*, **7**: 127-134. <https://doi.org/10.1016/j.jceh.2017.01.113>
- Kato, A., Higuchi, Y., Goto, H., Kizu, H., Okamoto, T., Asano, N., Hollinshead, J., Nash, R. J. and Adachi, I., 2006. Inhibitory effects of *Zingiber officinale* Roscoe derived components on aldose reductase activity in vitro and in vivo. *J. Agric. Fd. Chem.*, **54**: 6640-6644. <https://doi.org/10.1021/jf061599a>
- Liu, B.H., Wu, T.S., Yu, F.Y. and Su, C.C., 2006. Induction of oxidative stress response by the mycotoxin patulin in mammalian cells. *Toxicol. Sci.*, **95**: 340-347. <https://doi.org/10.1093/toxsci/kfl156>
- Masson, P., 1929. Some histological methods: trichrome staining and their preliminary technique. *J. Technol. Meth.*, **12**: 75-90.
- Pfeiffer, E., Diwald, T.T. and Metzler, M., 2005. Patulin reduces glutathione level and enzyme activities in rat liver slices. *Mol. Nutr. Fd. Res.*, **49**: 329-336. <https://doi.org/10.1002/mnfr.200400089>
- Ramalingam, S., Bahuguna, A. and Kim, M., 2018. The effects of mycotoxin patulin on cells and cellular components. *Trends Fd. Sci. Technol.*, **83**: 99-113. <https://doi.org/10.1016/j.tifs.2018.10.010>
- Reitman, S. and Frankel, S., 1957. A colorimetric method for the determination of serum glutamic oxalacetic and glutamic pyruvic transaminases. *Am. J. clin. Pathol.*, **28**: 56-63. <https://doi.org/10.1093/ajcp/28.1.56>
- Rolinec, M., Bíro, D., Šťastný, P. and Kanka, T., 2010. Zhodnotenie hematologických ukazovateľov prasiat v skorom postnatálnom období-Analysis of haematological profile of piglets in early postnatal period. *Acta Fytotech. Zootech.*, **13**: 40-43.
- Saxena, N., Ansari, K.M., Kumar, R., Chaudhari, B.P., Dwivedi, P.D. and Das, M., 2011. Role of mitogen activated protein kinases in skin tumorigenicity of patulin. *Toxicol. appl. Pharmaol.*, **257**: 264-271. <https://doi.org/10.1016/j.taap.2011.09.012>
- Shen, C.L., Hong, K.J. and Kim, S.W., 2003. Effects of ginger (*Zingiber officinale* Rosc.) on decreasing the production of inflammatory mediators in sow osteoarthrotic cartilage explants. *J. Med. Fd.*, **6**: 323-328. <https://doi.org/10.1089/109662003772519877>
- Song, E., Su, C., Fu, J., Xia, X., Yang, S., Xiao, C., Lu, B., Chen, H., Sun, Z. and Wu, S., 2014a. Selenium supplementation shows protective effects against patulin-induced brain damage in mice via increases in GSH-related enzyme activity and expression.

- Life Sci.*, **109**: 37-43. <https://doi.org/10.1016/j.lfs.2014.05.022>
- Song, E., Xia, X., Su, C., Dong, W., Xian, Y., Wang, W. and Song, Y., 2014b. Hepatotoxicity and genotoxicity of patulin in mice, and its modulation by green tea polyphenols administration. *Fd. Chem. Toxicol.*, **71**: 122-127. <https://doi.org/10.1016/j.fct.2014.06.009>
- Verma, S., Singh, M., Jain, P. and Bordia, A., 2004. Protective effect of ginger, *Zingiber officinale* Rosc on experimental atherosclerosis in rabbits. *Indian J. exp. Biol.*, **42**: 736-738
- Wei, Q.Y., Ma, J.P., Cai, Y.J., Yang, L. and Liu, Z.L., 2005. Cytotoxic and apoptotic activities of diarylheptanoids and gingerol-related compounds from the rhizome of Chinese ginger. *J. Ethnopharmacol.*, **102**: 177-184. <https://doi.org/10.1016/j.jep.2005.05.043>
- Zhou, S.M., Jiang, L.P., Geng, C.Y., Cao, J. and Zhong, L.F., 2009. Patulin-induced genotoxicity and modulation of glutathione in HepG2 cells. *Toxicol.*, **53**: 584-586. <https://doi.org/10.1016/j.toxicol.2009.01.030>