



Supplementary Material

Short Communication: Pathology of Experimentally Induced Hydropericardium Syndrome in Ostrich

Attaur Rahman¹, Sadeeq ur Rahman^{1,*}, Ashfaq Ahmad², Abdul Sajid¹, Muhammad Asif Hussain¹, Mian Muhammad Salman¹, Niamatullah Khan¹, Kamran Khan³, Fazle Rabbani¹, Muhammad Akbar Shahid⁴, Irshad Ahmad⁵ and Shakoor Ahmad⁶

¹College of Veterinary Sciences and Animal Husbandry, Abdul Wali Khan University, Mardan, Pakistan

²Department of Plant Breeding and Genetics, University of Agriculture, Peshawar, Pakistan

³Sindh Poultry Vaccine Centre, Karachi, Pakistan

⁴Bahauddin Zakariya University, Multan, Pakistan

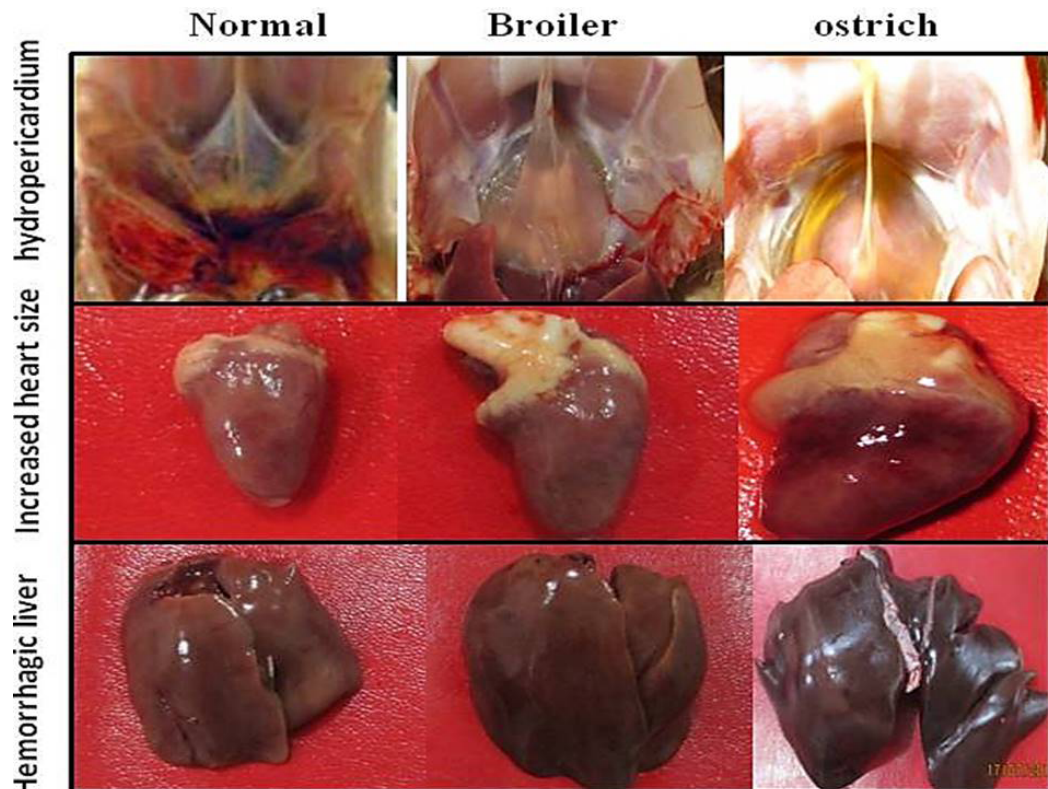
⁵School of Biomedical Sciences, University of Leeds, United Kingdom

⁶Department of Animal Health, The University of Agriculture, Peshawar, Pakistan

* Corresponding author: sadeeq@awkum.edu.pk

0030-9923/2019/0003-1179 \$ 9.00/0

Copyright 2019 Zoological Society of Pakistan



Supplementary Fig. S1. Postmortem lesions of induced HPS in broiler and ostrich. HPS was induced in broiler and ostrich birds and birds were examined for postmortem lesions. Fluid accumulation was observed both in broiler and ostrich. Beside, an obvious increase in the size of hearts, petechial and echymotic hemorrhages on postmortem resected heart and liver were also observed.

Supplementary Table I.- Gross pathological scoring of affected organs of FAdV-4 infected broiler and ostrich.

Organ affected	Mean scores							
	D0	D1	D2	D3	D4	D5	D6	D7
Broiler								
Liver	0	0	1	2	3	3	3	3
Kidney	0	0	2	3	3	3	3	3
Heart	0	0	1	3	3	3	3	3
Spleen	0	0	1	2	3	3	3	3
Ostrich								
Liver	0	0	0	1	2	3	3	3
Kidney	0	0	0	2	3	3	3	3
Heart	0	0	0	2	3	3	3	3
Spleen	0	0	0	0	1	2	3	3

0, no lesions; 1, light; 2, moderate; 3, severe.