



Supplementary Material

Prevalence of *Mycoplasma gallisepticum* in Poultry and Wild Life Birds Suspected of Chronic Respiratory Disease in Northern Pakistan

Nasir Abbas¹, Muhammad Suleman¹, Nazir Ahmad Khan^{2,*}, Ijaz Ali³, Mubashir Rauf^{1,5} and Sadeeq ur Rahman^{4,*}

¹Department of Microbiology, Hazara University, Mansehra 21300, Khyber Pakhtunkhwa

²Department of Animal Nutrition, The University of Agriculture, Peshawar

³Department of Biosciences, Bioscience Block, Chak Shehzad Campus, Park Road, COMSATS Institute of Information Technology, Islamabad

⁴College of Veterinary Sciences and AH, Section Microbiology, Abdul Wali Khan University, Mardan, Khyber Pakhtunkhwa

⁵College of Veterinary Sciences, Bahauddin Zakariya University, Sub Campus Layyah

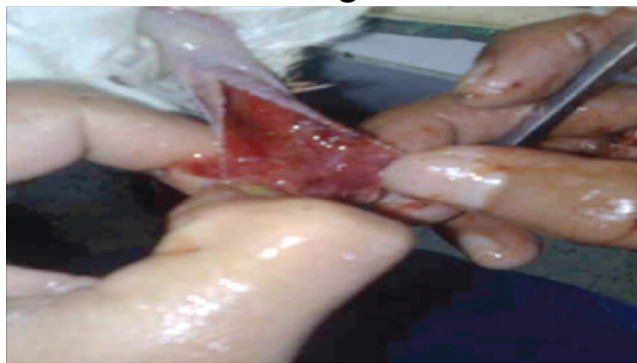* Corresponding authors: sadeeq@awkum.edu.pk;

nak126@gmail.com

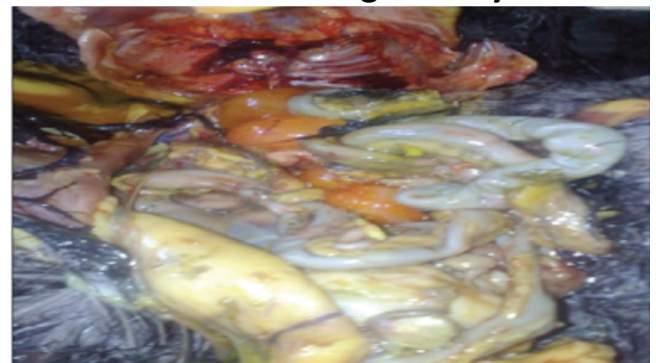0030-9923/2018/0003-1071 \$ 9.00/0

Copyright 2018 Zoological Society of Pakistan

Haemorrhagic trachea



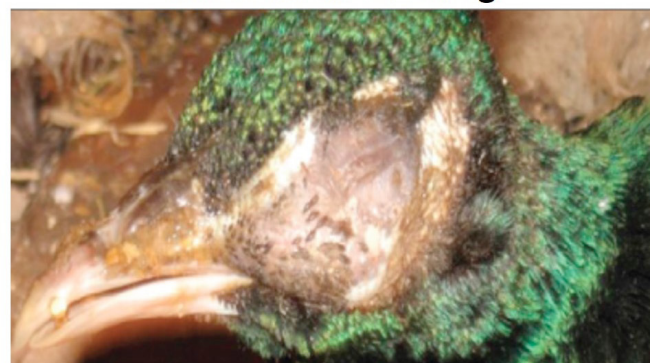
Haemorrhagic ovary

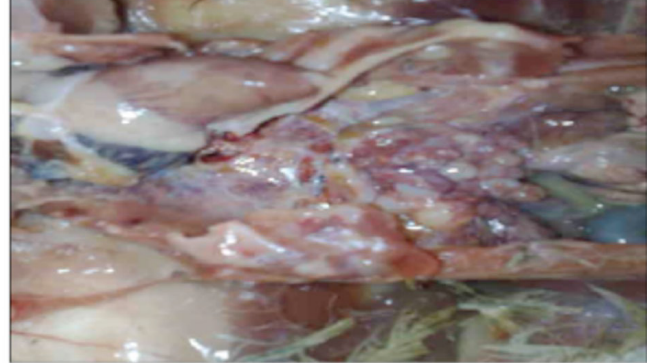

Open mouth respiration



Infraorbital swelling



Infraorbital swelling**Affected ovaries**

Supplementary Fig. S1. Clinical symptoms and postmortem lesions. Poultry and pheasantry birds showing clinical signs or postmortem lesion of the resected organs of CRD suspected birds.